



**PATIENT**

Rudy O'Kelley

**SPECIES**

Canine

**BREED**

Standard Poodle

**SEX**

Neutered Male

**AGE**

8

**WEIGHT**

30 kg

**INTERPRETED BY**

Beth Johnson, DVM  
DACVIM

**IMAGING PERFORMED BY**

Meegan Spatz

**HOSPITAL NAME**

Boren Vet Medical  
Teaching Hospital

**REFERRING VET**

Dr. Leandro Fadel

**INVOICE**

46295

**DATE**

3/30/23

**PRESENTING CLINICAL SIGNS**

Went to rDVM Tuesday for ADR, vomiting and diarrhea. Kept overnight with antibiotics, antiemetic, steroid, and subcutaneous fluids. RDVM performed barium study on Wednesday and started giving IV fluids in addition to the other medications. rDVM suspected abdominal mass and referred to our clinic today. Patient presents today with a mild hyperthermia, weak pulses, muddy MM, and a CRT >3 sec. Ventricular escape beats were noted on ECG and pericardial fluid noted on TFAST. **LEADING DIFFERENTIAL/DIAGNOSIS:** Neoplasia, Metastatic neoplasia, idiopathic pericarditis.

**ULTRASONOGRAPHIC EXAMINATION OF THE ABDOMEN**

**Urinary System**

The urinary bladder is moderately distended with anechoic contents. No masses, inflammatory changes, echogenic sediment or cystoliths are observed. The urinary bladder, trigone and visible pelvic urethra are normal in thickness with a smooth mucosal surface.

The area of the prostate is examined without evident prostatic pathology.

The right kidney is normal in size (7.49 cm), shape and echogenicity. It has smooth peripheral margination. There is a normal 1:3 cortex to medulla ratio with appropriate corticomedullary distinction. There is no evidence of pyelectasia, mineral or infarcts observed.

The left kidney is normal in size (7.0 cm), shape and echogenicity. It has smooth peripheral margination. There is a normal 1:3 cortex to medulla ratio with appropriate corticomedullary distinction. There is no evidence of pyelectasia, mineral or infarcts observed.

**Adrenal Glands**

The adrenal glands are unable to be well visualized in these images.

**Spleen**

The spleen presents multiple heterogeneous cavitated nodules and masses, resulting in a scalloped appearance, the largest of which measures 6.5 cm in diameter.

**Liver**

The liver is subjectively normal in size with normal smooth curvilinear peripheral contour. Parenchyma is appropriately hypoechoic to the spleen in echogenicity and appropriately mildly coarse and homogenous in echotexture. No focal lesions are observed. Visible vasculature and biliary tree appear normal without distension or congestion.

The gallbladder is non-distended in size. The wall is smooth without visible thickening. Luminal contents are primarily anechoic. There is no evidence of cystic or common bile duct dilation.

**Gastrointestinal**

The stomach wall is normal in thickness (canine < 0.5 cm and feline < 0.4 cm) and layering. The lumen of the stomach is empty with no evidence of obstruction, foreign material or infiltrative disease. Pyloric outflow tract appears patent.

The visible small intestines are normal in wall thickness and layering (canine duodenum < 0.5 cm and feline duodenum < 0.4 cm; other < 0.3 cm). Small intestinal motility appears adequate (1-3 contractions per min). The lumen of the small intestine is empty with no evidence of obstruction, foreign material or infiltrative disease.



**PATIENT**

Rudy O'Kelley

The visible colon is normal in wall thickness (< 0.2 cm) and layering. Contents are consistent with normal formed feces and gas.

**SPECIES**

Canine

**Pancreas**

The pancreatic parenchyma is appropriately isoechoic to surrounding tissue. Visible capsule is smooth and normal in contour. There is no visible pancreatic duct dilation. There is no evidence of active peripancreatic inflammation.

**BREED**

Standard Poodle

**Free Abdomen**

There is no evidence of free peritoneal effusion noted in these images.

**SEX**

Neutered Male

There is no apparent lymphadenopathy noted in these images.

**AGE**

8

There is no evidence of heart base or pericardial pathology noted in these images at this time. If cardiac function evaluation is desired a full echocardiogram is recommended.

**WEIGHT**

30 kg

**ULTRASONOGRAPHIC FINDINGS**

- Multiple heterogeneous cavitated splenic masses – concerning for infiltrative neoplasia such as sarcoma versus round cell neoplasia versus other. Benign hematomas, extramedullary hematopoiesis, etc. can mimic infiltrative neoplasia and can't be ruled out without tissue sampling but are considered less likely.

**INTERPRETED BY**

Beth Johnson, DVM  
DACVIM

**INTERPRETATION OF THE FINDINGS & FURTHER RECOMMENDATIONS**

Three view thoracic radiographs are recommended for further assessment of cardio-pulmonary status as well as to further evaluate for any evidence of metastatic disease, if not recently evaluated.

Given this patient's clinical presentation, a full echocardiogram may be warranted for further assessment of full cardiac function.

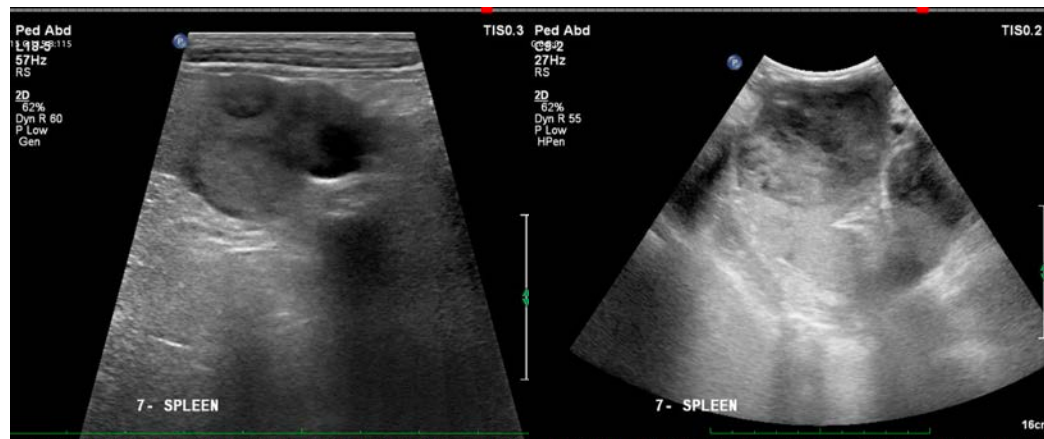
**IMAGING PERFORMED BY**

Meegan Spatz

Ultimately, an exploratory laparotomy for planned splenectomy is recommended.

**HOSPITAL NAME**

Boren Vet Medical  
Teaching Hospital



**REFERRING VET**

Dr. Leandro Fadel

**INVOICE**

46295

**DATE**

3/30/23



**PATIENT**

Rudy O'Kelley

**SPECIES**

Canine

**BREED**

Standard Poodle

**SEX**

Neutered Male

**AGE**

8

**WEIGHT**

30 kg

**INTERPRETED BY**

Beth Johnson, DVM  
DACVIM

**IMAGING PERFORMED BY**

Meegan Spatz

**HOSPITAL NAME**

Boren Vet Medical  
Teaching Hospital

**REFERRING VET**

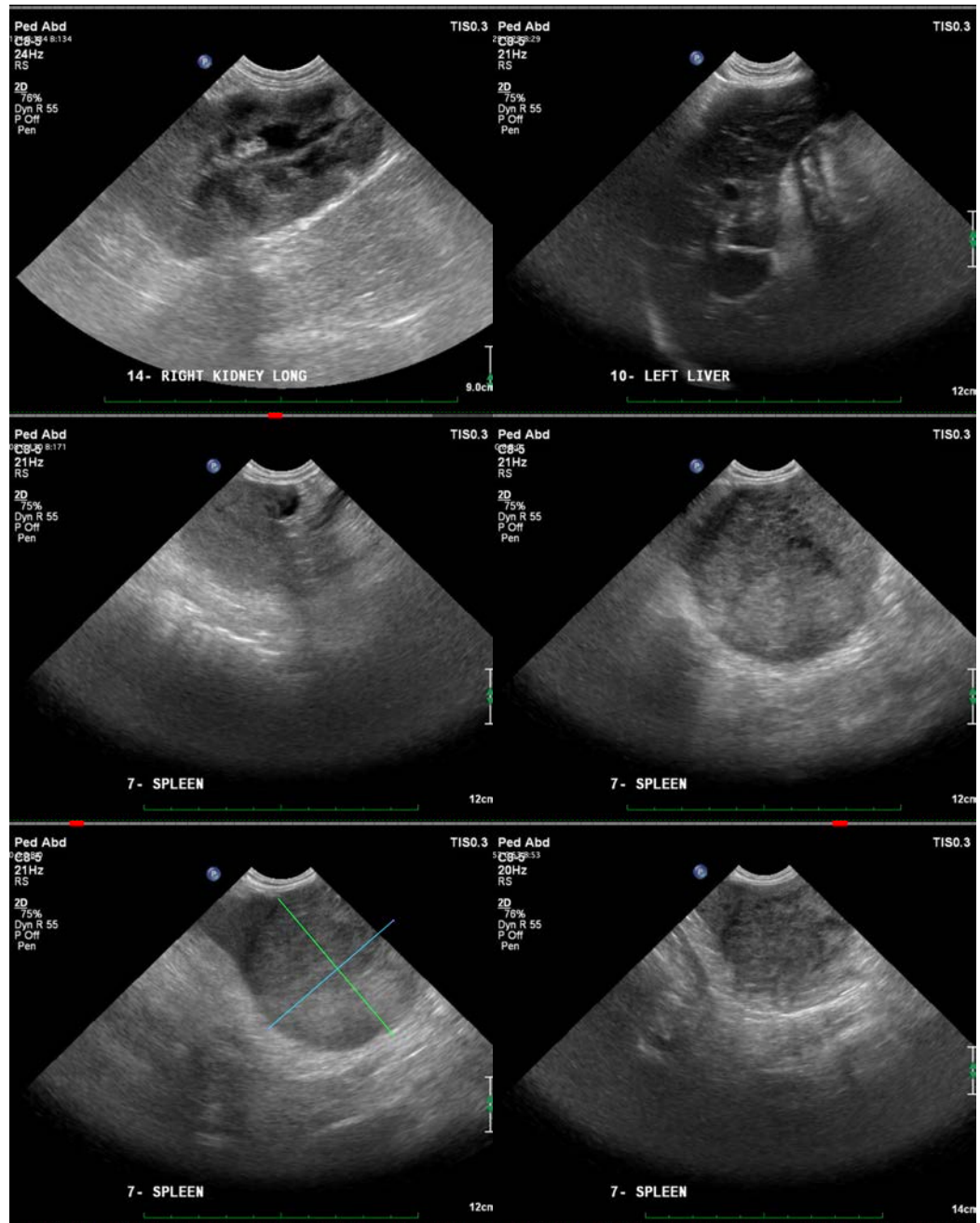
Dr. Leandro Fadel

**INVOICE**

46295

**DATE**

3/30/23





**PATIENT**

Rudy O'Kelley

**SPECIES**

Canine

**BREED**

Standard Poodle

**SEX**

Neutered Male

**AGE**

8

**WEIGHT**

30 kg

**INTERPRETED BY**

Beth Johnson, DVM  
DACVIM

**IMAGING  
PERFORMED BY**

Meegan Spatz

**HOSPITAL NAME**

Boren Vet Medical  
Teaching Hospital

**REFERRING VET**

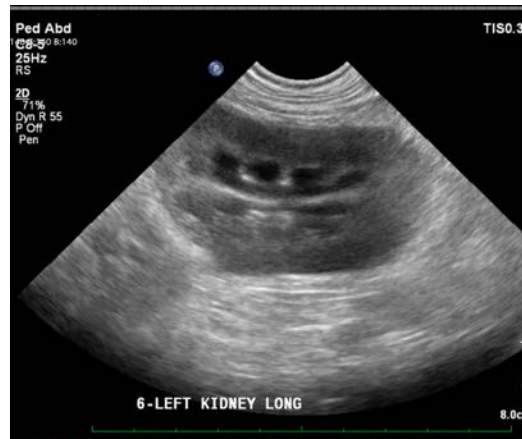Dr. Leandro Fadel

**INVOICE**

46295

**DATE**

3/30/23



The information and recommendations provided are based on the images presented by the referring veterinarian/sonographer. No evaluation can be communicated regarding pathology that was not visible in the image/video clips provided.

Thank you for this referral. If the clinical or image interpretation does not parallel your findings or if I can be of any further assistance please contact me.

**Beth Johnson, DVM, DACVIM**  
Beth.Johnson@sonopath.com