



PATIENT

Madison Lackey

SPECIES

Canine

BREED

Yorkie

SEX

Spayed Female

AGE

6 Years

WEIGHT

9.5 Pounds

INTERPRETED BY

Beth Johnson, DVM
DACVIM

IMAGING PERFORMED BY

Dr. Marti Williams

HOSPITAL NAME

Limestone VH

REFERRING VET

Dr. Marti Williams

INVOICE

46283

DATE

3/30/23

PRESENTING CLINICAL SIGNS

History of ADR: lethargy, shaking, inappetence, staring off into space. Worse in the evening and night. No vomiting or diarrhea. No response to pain medications. Note that dog was fed small amount of food prior to AUS for bile acid test.

Abnormal PE/Chem/CBC/UA Results: Labwork: NSF: Glu 157, Mono 994, USG 1.039, pH 7.5, 1+ protein, UPCR 0.3 negative glucose, 4-10 struvite crystals else WNL.

ULTRASONOGRAPHIC EXAMINATION OF THE ABDOMEN

Urinary System

The urinary bladder is moderately distended with anechoic contents. No masses, inflammatory changes, echogenic sediment or cystoliths are observed. The urinary bladder, trigone and visible pelvic urethra are normal in thickness with a smooth mucosal surface.

The right kidney is normal in size (3.77 cm), shape and echogenicity. It has smooth peripheral margination. There is a normal 1:3 cortex to medulla ratio with appropriate corticomedullary distinction. There is no evidence of pyelectasia, mineral or infarcts observed.

The left kidney is normal in size (3.76 cm), shape and echogenicity. It has smooth peripheral margination. There is a normal 1:3 cortex to medulla ratio with appropriate corticomedullary distinction. There is no evidence of pyelectasia, mineral or infarcts observed.

Adrenal Glands

The right adrenal gland is normal in size (0.54 cm at the cranial pole and 0.64 cm at the caudal pole), shape and contour. Corticomedullary structure is unremarkable. Visible surrounding vasculature appears normal.

The left adrenal gland is normal in size (0.45 cm at the caudal pole), shape and contour. Corticomedullary structure is unremarkable. Visible surrounding vasculature appears normal. The cranial pole is unable to be fully visualized in these images.

Spleen

The spleen is subjectively normal in size with a normal smooth capsular contour. Parenchyma is appropriately finely textured and homogenous with normal echogenicity relative to surrounding tissue (hyperechoic to liver). No focal nodules or masses are observed. Splenic vasculature appears normal.

Liver

The liver is subjectively normal in size with normal smooth curvilinear peripheral contour. Parenchyma is appropriately hypoechoic to the spleen in echogenicity and appropriately mildly coarse and homogenous in echotexture. No focal lesions are observed. Visible vasculature and biliary tree appear normal without distension or congestion.

Gallbladder is moderately distended with anechoic bile as well as moderate suspended and gravity dependent echogenic debris. The wall is smooth without visible thickening. There is no evidence of cystic or CBD dilation. There is no evidence of effusion or inflammation.

Gastrointestinal

The stomach wall is normal in thickness (canine < 0.5 cm and feline < 0.4 cm) and layering. The lumen of the stomach is empty with no evidence of obstruction, foreign material or infiltrative disease. Pyloric outflow tract appears patent.



PATIENT

Madison Lackey

SPECIES

Canine

BREED

Yorkie

SEX

Spayed Female

AGE

6 Years

WEIGHT

9.5 Pounds

INTERPRETED BY

Beth Johnson, DVM
DACVIM

IMAGING PERFORMED BY

Dr. Marti Williams

HOSPITAL NAME

Limestone VH

REFERRING VET

Dr. Marti Williams

INVOICE

46283

DATE

3/30/23

Diffusely, the visible small intestines are normal in wall thickness and layering. Small intestinal motility appears adequate (1-3 contractions per min). However, in the mid abdomen, there is a small bowel loop with a diffusely thick wall measuring 0.70 cm thick. Layering is visible with primarily a thick muscularis layer relative to the mucosa. However, distinct layering is subtle. The lumen of the small intestine is mildly distended with echogenic non-shadowing luminal contents and gas consistent with normal ingesta. There is no evidence of obstruction, foreign material or infiltrative disease.

The visible colon is normal in wall thickness (< 0.2 cm) and layering. Contents are consistent with normal formed feces and gas.

Pancreas

The pancreatic parenchyma is appropriately isoechoic to surrounding tissue. Visible capsule is smooth and normal in contour. There is no visible pancreatic duct dilation. There is no evidence of active peripancreatic inflammation.

Free Abdomen

There is no evidence of free peritoneal effusion noted in these images.

There is no apparent lymphadenopathy noted in these images.

PRIMARY FINDINGS

- Focal mid abdominal small bowel thickening with layering intact but concern for early or emerging loss of layering – Differentials include benign inflammatory bowel disease as well as infiltrative neoplasia, which can't be differentiated fully without tissue sampling.

SECONDARY FINDINGS

- **Moderate gallbladder debris** - Cholecystic debris is of unknown clinical significance. It can be seen with biliary stasis from fasting or illness. Cholecystic debris is not necessarily related to hepatobiliary disease. Echogenic bile is most commonly an incidental finding in dogs and should be interpreted in combination with clinical signs such as nausea, inappetence, cranial abdominal discomfort and/or laboratory changes such as increased ALP and/or increased Tbili.

INTERPRETATION OF THE FINDINGS & FURTHER RECOMMENDATIONS

Given patient breed and subtle reported neurologic clinical signs, bile acid testing (which is reportedly already pending) is a good idea.

Additionally, a gastrointestinal malabsorption panel (including cobalamin, folate, TLI and PLI) to Texas A&M GI Laboratory is recommended for further evaluation of GI and pancreatic function.

Pending results of the above, an exploratory laparotomy for full thickness GI biopsies and potential resection and anastomosis of the focally thickened/mass area could be considered. Endoscopy could be considered as an alternative to surgery. However, I'm concerned that the loop in question is jejunum and may not be able to be reached endoscopically.



PATIENT

Madison Lackey

SPECIES

Canine

BREED

Yorkie

SEX

Spayed Female

AGE

6 Years

WEIGHT

9.5 Pounds

INTERPRETED BY

Beth Johnson, DVM
DACVIM

IMAGING PERFORMED BY

Dr. Marti Williams

HOSPITAL NAME

Limestone VH

REFERRING VET

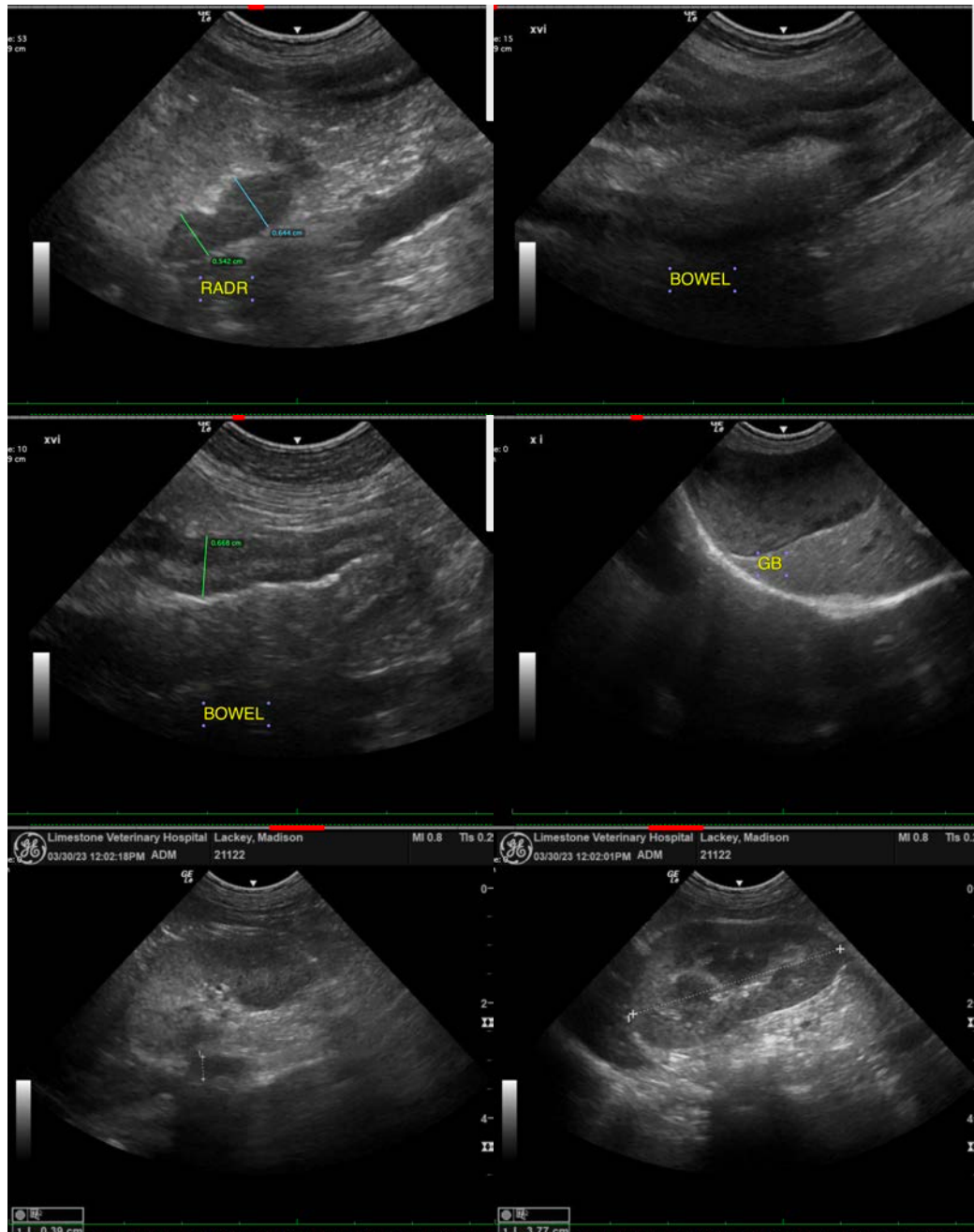
Dr. Marti Williams

INVOICE

46283

DATE

3/30/23





PATIENT

Madison Lackey

SPECIES

Canine

BREED

Yorkie

SEX

Spayed Female

AGE

6 Years

WEIGHT

9.5 Pounds

INTERPRETED BY

Beth Johnson, DVM
DACVIM

IMAGING PERFORMED BY

Dr. Marti Williams

HOSPITAL NAME

Limestone VH

REFERRING VET

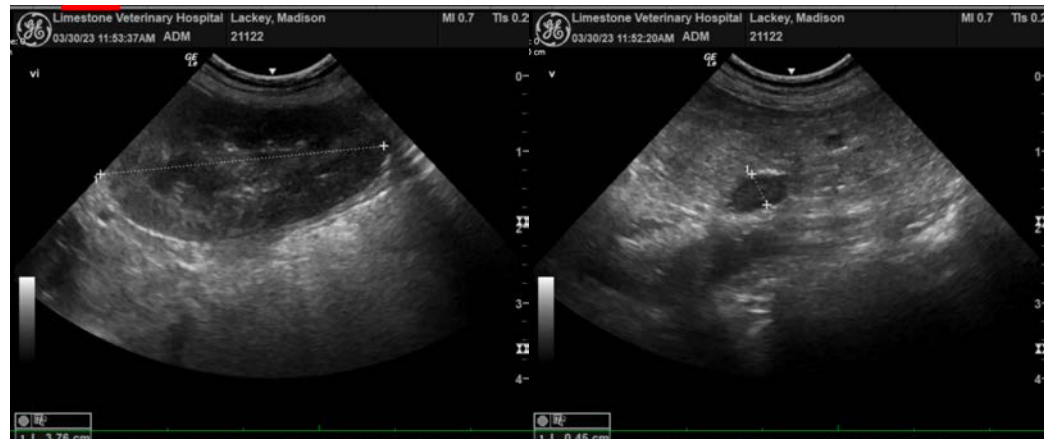
Dr. Marti Williams

INVOICE

46283

DATE

3/30/23



The information and recommendations provided are based on the images presented by the referring veterinarian/sonographer. No evaluation can be communicated regarding pathology that was not visible in the image/video clips provided.

Thank you for this referral. If the clinical or image interpretation does not parallel your findings or if I can be of any further assistance please contact me.

Beth Johnson, DVM, DACVIM
Beth.Johnson@sonopath.com