

**DATE PRESENTING CLINICAL SIGNS**

3/30/23 Chronic elevated ALP, recent blood recheck also revealed elevated ALT, has had diarrhea and weight loss last month.

PATIENT

Cooper Walker Boyd

Current Medications: Denamarin.

Lab Results: See attached.

Date of Previous IntraPet Ultrasound: No previous.

Sedation: Not required to complete full diagnostic ultrasound.

Stat Report: Not requested.

Imaging Performed By: Rachel Brillhart, RDMS.

SPECIES

Canine

BREED

Boston Terrier

SEX

Neutered Male

AGE

5/16/13

WEIGHT

22.5 Pounds

INTERPRETED BYBeth Johnson, DVM
DACVIM**HOSPITAL NAME**

Bayside AMC

REFERRING VET

Dr. Oliver

INVOICE

46313

ULTRASONOGRAPHIC EXAMINATION OF THE ABDOMEN**Urinary System**

The urinary bladder is moderately distended with anechoic contents. No masses or inflammatory changes. Some mineral/sand debris is noted along the dependent wall in the trigone, the proximal urethra, and the intraprostatic urethra. Tiny punctate cystoliths can't be ruled out. The urinary bladder, trigone and visible pelvic urethra are normal in thickness with a smooth mucosal surface.

Prostate is normal in size, echotexture and echogenicity for a neutered male.

The right kidney is normal in size (4.43 cm), shape and echogenicity. It has smooth peripheral margination. There is a normal 1:3 cortex to medulla ratio with appropriate corticomedullary distinction. There is no evidence of pyelectasia, mineral or infarcts observed.

The left kidney is normal in size (4.61 cm), shape and echogenicity. It has smooth peripheral margination. There is a normal 1:3 cortex to medulla ratio with appropriate corticomedullary distinction. There is no evidence of pyelectasia, mineral or infarcts observed.

Adrenal Glands

The right adrenal gland is normal in size (1.91 cm long x 0.60 cm at the cranial pole and 0.68 cm at the caudal pole), shape and contour. Corticomedullary structure is unremarkable. Visible surrounding vasculature appears normal.

The left adrenal gland is normal in size (2.09 cm long x 0.58 cm at the cranial pole and 0.70 cm at the caudal pole), shape and contour. Corticomedullary structure is unremarkable. Visible surrounding vasculature appears normal.

Spleen

The spleen is subjectively normal in size with a normal smooth capsular contour. Parenchyma is appropriately finely textured and homogenous with normal echogenicity relative to surrounding tissue (hyperechoic to liver). No focal nodules or masses are observed. Splenic vasculature appears normal.

Liver

Liver is subjectively enlarged with mildly irregular margins. Parenchyma is markedly heterogenous (almost lacy or moth eaten in appearance) characterized by multiple poorly defined hypoechoic nodules within otherwise hyperechoic liver parenchyma. Visible vasculature and biliary tree appear normal without distension or congestion.

The gallbladder is non-distended in size. The wall is smooth without visible thickening. Luminal contents are primarily anechoic. There is no evidence of cystic or common bile duct dilation.

Gastrointestinal

The stomach wall is normal in thickness (canine < 0.5 cm and feline < 0.4 cm) and layering. The lumen of the stomach is empty with no evidence of obstruction, foreign material or infiltrative disease. Pyloric outflow tract appears patent.

The visible small intestines are normal in wall thickness and layering (canine duodenum < 0.5 cm and feline duodenum < 0.4 cm; other < 0.3 cm). Small intestinal motility appears adequate (1-3 contractions per min). The lumen of the small intestine is empty with no evidence of obstruction, foreign material or infiltrative disease.

The visible colon is normal in wall thickness (< 0.2 cm) and layering. Contents are consistent with normal formed feces and gas.

Pancreas

The observed pancreas appears appropriately isoechoic to surrounding omental fat. The capsule is mildly irregular in shape. Parenchyma is mildly heterogenous and coarse. There is no visible pancreatic duct dilation. There is no evidence of active peripancreatic inflammation.

Free Abdomen

There is no evidence of free peritoneal effusion noted in these images.

There is no apparent lymphadenopathy noted in these images.

ULTRASONOGRAPHIC FINDINGS

- **Markedly heterogeneous, almost moth eaten liver** – This can be seen with benign processes such as nodular hyperplasia, steroid or vacuolar hepatopathy, extramedullary hematopoiesis, or even chronic inflammatory disease. However, given the marked degree, infiltrative neoplasia including round cell neoplasia, metastatic neoplasia, other must also be considered.
- Mineral/sand debris within the urinary bladder and urethra
- **Pancreatic age-related remodeling** – Mild irregularities are consistent with benign age-related change. Low-grade smoldering chronic pancreatitis cannot be ruled out and should be suspected in the face of appropriate clinical signs.

INTERPRETATION OF THE FINDINGS & FURTHER RECOMMENDATIONS

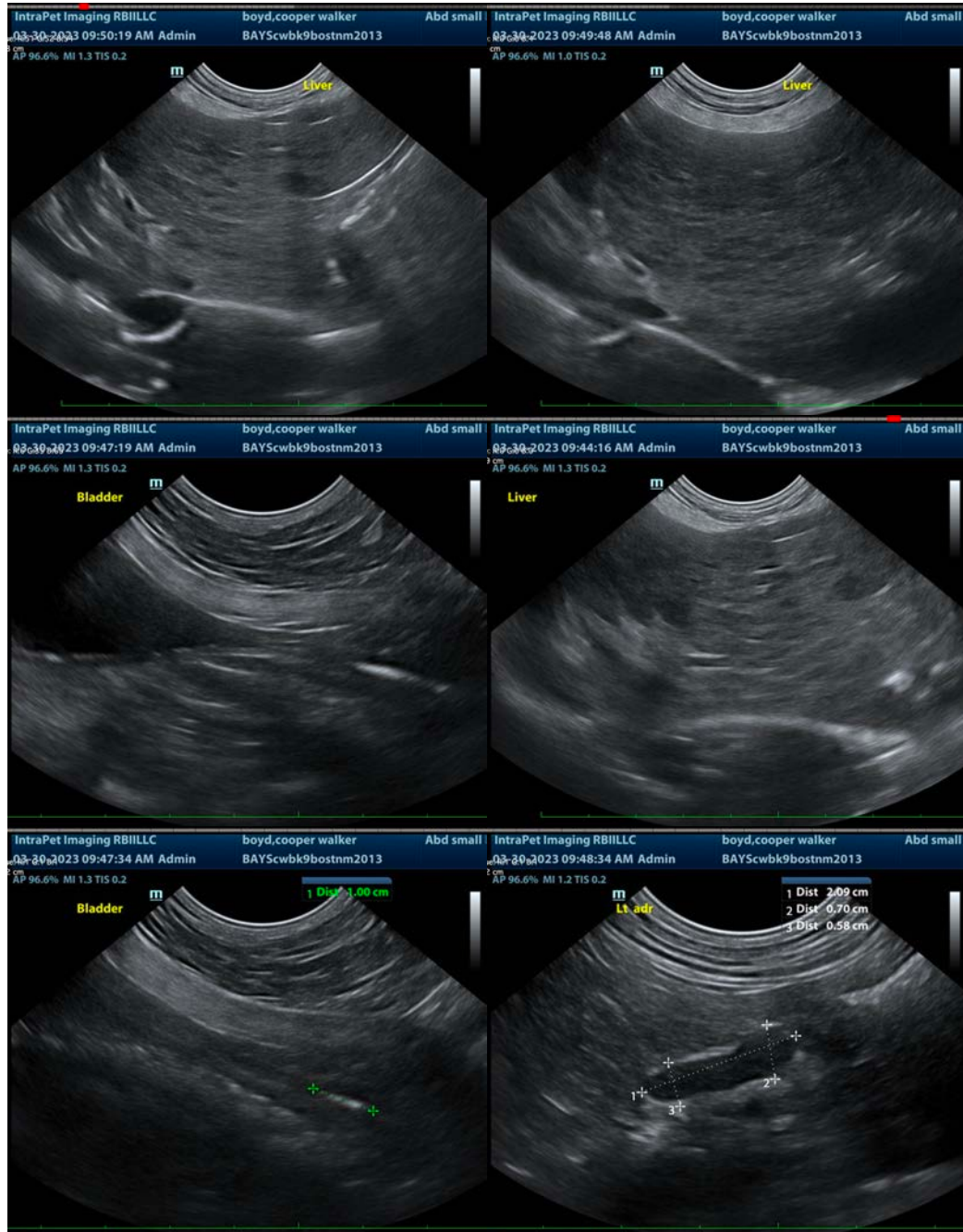
Testing for Leptospirosis is recommended. Bile acids are recommended, if t bili is not increased. An empirical course of antibiotics and hepatic nutraceuticals may be tried empirically; however, ultimately, tissue sampling is likely warranted. FNA of the liver can be performed to assess inflammatory cell type, rule in/out round cell neoplasia, etc. If round cell neoplasia is not diagnosed, a liver biopsy (including copper level assessment) may be required to definitively diagnose the underlying hepatopathy.

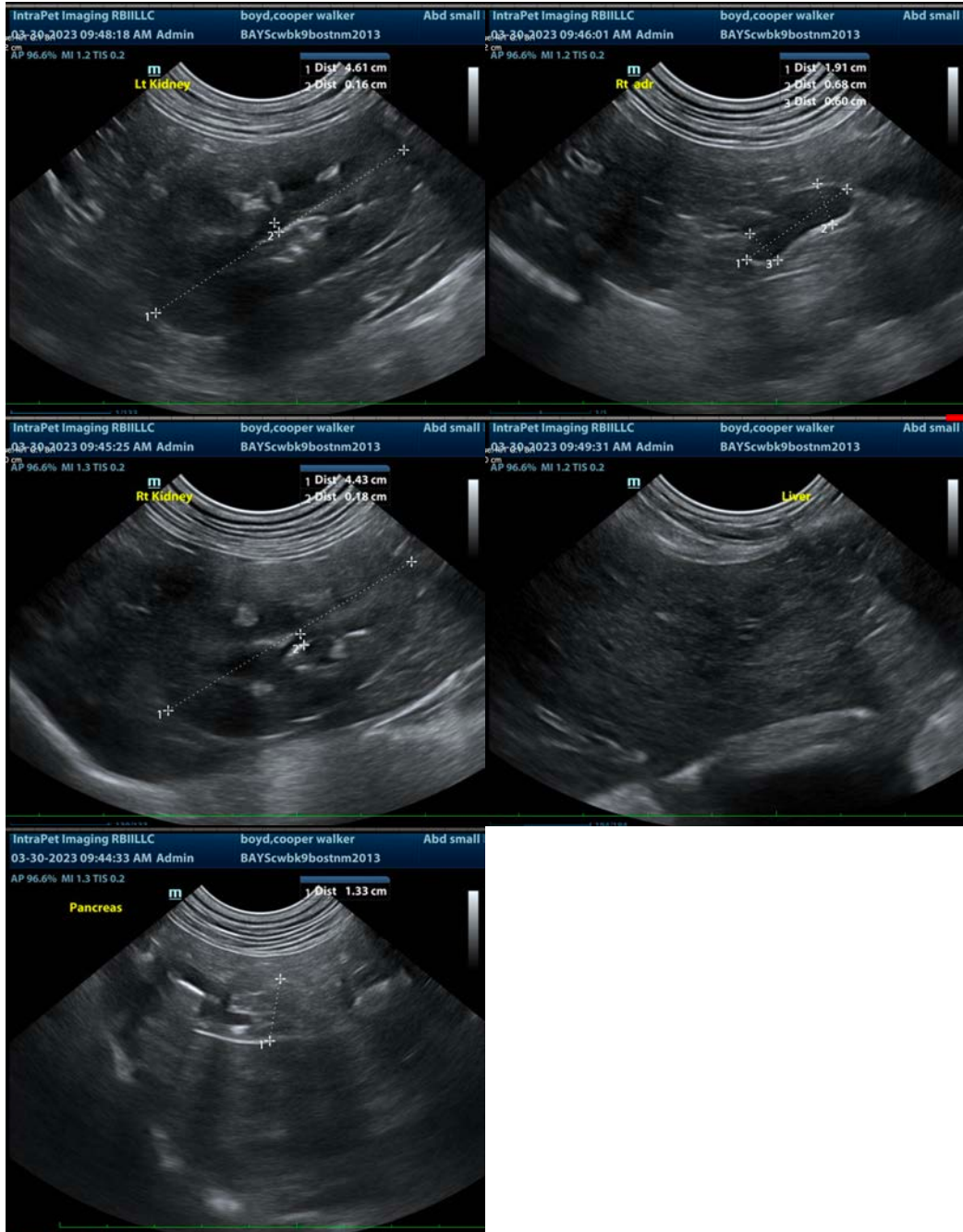
If not recently evaluated, a urinalysis and, if indicated based on urinalysis results, urine culture are recommended. If protein is present in an otherwise quiet sediment, protein quantification with a urine protein to creatinine ration is recommended.

If a diagnosis is not obtained from liver sampling, given this patient's reported weight loss and diarrhea, further evaluation for maldigestive/malabsorptive condition is recommended, beginning with a gastrointestinal malabsorption panel (including cobalamin, folate, TLI and PLI) to Texas A&M GI Laboratory.

An additional consideration could include a fecal enteropathogen PCR panel to Texas A&M GI Laboratory could be considered for further evaluation of possible infectious disease.

In the meantime, while awaiting results, empirical deworming with a 5-day course of Panacur is recommended for the diarrhea as well as a probiotic such as Visbiome or Provioble.





The information and recommendations provided are based on the images presented by the referring veterinarian/sonographer. No evaluation can be communicated regarding pathology that was not visible in the image/video clips provided.

Thank you for this referral. If the clinical or image interpretation does not parallel your findings or if I can be of any further assistance please contact me.

Beth Johnson, DVM, DACVIM
Beth.Johnson@sonopath.com