



PATIENT

Hudson Alford

SPECIES

Canine

BREED

Goldendoodle

SEX

Neutered Male

AGE

3 Years 10 Months

WEIGHT

41 lbs

INTERPRETED BY

Beth Johnson, DVM
DACVIM

IMAGING PERFORMED BY

Kathleen Byrnes

HOSPITAL NAME

Stoney Creek
Veterinary Hospital

REFERRING VET

Dr. Zamoborsky

INVOICE

73345

DATE

3/3/26

PRESENTING CLINICAL SIGNS

P presented for US due to PU/PD, usg 1.002. Sedated with Dex and Torb.

ULTRASONOGRAPHIC EXAMINATION OF THE ABDOMEN

Urinary System

The urinary bladder is adequately distended with anechoic contents. No masses, inflammatory changes, echogenic sediment or cystoliths are observed. The urinary bladder, trigone and visible pelvic urethra are normal in thickness with a smooth mucosal surface.

Prostate is normal in size, echotexture and echogenicity for a neutered male.

The right kidney is normal is size (5.03 cm), shape and echogenicity. It has smooth peripheral margination. There is a normal 1:3 cortex to medulla ratio with appropriate corticomedullary distinction. There is no evidence of pyelectasia, mineral or infarcts observed. A very mild/subtle hyperechoic band parallel to the corticomedullary border is present.

The left kidney is normal is size (5.09 cm), shape and echogenicity. It has smooth peripheral margination. There is a normal 1:3 cortex to medulla ratio with appropriate corticomedullary distinction. There is no evidence of pyelectasia, mineral or infarcts observed. A very mild/subtle hyperechoic band parallel to the corticomedullary border is present.

Adrenal Glands

The right adrenal gland is normal in size (0.98 cm at cranial pole and 0.41 cm at caudal pole), shape and overall architecture, echogenicity and echotexture. Visible surrounding vasculature appears normal.

The left adrenal gland is normal in size (0.51 cm at cranial pole and 0.39 cm at caudal pole), shape and overall architecture, echogenicity and echotexture. Visible surrounding vasculature appears normal.

Spleen

The spleen is subjectively normal in size with a normal smooth capsular contour. Parenchyma is appropriately finely textured and homogenous with normal echogenicity relative to surrounding tissue (hyperechoic to liver). No focal nodules or masses are observed. Splenic vasculature appears normal.

Liver

The liver is subjectively normal in size with normal smooth curvilinear peripheral contour. Parenchyma is appropriately hypoechoic to the spleen in echogenicity and appropriately mildly coarse and homogenous in echotexture. No focal lesions are observed. Visible vasculature and biliary tree appear normal without distension or congestion.

The gallbladder is non-distended in size. The wall is smooth without visible thickening. Luminal contents are primarily anechoic. There is no evidence of cystic or common bile duct dilation.

Gastrointestinal

The visible stomach wall is normal in thickness and layering. The stomach is moderately distended with echogenic non-shadowing luminal contents and gas consistent with normal ingesta. There is no evidence of obstruction, foreign material or infiltrative disease. If patient was appropriately fasted,



PATIENT

Hudson Alford

SPECIES

Canine

BREED

Goldendoodle

SEX

Neutered Male

AGE

3 Years 10 Months

WEIGHT

41 lbs

INTERPRETED BY

Beth Johnson, DVM
DACVIM

IMAGING PERFORMED BY

Kathleen Byrnes

HOSPITAL NAME

Stoney Creek
Veterinary Hospital

REFERRING VET

Dr. Zamoborsky

INVOICE

73345

DATE

3/3/26

delayed gastric emptying could be considered. Non-shadowing foreign material is considered less likely but cannot be definitively ruled out.

If clinical signs are consistent (vomiting, etc.), recommendations include supportive medical care, 24 hours fasting and re-image.

The visible small intestines are normal in wall thickness and layering. Small intestinal motility appears adequate (1-3 contractions per min). The lumen of the small intestine is empty with no evidence of obstruction, foreign material or infiltrative disease.

The visible colon is normal in wall thickness (< 0.2 cm) and layering. Contents are consistent with normal formed feces and gas.

Pancreas

The pancreas that is observed appears appropriately isoechoic to surrounding omental fat. Visible capsule is smooth and normal in contour. Visible pancreatic parenchyma is homogenous and unremarkable. There is no visible pancreatic duct dilation. There is no evidence of active peripancreatic inflammation.

Free Abdomen

There is no visible free peritoneal effusion noted in these images.

There is no apparent pathologic lymphadenopathy noted in these images.

ULTRASONOGRAPHIC FINDINGS

- Very mild/subtle bilateral medullary rim sign - This finding is of unknown clinical significance and can be a normal variant, often idiopathic. Medullary rim sign can be present with renal disease including lymphoma, hypercalcemic nephropathy, Leptospirosis, tubular disease, other and should be interpreted in combination with other more specific indications of kidney disease such as isosthenuria, proteinuria, azotemia, etc. This is a common incidental finding in patients with diabetes mellitus.

INTERPRETATION OF THE FINDINGS & FURTHER RECOMMENDATIONS

Differentials for PU/PD are vast and include, but are not limited to:

Primary polyuria caused by chronic kidney disease, pyelonephritis, liver disease, diabetes mellitus, hyperthyroidism, hypercalcemia, hyperadrenocorticism, hypoadrenocorticism, E.coli infections ie) pyometra in females, polycythemia, central diabetes insipidus or primary nephrogenic diabetes insipidus.

Primary polydipsia caused by psychogenic polydipsia, fever, pain, or central nervous system disease.

Most causes of PU/PD can be diagnosed with a comprehensive history and physical exam, a first AM urine specific gravity to see if urine concentration is possible (as most animals naturally consume less water overnight) followed by a comprehensive CBC, serum chemistry panel, electrolytes, and urinalysis.

If not, next step(s) may include a urine culture, low dose dexamethasone suppression test, T4, bile acids, Leptospirosis testing and/or an empirical course of antibiotics.



PATIENT

Hudson Alford

SPECIES

Canine

BREED

Goldendoodle

SEX

Neutered Male

AGE

3 Years 10 Months

WEIGHT

41 lbs

INTERPRETED BY

Beth Johnson, DVM
 DACVIM

IMAGING PERFORMED BY

Kathleen Byrnes

HOSPITAL NAME

Stoney Creek
 Veterinary Hospital

REFERRING VET

Dr. Zamoborsky

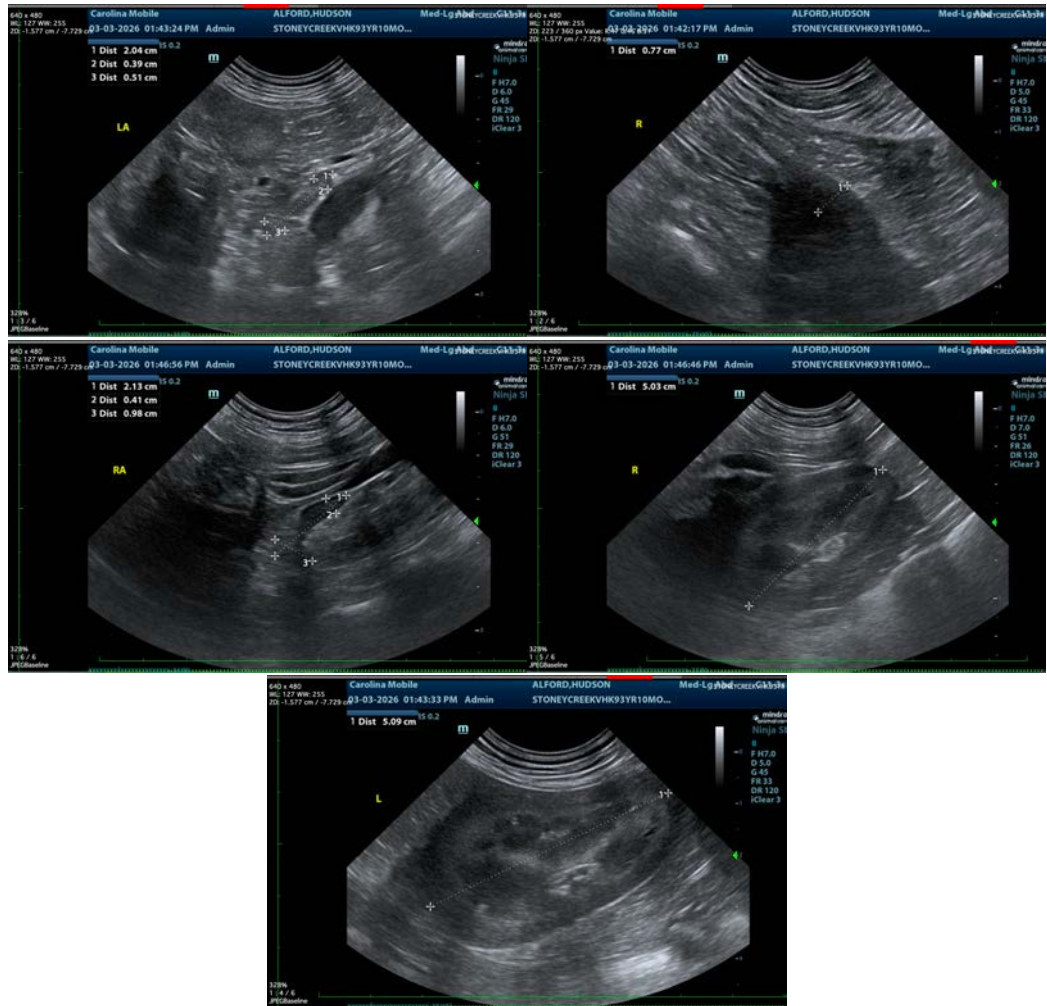
INVOICE

73345

DATE

3/3/26

If a diagnosis is still not obtained, a more advanced work-up is indicated and consultation with an internist may be warranted.



The information and recommendations provided are based on the images presented by the referring veterinarian/sonographer. No evaluation can be communicated regarding pathology that was not visible in the image/video clips provided.

Thank you for this referral. If the clinical or image interpretation does not parallel your findings or if I can be of any further assistance please contact me.

Beth Johnson, DVM, DACVIM
 info@sonopath.com