

**DATE PRESENTING CLINICAL SIGNS**

3/29/23 Patient presented with masses in mammary chain. Came back consistent with mammary gland carcinoma. Ultrasound recommended to check for metastasis.

**PATIENT**

Roxanne Henderson

Current Medications: None listed.

Date of Previous IntraPet Ultrasound: No previous.

Sedation: Not required to complete full diagnostic ultrasound.

Stat Report: Not requested. Heart check declined at this time.

Imaging Performed By: Stephanie Warga RDCS, RVT.

**SPECIES**

Canine

**ULTRASONOGRAPHIC EXAMINATION OF THE ABDOMEN****BREED**

Toy Poodle

**Urinary System**

The urinary bladder is moderately distended with anechoic contents. No masses, inflammatory changes, echogenic sediment or cystoliths are observed. The urinary bladder, trigone and visible pelvic urethra are normal in thickness with a smooth mucosal surface.

**SEX**

Intact Female

The right kidney is normal in size (3.13 cm), shape and echogenicity. It has smooth peripheral margination. There is a normal 1:3 cortex to medulla ratio with appropriate corticomedullary distinction. There is no evidence of pyelectasia, mineral or infarcts observed.

**AGE**

11/1/13

The left kidney is normal in size (3.06 cm), shape and echogenicity. It has smooth peripheral margination. There is a normal 1:3 cortex to medulla ratio with appropriate corticomedullary distinction. There is no evidence of pyelectasia, mineral or infarcts observed.

**WEIGHT**

2.54 Pounds

**Adrenal Glands**

The right adrenal gland is normal in size (1.43 cm long x 0.46 cm at the cranial pole and 0.51 cm at the caudal pole), shape and contour. Corticomedullary structure is unremarkable. Visible surrounding vasculature appears normal.

**INTERPRETED BY**Beth Johnson, DVM  
DACVIM

The left adrenal gland is normal in size (1.29 cm long x 0.54 cm at the cranial pole and 0.46 cm at the caudal pole), shape and contour. Corticomedullary structure is unremarkable. Visible surrounding vasculature appears normal.

**HOSPITAL NAME**

Banfield Timonium

**Spleen**

The spleen is subjectively normal in size with a normal smooth capsular contour. Parenchyma is appropriately finely textured and homogenous with normal echogenicity relative to surrounding tissue (hyperechoic to liver). A 0.80 cm x 0.30 cm hypo- to anechoic non-capsule disrupting nodule is noted near the head of the spleen. Splenic vasculature appears normal.

**REFERRING VET**

Dr. Kameka

**INVOICE**

46278

**Liver**

Liver is subjectively enlarged with mildly irregular margins. Parenchyma is heterogenous characterized by multiple poorly defined hypoechoic nodules within otherwise hyperechoic liver parenchyma. Visible vasculature and biliary tree appear normal without distension or congestion.

Gallbladder is moderately distended with anechoic bile as well as moderate suspended and gravity dependent echogenic debris. The wall is smooth without visible thickening. There is no evidence of cystic or CBD dilation. There is no evidence of effusion or inflammation.

### ***Gastrointestinal***

The stomach wall is normal in thickness (canine < 0.5 cm and feline < 0.4 cm) and layering. The lumen of the stomach is empty with no evidence of obstruction, foreign material or infiltrative disease. Pyloric outflow tract appears patent.

The visible small intestines are normal in wall thickness and layering (canine duodenum < 0.5 cm and feline duodenum < 0.4 cm; other < 0.3 cm). Small intestinal motility appears adequate (1-3 contractions per min). The lumen of the small intestine is empty with no evidence of obstruction, foreign material or infiltrative disease.

The visible colon is normal in wall thickness (< 0.2 cm) and layering. Contents are consistent with normal formed feces and gas.

### ***Pancreas***

The pancreatic parenchyma is appropriately isoechoic to surrounding tissue. Visible capsule is smooth and normal in contour. There is no visible pancreatic duct dilation. There is no evidence of active peripancreatic inflammation.

### ***Free Abdomen***

There is no evidence of free peritoneal effusion noted in these images.

The mesenteric lymph nodes are prominent in size with swollen capsular contour. Normal elongated shape (length to width ratio) is maintained. There is no loss of parenchymal detail.

Both ovaries and the uterus are visualized without evident ovarian or uterine pathology.

## **ULTRASONOGRAPHIC FINDINGS**

- **Heterogenous Liver** – These changes are most consistent with benign processes such as nodular hyperplasia, steroid (vacuolar) hepatopathy, extramedullary hematopoiesis or possibly chronic inflammatory disease and less commonly infiltrative round cell or metastatic neoplasia.
- **Hypo to anechoic splenic nodule** – likely represents a benign lesion such as a cyst, hematoma, nodular hyperplasia, extramedullary hematopoiesis, etc., however while considered less likely, infiltrative neoplasia can mimic benign lesions, and cannot be ruled out.
- **Reactive mesenteric lymph nodes** – infiltrative neoplastic disease cannot be ruled out but is considered less likely.
- **Moderate gallbladder debris** - Cholecystic debris is of unknown clinical significance. It can be seen with biliary stasis from fasting or illness. Cholecystic debris is not necessarily related to hepatobiliary disease. Echogenic bile is most commonly an incidental finding in dogs and should be interpreted in combination with clinical signs such as nausea, inappetence, cranial abdominal discomfort and/or laboratory changes such as increased ALP and/or increased Tbili.

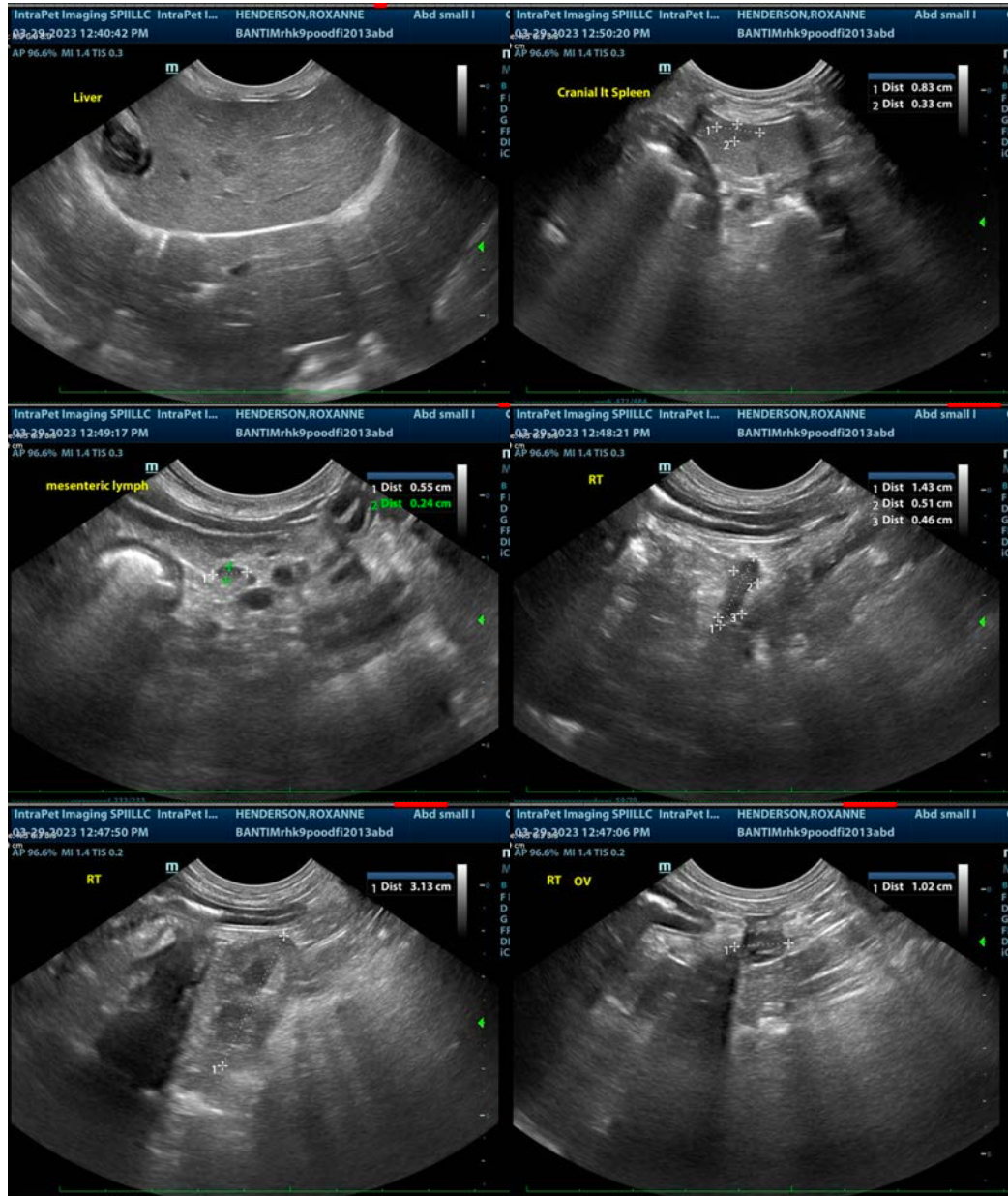
## **INTERPRETATION OF THE FINDINGS & FURTHER RECOMMENDATIONS**

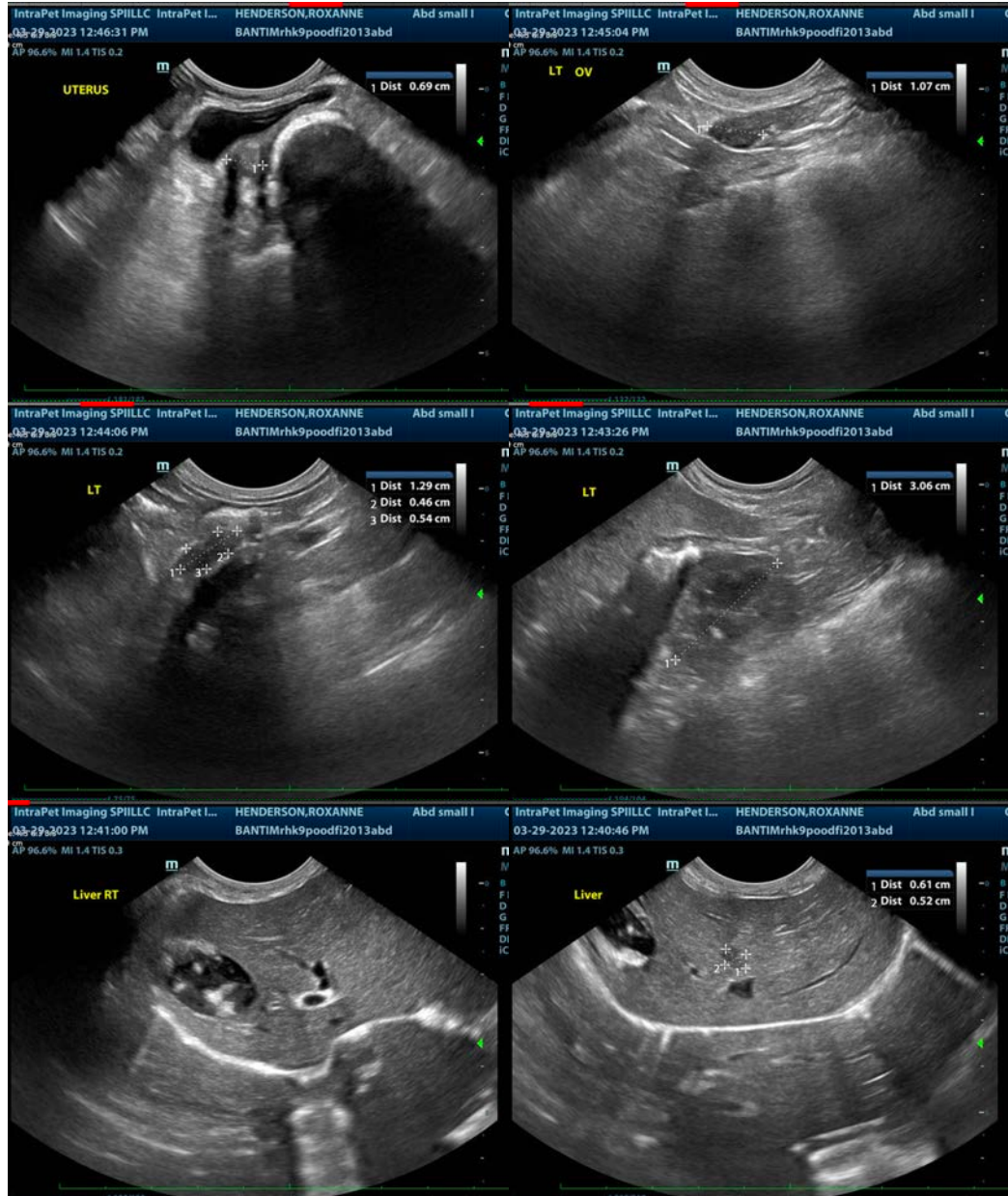
If not recently evaluated, Three view thoracic radiographs are recommended for further assessment of cardio-pulmonary status as well as to further evaluate for any evidence of metastatic disease, if not recently evaluated.

While both the spleen and liver changes trend in appearance toward benign, fine needle aspirates could be considered if patient's coagulation status is appropriate.

The mesenteric lymph nodes are likely too small to be sampled. However, if they can safely be reached, aspirates could be obtained of the lymph nodes as well.

Surgery will likely be the treatment of choice for this patient, at which time spay is also recommended. However, consultation with a veterinary oncologist is recommended prior to pursuing therapy, if possible.





The information and recommendations provided are based on the images presented by the referring veterinarian/sonographer. No evaluation can be communicated regarding pathology that was not visible in the image/video clips provided.

Thank you for this referral. If the clinical or image interpretation does not parallel your findings or if I can be of any further assistance please contact me.

**Beth Johnson, DVM, DACVIM**  
Beth.Johnson@sonopath.com