

**DATE PRESENTING CLINICAL SIGNS**

3/29/23 Ate rib bones two nights ago. Has watery, bloody diarrhea. Vomited 4 times yesterday.

PATIENT Current Medications: Cerenia given yesterday, 1000mL SubQ fluids yesterday and IV fluids today.
Date of Previous IntraPet Ultrasound: No previous.

Milk Chocolate Jones Sedation: Not required to complete full diagnostic ultrasound.

Stat Report: Not requested.

Imaging Performed By: Stephanie Warga RDCS, RVT.

SPECIES

Canine

ULTRASONOGRAPHIC EXAMINATION OF THE ABDOMEN**BREED**

Bulldog

Urinary System

The urinary bladder is moderately distended with anechoic contents. No masses, inflammatory changes, echogenic sediment or cystoliths are observed. The urinary bladder, trigone and visible pelvic urethra are normal in thickness with a smooth mucosal surface.

SEX

Intact Male

Prostate is normal in size for an intact male (4.1 cm wide). Parenchyma is diffusely homogenous and relatively hyperechoic. Normal distinct margins and symmetrical bilobed shape are maintained.

AGE

7/27/19

The right kidney is normal in size (6.99 cm), shape and echogenicity. It has smooth peripheral margination. There is a normal 1:3 cortex to medulla ratio with appropriate corticomedullary distinction. There is no evidence of pyelectasia, mineral or infarcts observed.

WEIGHT

68 Pounds

The left kidney is normal in size (6.77 cm), shape and echogenicity. It has smooth peripheral margination. There is a normal 1:3 cortex to medulla ratio with appropriate corticomedullary distinction. There is no evidence of pyelectasia, mineral or infarcts observed.

INTERPRETED BY

Beth Johnson, DVM
DACVIM

Adrenal Glands

The right adrenal gland is normal in size (2.61 cm long x 0.67 cm at the cranial pole and 0.76 cm at the caudal pole), shape and contour. Corticomedullary structure is unremarkable. Visible surrounding vasculature appears normal.

HOSPITAL NAME

Main Street

The left adrenal gland is normal in size (3.07 cm long x 0.46 cm at the cranial pole and 0.47 cm at the caudal pole), shape and contour. Corticomedullary structure is unremarkable. Visible surrounding vasculature appears normal.

REFERRING VET

Dr. Nabozny

Spleen

The spleen is subjectively normal in size with a normal smooth capsular contour. Parenchyma is appropriately finely textured and homogenous with normal echogenicity relative to surrounding tissue (hyperechoic to liver). No focal nodules or masses are observed. Splenic vasculature appears normal.

INVOICE

46275

Liver

The liver is subjectively normal in size with normal smooth curvilinear peripheral contour. Parenchyma is appropriately hypoechoic to the spleen in echogenicity and appropriately mildly coarse and homogenous in echotexture. No focal lesions are observed. Visible vasculature and biliary tree appear normal without distension or congestion.

The gallbladder is non-distended in size. The wall is smooth without visible thickening. Luminal contents are primarily anechoic. There is no evidence of cystic or common bile duct dilation.

Gastrointestinal

The stomach wall is normal in thickness (canine < 0.5 cm and feline < 0.4 cm) and layering. The lumen of the stomach is mildly fluid dilated with no evidence of obstruction, foreign material or infiltrative disease. Pyloric outflow tract appears patent.

The visible small intestines are normal in wall thickness and layering (canine duodenum < 0.5 cm and feline duodenum < 0.4 cm; other < 0.3 cm). Small intestinal motility appears adequate (1-3 contractions per min). The lumen of the small intestine is empty with no evidence of obstruction, foreign material or infiltrative disease.

The colon wall is mildly thick, primarily in the descending colon, measuring between 0.20-0.40 cm with normal intact layering preserved. Contents in the proximal colon appear to be liquid, transitioning into more normal hard shadowing stool distally.

Pancreas

The pancreatic parenchyma is appropriately isoechoic to surrounding tissue. Visible capsule is smooth and normal in contour. There is no visible pancreatic duct dilation. There is no evidence of active peripancreatic inflammation.

Free Abdomen

There is no evidence of free peritoneal effusion noted in these images.

The mesenteric lymph nodes are prominent in size with swollen capsular contour. Normal elongated shape (length to width ratio) is maintained. There is no loss of parenchymal detail.

Both testicles were visualized without evidence of testicular pathology.

ULTRASONOGRAPHIC FINDINGS

- **Mildly thick colon wall** – Given the patient's history and colonic contents, this is most consistent with a benign inflammatory colitis. Concurrent parasitic, infectious, other disease can't be ruled out. Infiltrative neoplasia is possible but considered less likely.
- **Reactive mesenteric lymph nodes** – infiltrative neoplastic disease cannot be ruled out but is considered less likely.

INTERPRETATION OF THE FINDINGS & FURTHER RECOMMENDATIONS

There is no visible evidence of obstruction in these images at this time, but given this patient's history dietary indiscretion, recommendations include empirical supportive/symptomatic medical management of likely dietary indiscretion, including antiemetics, gastroprotectants, a probiotic such as Visbiome or Provable, empirical deworming with a 5-day course of Panacur, and if tolerated a short term course of a bland, easy to digest or possibly fiber responsive diet.

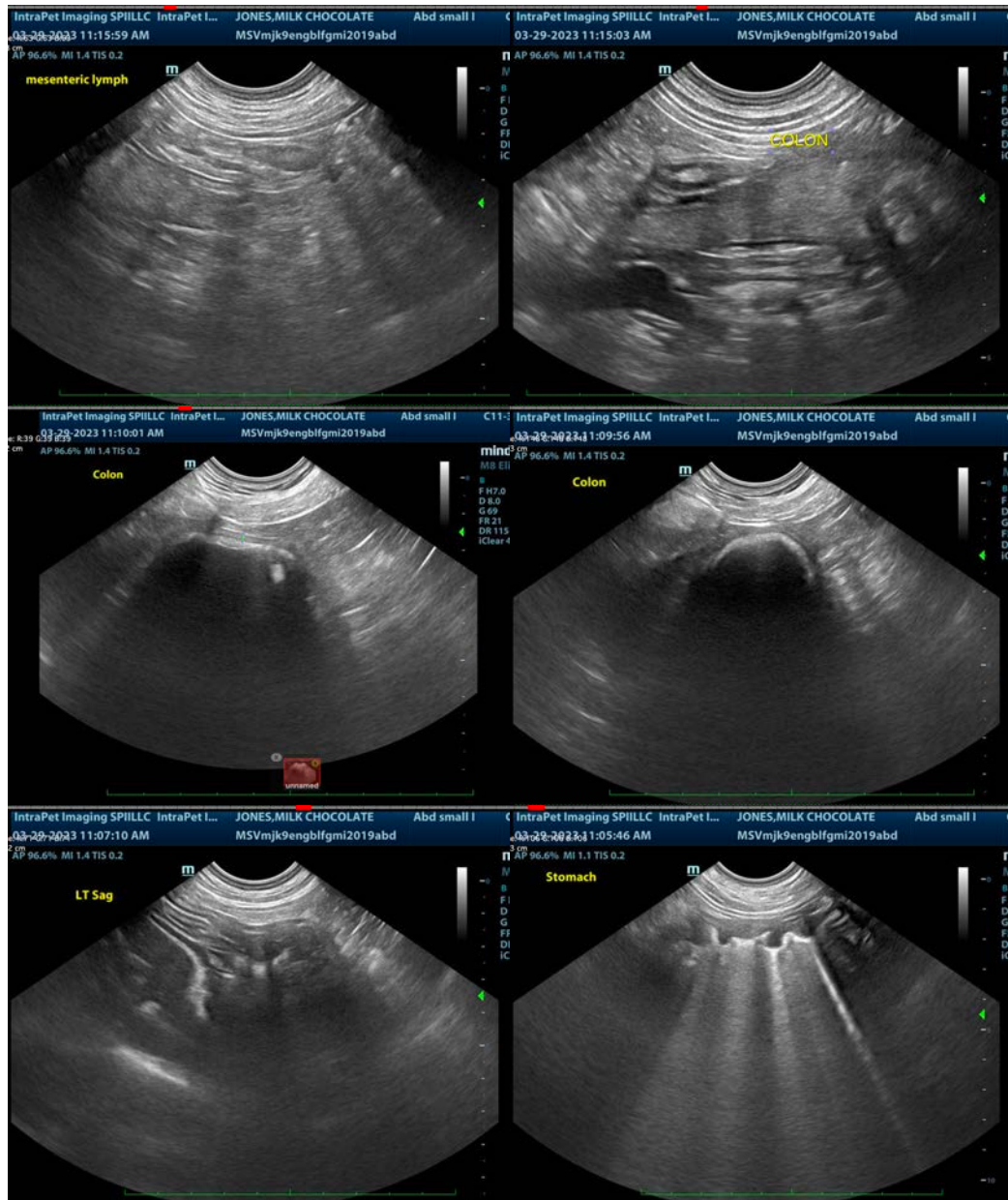
If clinical signs persist and/or progress, suggesting this event may not be related to the rib ingestion, further workup is recommended including:

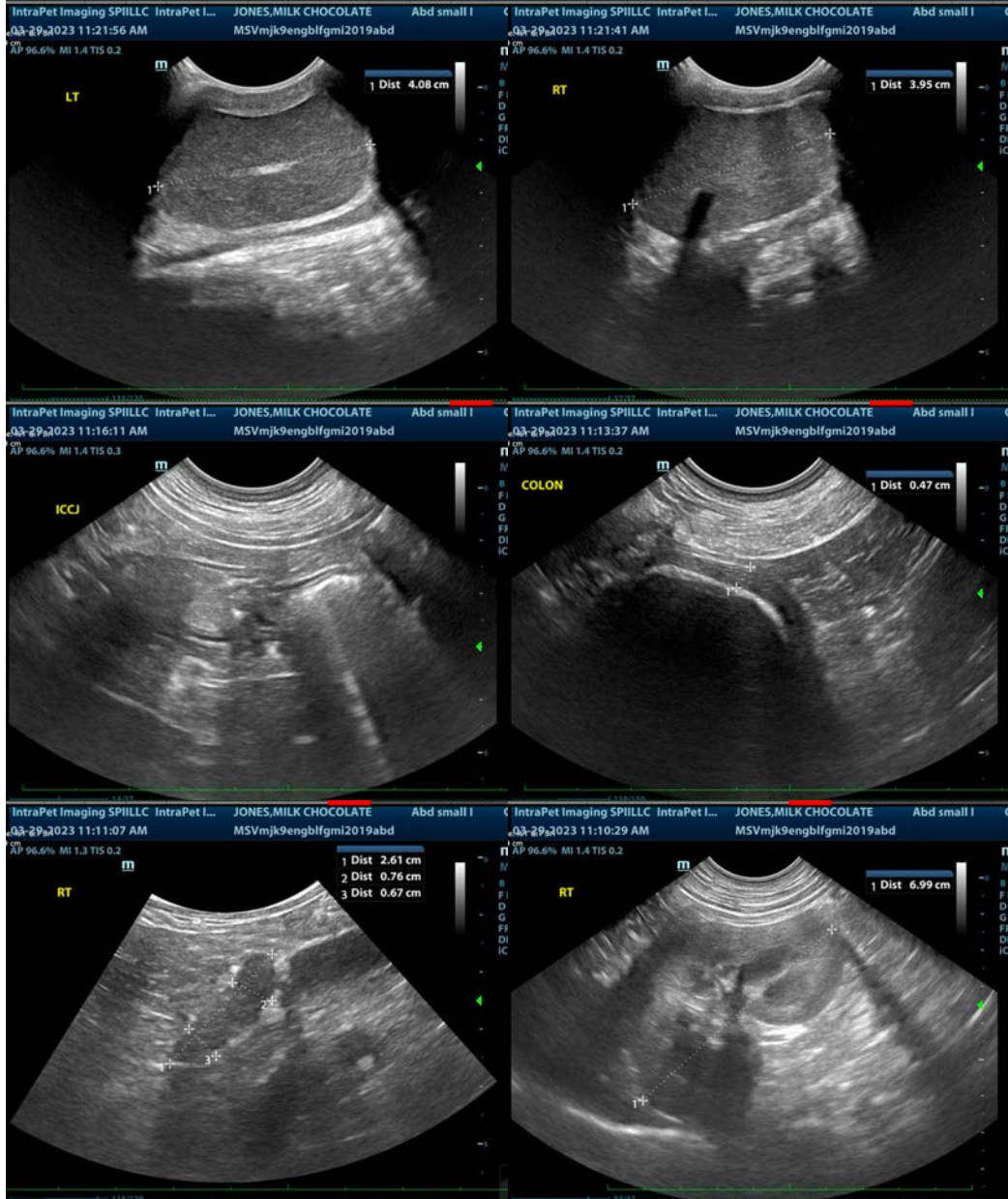
A gastrointestinal malabsorption panel (including cobalamin, folate, TLI and PLI) to Texas A&M GI Laboratory is recommended for further evaluation of GI and pancreatic function.

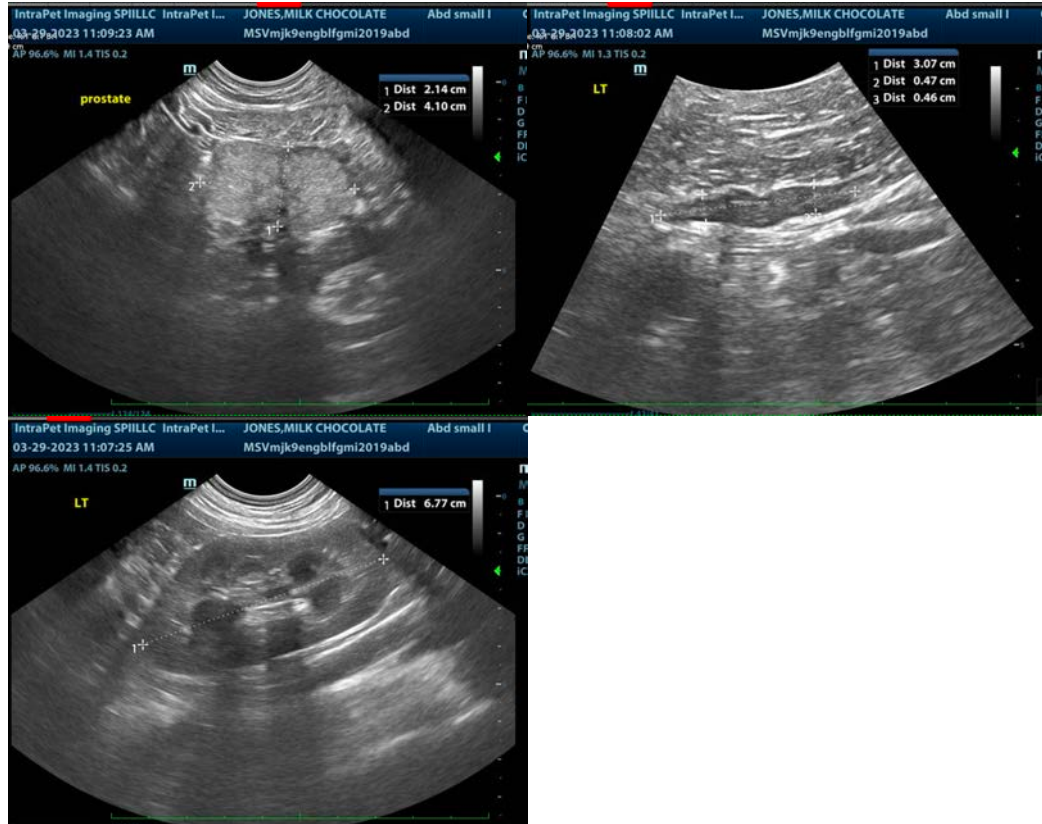
A baseline cortisol is recommended. If baseline cortisol is less than 2, a full ACTH stimulation test is recommended to rule out hypoadrenocorticism.

A fecal enteropathogen PCR panel to Texas A&M GI Laboratory could be considered for further evaluation of possible infectious disease.

Ultimately, if clinical signs persist, and a diagnosis is not reached, further evaluation of the GI tract via upper and lower endoscopy for visualization and biopsies may be warranted.







The information and recommendations provided are based on the images presented by the referring veterinarian/sonographer. No evaluation can be communicated regarding pathology that was not visible in the image/video clips provided.

Thank you for this referral. If the clinical or image interpretation does not parallel your findings or if I can be of any further assistance please contact me.

Beth Johnson, DVM, DACVIM
Beth.Johnson@sonopath.com