



<b>PATIENT</b>	<b>PRESENTING CLINICAL SIGNS</b>
Georgina Vieira	Still not eating, sniffing at the food but not eating, More social and interactive and holding head up more. Had a small tiny hard bm after enema yesterday. Urinated. Offered multiple foods but not eating yet.
<b>SPECIES</b>	Given cerenia, mirtazapine. Bilirubin is improving (was 33 and now 20) and icterus, anemia is better too. Albumin ok. All liver values remain in normal range (ALT, ALP and AST) PE: mm light pink, CRT <2sec, 7% dehydrated, more vocal and holds head up more. BCS 2.5/5- HR 200, rr 24, abdomen palpates with multiple hard firm stools that can still be compressed digitally but are quite hard =especially the distal stool in colon Current Medications Mirataz, Cerenia, Lactulose, cisapride - Gabapentin
Feline	
<b>BREED</b>	
DSH	
<b>SEX</b>	<b>ULTRASONOGRAPHIC EXAMINATION OF THE ABDOMEN</b>
Spayed Female	<b>Urinary System</b>
<b>AGE</b>	The urinary bladder is moderately distended with anechoic contents. No masses, inflammatory changes, echogenic sediment or cystoliths are observed. The urinary bladder, trigone and visible pelvic urethra are normal in thickness with a smooth mucosal surface.
18 Years	Kidneys are overall normal in size and shape with smooth peripheral margination. A normal 1:3 cortex to medulla ratio is maintained. The medulla and cortices are uniform in texture with some mild increased cortical echogenicity and mild loss of corticomedullary distinction, expected in this age patient. There is no evidence of pyelectasia or infarcts observed. A small non-obstructive nephrolith is noted in the right kidney. The right kidney measured 3.32 cm. The left kidney measured 3.38 cm.
<b>WEIGHT</b>	
2.85 kg	
<b>INTERPRETED BY</b>	<b>Adrenal Glands</b>
Beth Johnson, DVM DACVIM	The right adrenal gland is normal in size (0.14 cm), shape and contour. Corticomedullary structure is unremarkable. Visible surrounding vasculature appears normal.
	The left adrenal gland is normal in size (0.22 cm), shape and contour. Corticomedullary structure is unremarkable. Visible surrounding vasculature appears normal.
<b>IMAGING PERFORMED BY</b>	<b>Spleen</b>
Kelly Reschny	Spleen is subjectively large in size with normal smooth margins. Parenchyma is normal in echogenicity with a coarse/heterogenous echotexture. No focal nodules or masses are observed. Splenic vasculature appears normal.
<b>HOSPITAL NAME</b>	<b>Liver</b>
Windrush VS	Liver is subjectively enlarged (swollen contour). Mild parenchymal remodeling with diffusely mildly coarse architecture and increased portal markings is present. No focal nodules or masses are observed. Visible vasculature appears normal without distension or congestion. The intrahepatic biliary tree contains multifocal punctate mineral densities.
<b>REFERRING VET</b>	
Dr. McGrath	
<b>INVOICE</b>	
46260	The gallbladder is non-distended in size. The wall is smooth without visible thickening. Luminal contents are primarily anechoic. There is no evidence of cystic or common bile duct dilation.
<b>DATE</b>	<b>Gastrointestinal</b>
3/29/23	The stomach wall is normal in thickness (canine < 0.5 cm and feline < 0.4 cm) and layering. The lumen of the stomach is empty with no evidence of obstruction, foreign material or infiltrative disease. Pyloric outflow tract appears patent.
	The visible small intestine demonstrates areas of thick muscularis layer relative to mucosa (disruption of the normal 1:3 muscularis:mucosa ratio). Small intestinal submucosa is slightly irregular, thick and



<b>PATIENT</b>	hyperechoic, without evident loss of layering appreciated. The lumen is empty with no evidence of obstruction or foreign material.
Georgina Vieira	
<b>SPECIES</b>	The visible colon is normal in wall thickness (< 0.2 cm) and layering. Contents are consistent with normal formed feces and gas.
Feline	<b>Pancreas</b>
<b>BREED</b>	The pancreatic parenchyma is appropriately isoechoic to surrounding tissue. Visible capsule is smooth and normal in contour. There is no visible pancreatic duct dilation. There is no evidence of active peripancreatic inflammation.
DSH	
<b>SEX</b>	<b>Free Abdomen</b>
Spayed Female	There is no evidence of free peritoneal effusion noted in these images.
<b>AGE</b>	There is no apparent lymphadenopathy noted in these images.
18 Years	
<b>WEIGHT</b>	
2.85 kg	
<b>INTERPRETED BY</b>	
Beth Johnson, DVM DACVIM	
<b>IMAGING PERFORMED BY</b>	
Kelly Reschny	
<b>HOSPITAL NAME</b>	
Windrush VS	
<b>REFERRING VET</b>	
Dr. McGrath	
<b>INVOICE</b>	
46260	
<b>DATE</b>	
3/29/23	

#### PRIMARY FINDINGS

- **Hypoechoic hepatomegaly with multifocal intrahepatic biliary mineral** – This appearance is consistent with an acute hepatopathy or acute cholangiohepatitis. Infiltrative neoplasia (round cell neoplasia) should also be considered.
- **Inflammatory bowel disease (IBD) pattern** – Thick muscularis has been reported with infiltrative bowel disease including both benign inflammatory disease as well as infiltrative neoplasia such as lymphoma. No aggressive lymphadenopathy, loss of layering, etc. is noted to make lymphoma more probable, but lymphoma cannot be definitively ruled out without tissue sampling.
- **Coarse splenomegaly** – can be associated with congestion caused by sedation (if sedated) but can also be associated with diffuse infiltrative disease. Both benign conditions such as extramedullary hematopoiesis, lymphoid hyperplasia, amyloidosis, as well as infiltrative neoplastic diseases such as round cell neoplasia should be considered.

#### ULTRASONOGRAPHIC FINDINGS

- Age related kidney changes with a small non-obstructive nephrolith in the right kidney

#### INTERPRETATION OF THE FINDINGS & FURTHER RECOMMENDATIONS

Given this patient's reported inappetence and hyperbilirubinemia with mild improvement so far, treatment recommendations include fluid therapy, anti-emetics, gastroprotectants, hepatic nutraceuticals such as ursodiol and/or Denamarin, and broad spectrum antibiotics. Nutritional support is critical to prevent/manage concurrent hepatic lipidosis, so appetite stimulants and/or, if indicated, feeding tube placement is also recommended.

Pending response to therapy, etc., additional considerations, given the bowel changes reported above, include a gastrointestinal malabsorption panel (including cobalamin, folate, TLI and PLI) to Texas A&M GI Laboratory is recommended for further evaluation of GI and pancreatic function.

Ideally, biopsies of the GI tract, being sure to include ileum, if possible, are recommended to definitively diagnose and therefore manage the infiltrative bowel disease. Or alternatively, prior to pursuing biopsies, fine needle aspirates of both the spleen and liver could be considered if patient's coagulation status is appropriate to look for evidence of infiltrative round cell neoplasia prior to more invasive biopsies.



**PATIENT**

Georgina Vieira

**SPECIES**

Feline

**BREED**

DSH

**SEX**

Spayed Female

**AGE**

18 Years

**WEIGHT**

2.85 kg

**INTERPRETED BY**

Beth Johnson, DVM  
DACVIM

**IMAGING PERFORMED BY**

Kelly Reschny

**HOSPITAL NAME**

Windrush VS

**REFERRING VET**

Dr. McGrath

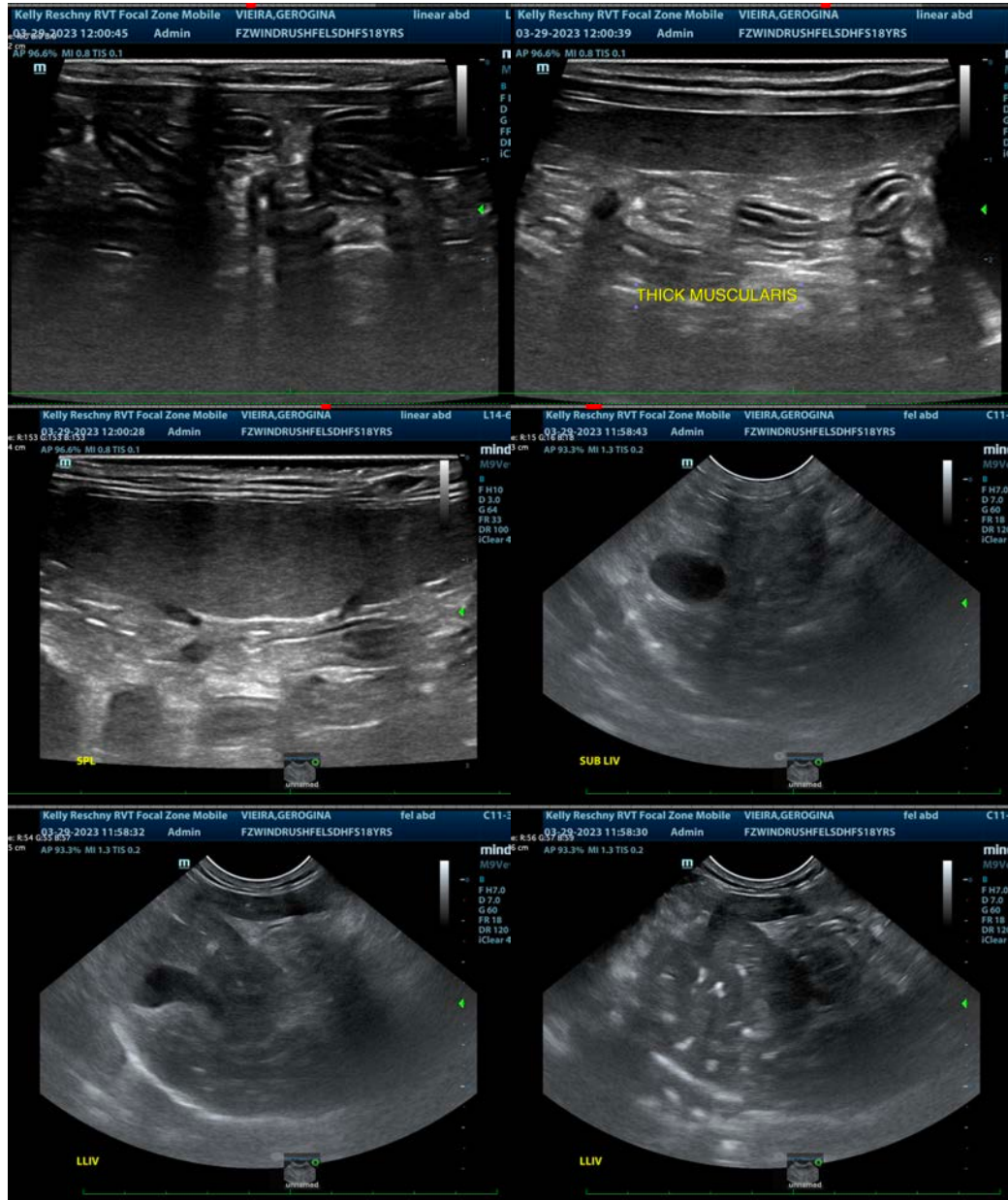
**INVOICE**

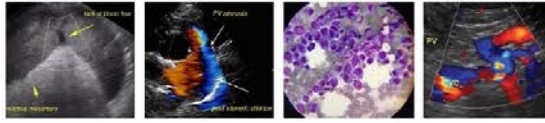
46260

**DATE**

3/29/23

If tissue sampling cannot be obtained, empirical therapies could include diet change, empirical deworming with a 5 day course of Panacur, cobalamin supplementation (unless cobalamin level is evaluated and supplementation is not warranted) and prednisolone (if not contraindicated based on patient contraindications, co-morbidities, etc.). Other supportive therapeutic considerations could include fiber supplementation, especially with large bowel diarrhea and/or a probiotic.





**PATIENT**

Georgina Vieira

**SPECIES**

Feline

**BREED**

DSH

**SEX**

Spayed Female

**AGE**

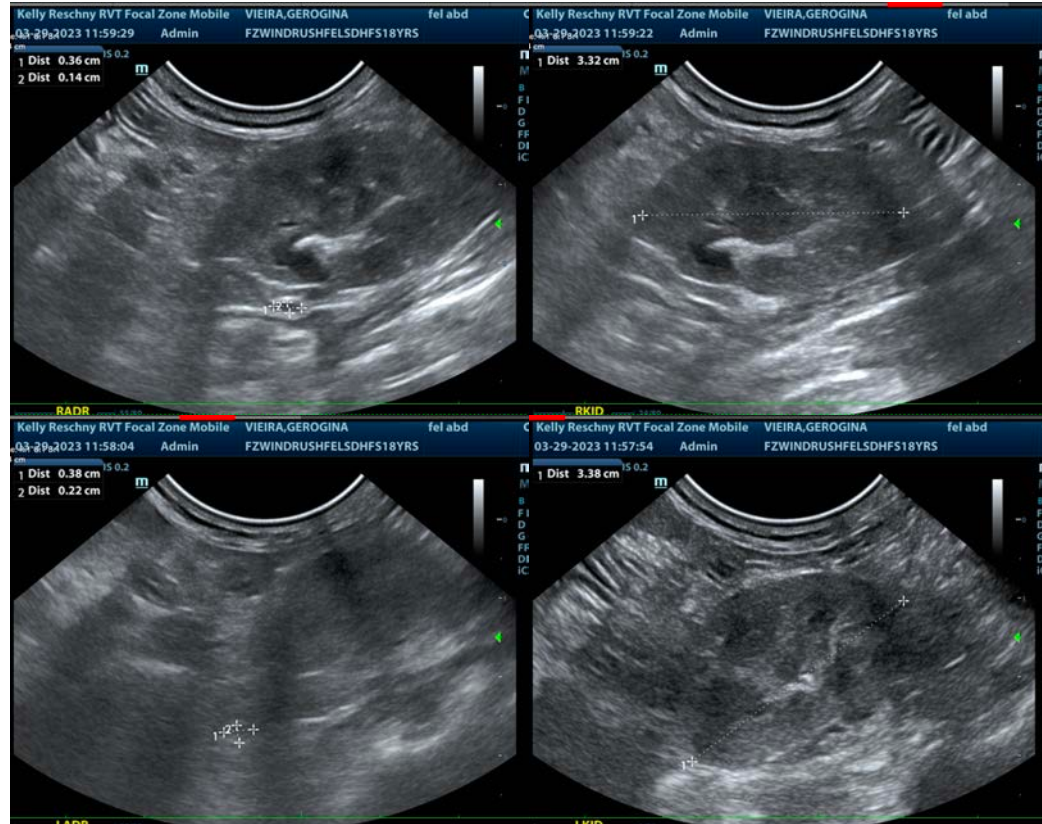
18 Years

**WEIGHT**

2.85 kg

**INTERPRETED BY**

Beth Johnson, DVM  
DACVIM



**IMAGING PERFORMED BY**

Kelly Reschny

**HOSPITAL NAME**

Windrush VS

**REFERRING VET**

Dr. McGrath

**INVOICE**

46260

**DATE**

3/29/23

The information and recommendations provided are based on the images presented by the referring veterinarian/sonographer. No evaluation can be communicated regarding pathology that was not visible in the image/video clips provided.

Thank you for this referral. If the clinical or image interpretation does not parallel your findings or if I can be of any further assistance please contact me.

**Beth Johnson, DVM, DACVIM**  
Beth.Johnson@sonopath.com