



PATIENT PRESENTING CLINICAL SIGNS

Niche Racz Niche presented for AUS as part of recommended routine evaluation after successful rectal adenocarcinoma removal and adjunctive therapy (2020-2021). He is doing well at home with no current clinical signs of significance noted

SPECIES

Canine Abnormal PE/Chem/CBC/UA Results: Labs performed in office today were within normal limits

BREED ULTRASONOGRAPHIC EXAMINATION OF THE ABDOMEN

Border Collie *Urinary System*

SEX

Neutered Male The urinary bladder is moderately distended with anechoic contents. No masses, inflammatory changes, echogenic sediment or cystoliths are observed. The urinary bladder, trigone and visible pelvic urethra are normal in thickness with a smooth mucosal surface.

AGE

11 Prostate is normal in size, echotexture and echogenicity for a neutered male.

WEIGHT

54 The right kidney is normal in size (6.2 cm), shape and echogenicity. It has smooth peripheral margination. There is a normal 1:3 cortex to medulla ratio with appropriate corticomedullary distinction. There is no evidence of pyelectasia, mineral or infarcts observed.

INTERPRETED BY

Beth Johnson, DVM
DACVIM

Adrenal Glands

The adrenal glands are unable to be well visualized in these images.

Spleen

The spleen is subjectively normal in size with a normal smooth capsular contour. Parenchyma is appropriately finely textured and homogenous with normal echogenicity relative to surrounding tissue (hyperechoic to liver). No focal nodules or masses are observed. Splenic vasculature appears normal.

IMAGING PERFORMED BY

Dr. James Hornbuckle

Liver

HOSPITAL NAME

Golden Isles AH

The liver is subjectively normal in size with normal smooth curvilinear peripheral contour. Parenchyma is appropriately hypoechoic to the spleen in echogenicity and appropriately mildly coarse and homogenous in echotexture. No focal lesions are observed. Visible vasculature and biliary tree appear normal without distension or congestion.

REFERRING VET

Dr. James Hornbuckle

The gallbladder is non-distended in size. The wall is smooth without visible thickening. Luminal contents are primarily anechoic. There is no evidence of cystic or common bile duct dilation.

INVOICE

46222

DATE

3/28/23

Gastrointestinal

The visible stomach wall is normal in thickness and layering. The lumen of the stomach is mildly distended with echogenic non-shadowing luminal contents and gas consistent with normal ingesta. There is no evidence of obstruction, foreign material or infiltrative disease. Pyloric outflow tract appears patent.

The visible small intestines are normal in wall thickness and layering (canine duodenum < 0.5 cm and feline duodenum < 0.4 cm; other < 0.3 cm). Small intestinal motility appears adequate (1-3 contractions per min). The lumen of the small intestine is empty with no evidence of obstruction, foreign material or infiltrative disease.



PATIENT

Niche Racz

The visible colon is normal in wall thickness (< 0.2 cm) and layering. Contents are consistent with normal formed feces and gas.

SPECIES

Canine

Pancreas

The pancreatic parenchyma is appropriately isoechoic to surrounding tissue. Visible capsule is smooth and normal in contour. There is no visible pancreatic duct dilation. There is no evidence of active peripancreatic inflammation.

BREED

Border Collie

Free Abdomen

There is no evidence of free peritoneal effusion noted in these images.

SEX

Neutered Male

There is no apparent lymphadenopathy noted in these images.

AGE

11

ULTRASONOGRAPHIC FINDINGS

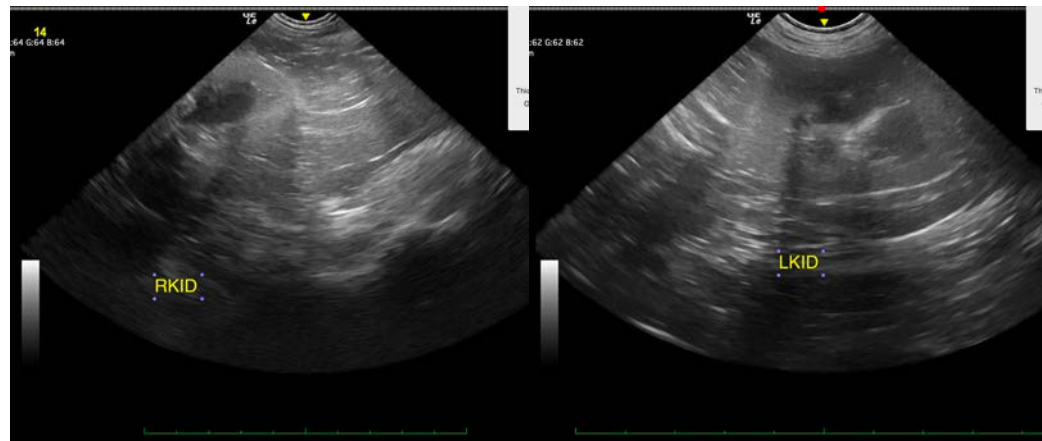
- Relatively unremarkable/normal abdomen without any intraabdominal evidence of metastatic disease in these images.

INTERPRETATION OF THE FINDINGS & FURTHER RECOMMENDATIONS

Recommendations are to consider therapy and monitoring as recommended by a veterinary oncologist.

INTERPRETED BY

Beth Johnson, DVM
DACVIM



IMAGING PERFORMED BY

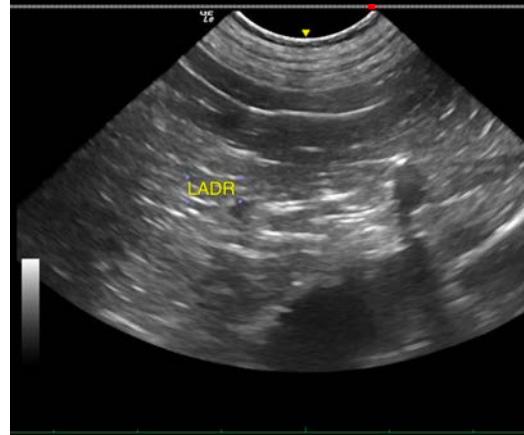
Dr. James Hornbuckle

HOSPITAL NAME

Golden Isles AH

REFERRING VET

Dr. James Hornbuckle



INVOICE

46222

DATE

3/28/23



PATIENT

Niche Racz

The information and recommendations provided are based on the images presented by the referring veterinarian/sonographer. No evaluation can be communicated regarding pathology that was not visible in the image/video clips provided.

SPECIES

Canine

Thank you for this referral. If the clinical or image interpretation does not parallel your findings or if I can be of any further assistance please contact me.

BREED

Border Collie

Beth Johnson, DVM, DACVIM
Beth.Johnson@sonopath.com

SEX

Neutered Male

AGE

11

WEIGHT

54

INTERPRETED BY

Beth Johnson, DVM
DACVIM

**IMAGING
PERFORMED BY**

Dr. James Hornbuckle

HOSPITAL NAME

Golden Isles AH

REFERRING VET

Dr. James Hornbuckle

INVOICE

46222

DATE

3/28/23