



**PATIENT**

Coco Loomis

**SPECIES**

Canine

**BREED**

Lab X

**SEX**

Spayed Female

**AGE**

12

**WEIGHT**

41.8

**INTERPRETED BY**

Beth Johnson, DVM  
DACVIM

**IMAGING PERFORMED BY**

Dr. Danielle Lanz

**HOSPITAL NAME**

New Holland VH

**REFERRING VET**

Dr. Danielle Lanz

**INVOICE**

46215

**DATE**

3/28/23

**PRESENTING CLINICAL SIGNS**

PU/PD, normal appetite, no diarrhea, vomiting, or weight loss reported. Currently on telmisartan and chitosan (started in February). Denamarin started 3/23 No improvement with triglycerides and has consistently elevating liver values. Improvement with UPC since starting telmisartan in February.

Abnormal PE/Chem/CBC/UA Results: 10mm multilobulated mass on upper eyelid - attempting to clear for surgical removal. Multiple soft, mobile subcutaneous masses throughout trunk. 3/23/23 CBC: WNL Chem: SDMA 17 Na 135, P 5.9, Na/K ratio 23, Chloride 99, Albumin 2.5, Globulin 4.1, Alb/Globulin 0.6, ALT 679, AST 61, ALP 782, GGT 31, Cholesterol 1891 T4 <0.4 (fasting sample) UA UPC 2.6 USG 1.012 2/21/23 CBC WNL Chem: Na 139, K 5.9 Na/K 24 Chloride 100 Alb 2.6 ALP 242 Cholesterol 1520, Triglycerides 1972 (fasting sample) UA: UPC 6.2, USG 1.008 4dx: negative ACTH stim: Pre 2.4, Post 21.3 1/14/23 UA UPC 6.0, occasional rods present CBC: Neutrophils 2.712 PLT 591 Chem: Na 141, K 5.6, Na/K 25 Chloride 100 ALP 164, Conj Bili 0.2, Cholesterol 1228, Triglycerides 4171 (not a fasted sample) T4 0.7

**ULTRASONOGRAPHIC EXAMINATION OF THE ABDOMEN**

**Urinary System**

The urinary bladder is moderately distended with anechoic contents. No masses, inflammatory changes, echogenic sediment or cystoliths are observed. The urinary bladder, trigone and visible pelvic urethra are normal in thickness with a smooth mucosal surface.

The right kidney is normal in size (5.1 cm), shape and echogenicity. It has smooth peripheral margination. There is a normal 1:3 cortex to medulla ratio with appropriate corticomedullary distinction. There is no evidence of pyelectasia, mineral or infarcts observed.

The left kidney is normal in size (5.35 cm), shape and echogenicity. It has smooth peripheral margination. There is a normal 1:3 cortex to medulla ratio with appropriate corticomedullary distinction. There is no evidence of pyelectasia, mineral or infarcts observed.

**Adrenal Glands**

Adrenal glands are plump/swollen in size. Normal shape and contour are maintained without evidence of capsular invasion. Corticomedullary structure is unremarkable. Visible surrounding vasculature appears normal. The cranial pole of the left is unable to be well visualized, but the caudal pole measures 0.96 cm. The right adrenal gland measures 1.6 cm at the cranial pole and 0.94 cm at the caudal pole.

**Spleen**

Spleen is subjectively normal in size with a normal smooth capsular contour. Parenchyma is appropriately finely textured and homogenous with normal echogenicity relative to surrounding tissue (hyperechoic to liver). Multifocal well-demarcated hyperechoic homogenous nodules are noted. Splenic vasculature appears normal.

**Liver**

Liver is subjectively enlarged with mildly irregular margins. Parenchyma is heterogenous characterized by multiple poorly defined hypoechoic nodules within otherwise hyperechoic liver parenchyma. Visible vasculature and biliary tree appear normal without distension or congestion.

Gallbladder is moderately distended with anechoic bile as well as mild suspended and gravity dependent echogenic debris. The wall is smooth without visible thickening. There is no evidence of cystic or CBD dilation. There is no evidence of effusion or inflammation.



**PATIENT**

Coco Loomis

**SPECIES**

Canine

**BREED**

Lab X

**SEX**

Spayed Female

**AGE**

12

**WEIGHT**

41.8

**INTERPRETED BY**

Beth Johnson, DVM  
DACVIM

**IMAGING PERFORMED BY**

Dr. Danielle Lanz

**HOSPITAL NAME**

New Holland VH

**REFERRING VET**

Dr. Danielle Lanz

**INVOICE**

46215

**DATE**

3/28/23

**Gastrointestinal**

The stomach wall is normal in thickness (canine < 0.5 cm and feline < 0.4 cm) and layering. The lumen of the stomach is mildly fluid distended with no evidence of obstruction, foreign material or infiltrative disease. Pyloric outflow tract appears patent.

The visible small intestines are normal in wall thickness and layering (canine duodenum < 0.5 cm and feline duodenum < 0.4 cm; other < 0.3 cm). Small intestinal motility appears adequate (1-3 contractions per min). The lumen of the small intestine is empty with no evidence of obstruction, foreign material or infiltrative disease.

The visible colon is normal in wall thickness (< 0.2 cm) and layering. Contents are consistent with normal formed feces and gas.

**Pancreas**

The pancreatic parenchyma is appropriately isoechoic to surrounding tissue. Visible capsule is smooth and normal in contour. There is no visible pancreatic duct dilation. There is no evidence of active peripancreatic inflammation.

**Free Abdomen**

There is no evidence of free peritoneal effusion noted in these images.

There is no apparent lymphadenopathy noted in these images.

**PRIMARY FINDINGS**

- **Bilateral adrenomegaly** – consistent with adrenal hyperplasia secondary to pituitary dependent hyperadrenocorticism vs stress or normal variant. Interpret in combination with clinical signs of hyperadrenocorticism.
- **Heterogenous Liver** – These changes are most consistent with benign processes such as nodular hyperplasia, steroid (vacuolar) hepatopathy, extramedullary hematopoiesis or possibly chronic inflammatory disease and less commonly infiltrative round cell or metastatic neoplasia.
- **Mild gallbladder debris** - Cholecystic debris is of unknown clinical significance. It can be seen with biliary stasis from fasting or illness. Cholecystic debris is not necessarily related to hepatobiliary disease. Echogenic bile is most commonly an incidental finding in dogs and should be interpreted in combination with clinical signs such as nausea, inappetence, cranial abdominal discomfort and/or laboratory changes such as increased ALP and/or increased Tbili.

**SECONDARY FINDINGS**

- **Hyperechoic splenic nodules** – most consistent with benign myelolipomas. Other differentials such as fibrosis or calcification caused by old hematomas or infarcts, chronic inflammation, granulomatous disease or metastatic disease cannot be ruled out, but are considered less likely.

**INTERPRETATION OF THE FINDINGS & FURTHER RECOMMENDATIONS**

This patient's adrenal gland, liver, gallbladder, etc. changes combined with PU/PD is all concerning hyperadrenocorticism, which could be further investigated, following a reportedly normal ACTH stim, with a more sensitive low-dose Dexamethasone suppression test. However, given this patient's progressive hypoalbuminemia despite and improving UPC, other underlying conditions are considered likely and potentially more serious, and should be evaluated prior to further pursuing hyperadrenocorticism.



**PATIENT**

Coco Loomis

Bile acids could be considered, as could a gastrointestinal malabsorption panel (including cobalamin, folate, TLI and PLI) to Texas A&M GI Laboratory to further evaluate another source of the hypoalbuminemia. Additionally, testing for Leptospirosis is recommended.

**SPECIES**

Canine

Additionally, given the hepatocellular injury pattern versus cholestatic pattern, which is less typical with hyperadrenocorticism, liver sampling, beginning with a fine needle aspirate if the patient's coagulation status is appropriate, is also recommended.

**BREED**

Lab X

A blood pressure is also recommended if not recently evaluated.

**SEX**

Spayed Female

Following that workup, if another underlying cause for the PU/PD is not found, and clinical signs persist, at that point is when a low-dose Dexamethasone suppression test should be considered, as false positive results are likely in the face of concurrent disease.

**AGE**

12

**WEIGHT**

41.8

**INTERPRETED BY**

Beth Johnson, DVM  
DACVIM

**IMAGING PERFORMED BY**

Dr. Danielle Lanz

**HOSPITAL NAME**

New Holland VH

**REFERRING VET**

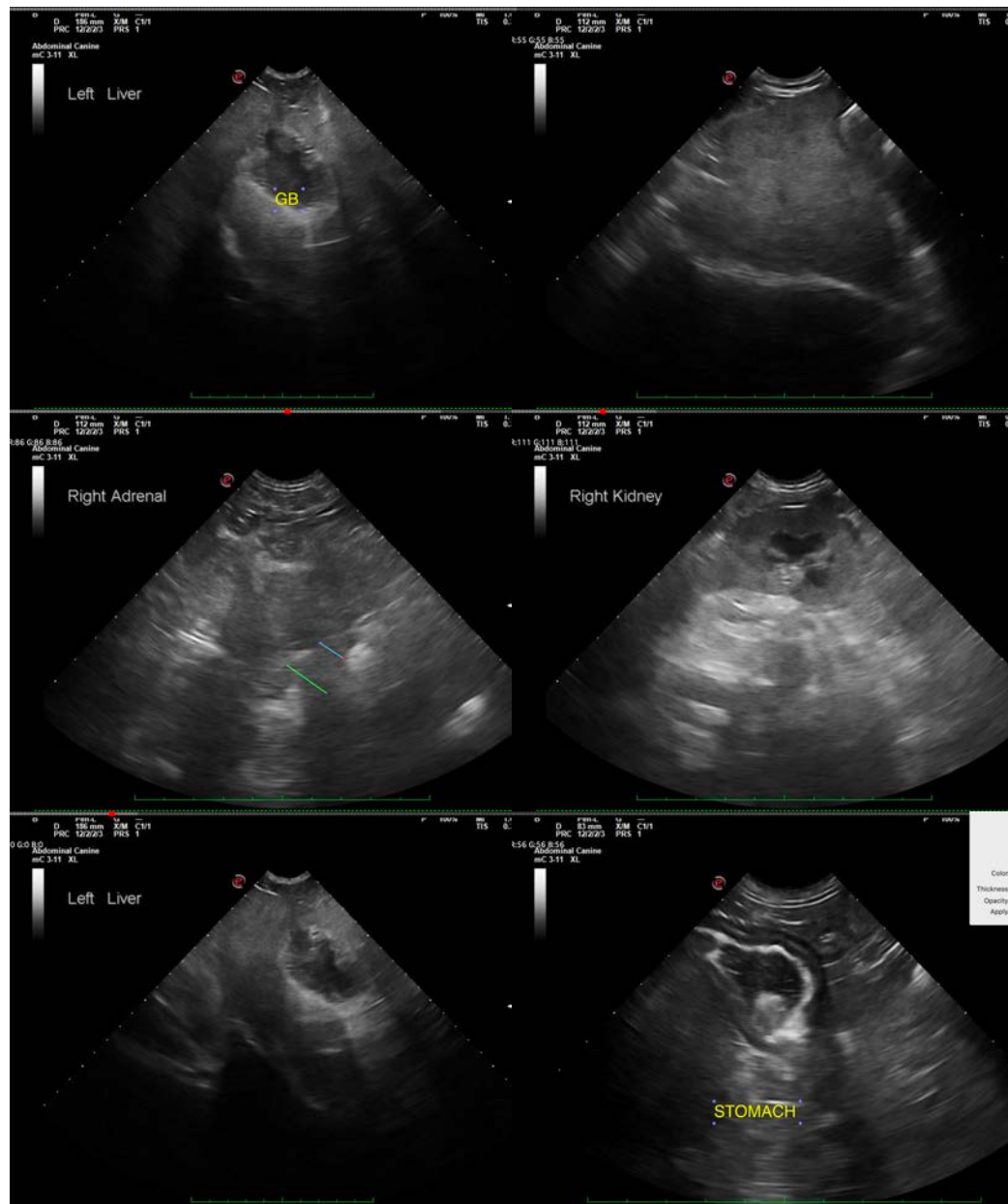Dr. Danielle Lanz

**INVOICE**

46215

**DATE**

3/28/23





**PATIENT**

Coco Loomis

**SPECIES**

Canine

**BREED**

Lab X

**SEX**

Spayed Female

**AGE**

12

**WEIGHT**

41.8

**INTERPRETED BY**

Beth Johnson, DVM  
DACVIM

**IMAGING PERFORMED BY**

Dr. Danielle Lanz

**HOSPITAL NAME**

New Holland VH

**REFERRING VET**

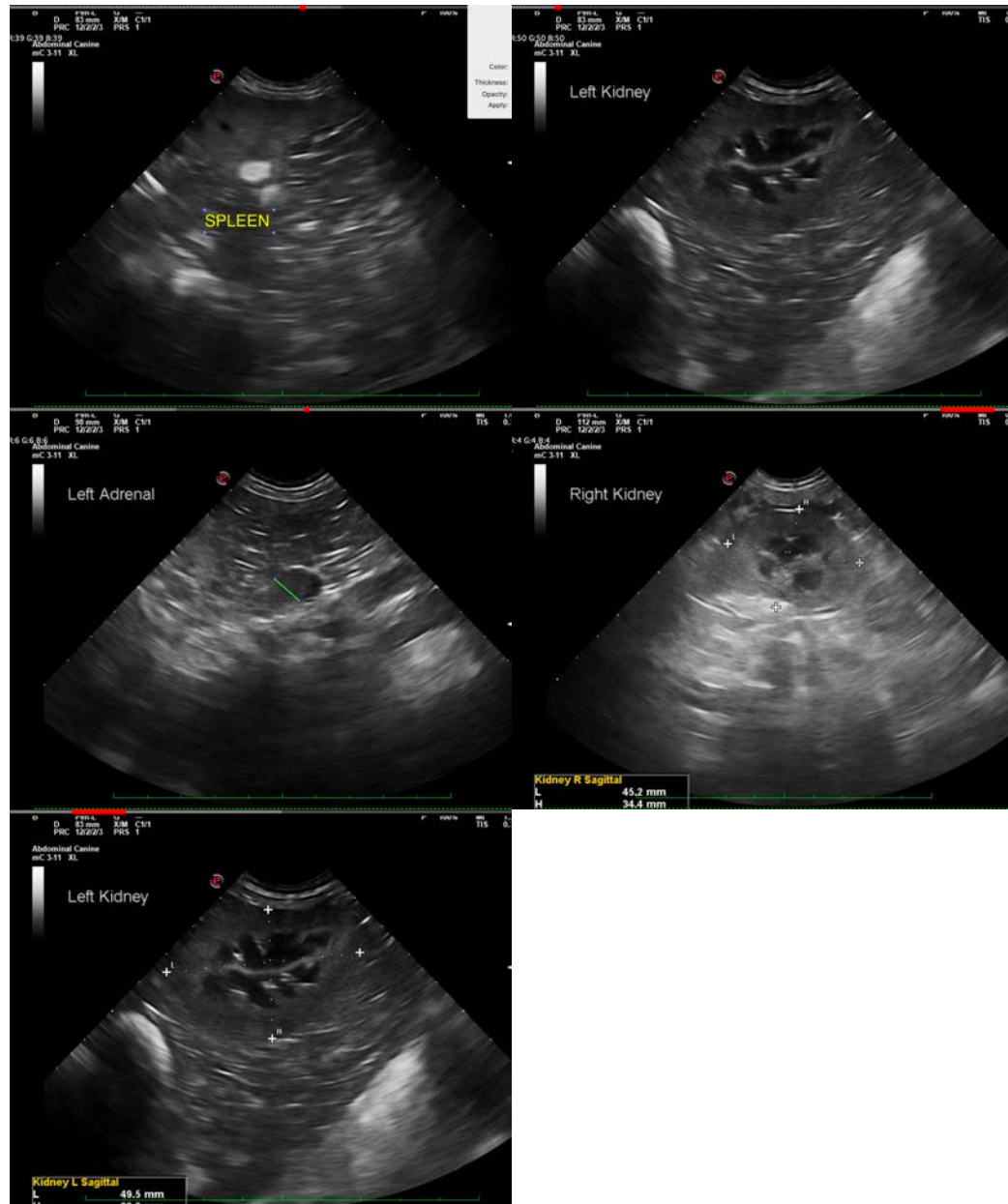
Dr. Danielle Lanz

**INVOICE**

46215

**DATE**

3/28/23



The information and recommendations provided are based on the images presented by the referring veterinarian/sonographer. No evaluation can be communicated regarding pathology that was not visible in the image/video clips provided.

Thank you for this referral. If the clinical or image interpretation does not parallel your findings or if I can be of any further assistance please contact me.

**Beth Johnson, DVM, DACVIM**  
Beth.Johnson@sonopath.com