



PATIENT

Colt Daniels

SPECIES

Canine

BREED

Lab x

SEX

Neutered Male

AGE

10 Years 4 Months

WEIGHT

62

INTERPRETED BY

Beth Johnson, DVM
DACVIM

IMAGING PERFORMED BY

Jessica Green

HOSPITAL NAME

Stanglein Veterinary
Clinic

REFERRING VET

Dr. Katrina lobst

INVOICE

74013

DATE

3/25/26

PRESENTING CLINICAL SIGNS

10yo MN Lab Mix with acute ITP dx 3/3/26 - caudal abdominal ecchymoses, CBC PLT 4, confirmed <50K/uL PLT with in-house blood morphology. No response to Prednisone x 1 week. Positive response to single dose Vincristine given 3/17/26. PLT normalized to 266 on 3/24/26 CBC.

Previous history includes GB debris (identified on AUS 8/18/25) & PU/PD with dilute urine (open etiology: atypical cushings vs diabetes insipidus vs other).

Abnormal PE/Chem/CBC/UA Results: 3/3/26 CBC: HCT 62.2 (H; N = 37.3-61.7), Retics 82.6 (N = 10-110); WBCs all low-normal; Plt 4 (L; N = 148-484). Blood morph confirmed Plt <50K/uL (markedly decreased), no agglutination or spherocytes. 3/3/26 Chem: Amy 474 (L; N = 500-1500), all other values WNL 3/4/26 Tick/Vector Comprehensive RealPCR: NEGATIVE 3/14/26 CBC: HCT normalized, Plt 0. Blood smear confirmed inadequate Plt estimate. Neuts 13.27 (N = 2.95-11.64), evidence of toxic change. 3/24/26 CBC: Plt 266, MPV 14.5 (H; N = 8.7-13.2), otherwise WNL. RADS: Mild generalized bronchial pulmonary pattern in the caudodorsal lung fields, no nodules or suspected neoplastic lesions. Subjectively rounded hepatic lobe margins +/- irregular hepatic contour, +/- splenomegaly vs superimposed subcutaneous mass.

ULTRASONOGRAPHIC EXAMINATION OF THE ABDOMEN

Urinary System

Urinary bladder is adequately distended with primarily anechoic contents and occasional echogenic non-shadowing debris. Apical urinary bladder wall is diffusely thick (X cm). Mucosa is hyperechoic and irregular. No masses or calculi are observed. The trigone and visible pelvic urethra are normal thickness with a smooth mucosal surface.

The prostate is unable to be well visualized in these images.

The right kidney is normal is size (7.07 cm), shape and echogenicity. It has smooth peripheral margination. There is a normal 1:3 cortex to medulla ratio with appropriate corticomedullary distinction. There is no evidence of pyelectasia, mineral or infarcts observed.

The left kidney is normal is size (7.17 cm), shape and echogenicity. It has smooth peripheral margination. There is a normal 1:3 cortex to medulla ratio with appropriate corticomedullary distinction. There is no evidence of pyelectasia, mineral or infarcts observed.

Adrenal Glands

The right adrenal gland is unable to be well visualized in these images.

The left adrenal gland is small (flattened contour), measuring 0.36 cm at the cranial pole and 0.35 cm at the caudal pole. Corticomedullary structure is unremarkable. Visible surrounding vasculature appears normal.

Spleen

Spleen is subjectively large in size (2.0 cm thick at the hilus) with normal smooth margins. Parenchyma is normal in echogenicity with a diffusely coarse/heterogenous echotexture. Specifically, there is an approximately 0.70 cm x 0.90 cm non-capsule disrupting hypo- to anechoic density near the medial mid aspect of the spleen. Splenic vasculature appears normal.



PATIENT

Colt Daniels

SPECIES

Canine

BREED

Lab x

SEX

Neutered Male

AGE

10 Years 4 Months

WEIGHT

62

INTERPRETED BY

Beth Johnson, DVM
DACVIM

IMAGING PERFORMED BY

Jessica Green

HOSPITAL NAME

Stanglein Veterinary
Clinic

REFERRING VET

Dr. Katrina lobst

INVOICE

74013

DATE

3/25/26

Liver

Liver is subjectively enlarged with mildly irregular margins. Parenchyma is moderately heterogenous characterized by multiple poorly defined hypoechoic nodules within otherwise hyperechoic liver parenchyma. Visible vasculature and biliary tree appear normal without distension or congestion.

Gallbladder is moderately distended with anechoic bile as well as suspended and gravity dependent echogenic debris. The wall is smooth without visible thickening. There is no evidence of cystic or CBD dilation. There is no evidence of effusion or inflammation.

Gastrointestinal

The visible stomach wall is normal in thickness and layering. The stomach is moderately distended with echogenic non-shadowing luminal contents and gas consistent with normal ingesta. There is no evidence of obstruction, foreign material or infiltrative disease. If patient was appropriately fasted, delayed gastric emptying could be considered. Non-shadowing foreign material is considered less likely but cannot be definitively ruled out.

If clinical signs are consistent (vomiting, etc.), recommendations include supportive medical care, 24 hours fasting and re-image.

The visible small intestines are normal in wall thickness and layering. Small intestinal motility appears adequate (1-3 contractions per min). The lumen is mildly distended with echogenic non-shadowing luminal contents and gas consistent with normal ingesta/chyme. There is no evidence of obstruction, foreign material or infiltrative disease.

The visible colon is normal in wall thickness (< 0.2 cm) and layering. Contents are consistent with normal formed feces and gas.

Pancreas

The pancreas that is observed appears appropriately isoechoic to surrounding omental fat. Visible capsule is smooth and normal in contour. Visible pancreatic parenchyma is homogenous and unremarkable. There is no visible pancreatic duct dilation. There is no evidence of active peripancreatic inflammation.

Free Abdomen

There is no visible free peritoneal effusion noted in these images.

There is no apparent pathologic lymphadenopathy noted in these images.

PRIMARY FINDINGS

- Coarse splenomegaly – can be associated with congestion caused by sedation (if sedated) but can also be associated with diffuse infiltrative disease. Both benign conditions such as extramedullary hematopoiesis, lymphoid hyperplasia, as well as infiltrative neoplastic diseases such as round cell neoplasia should be considered.
- One hypo to anechoic splenic nodule – likely represents a benign lesion such as a cyst, hematoma, nodular hyperplasia, extramedullary hematopoiesis, etc., however while considered less likely, infiltrative neoplasia can mimic benign lesions, and cannot be ruled out.



PATIENT

Colt Daniels

SPECIES

Canine

BREED

Lab x

SEX

Neutered Male

AGE

10 Years 4 Months

WEIGHT

62

INTERPRETED BY

Beth Johnson, DVM
DACVIM

IMAGING PERFORMED BY

Jessica Green

HOSPITAL NAME

Stanglein Veterinary
Clinic

REFERRING VET

Dr. Katrina lobst

INVOICE

74013

DATE

3/25/26

- Moderately heterogenous liver – These changes are most consistent with benign processes such as nodular hyperplasia, steroid (vacuolar) hepatopathy, extramedullary hematopoiesis or possibly chronic inflammatory disease and less commonly infiltrative round cell or metastatic neoplasia.

- Moderate gallbladder debris - Cholecystic debris is of unknown clinical significance. It can be seen with biliary stasis from fasting or illness. Cholecystic debris is not necessarily related to hepatobiliary disease. Echogenic bile is most commonly an incidental finding in dogs and should be interpreted in combination with clinical signs such as nausea, inappetence, cranial abdominal discomfort and/or laboratory changes such as increased ALP and/or increased Tbili.

SECONDARY FINDINGS

- Mild chronic cystitis - Urinary bladder wall changes are most consistent with chronic cystitis. Infiltrative neoplasia cannot be ruled out but is considered less likely give the location and diffuse nature of the changes.
- The subjectively flat adrenal glands are consistent with patient's steroid history.

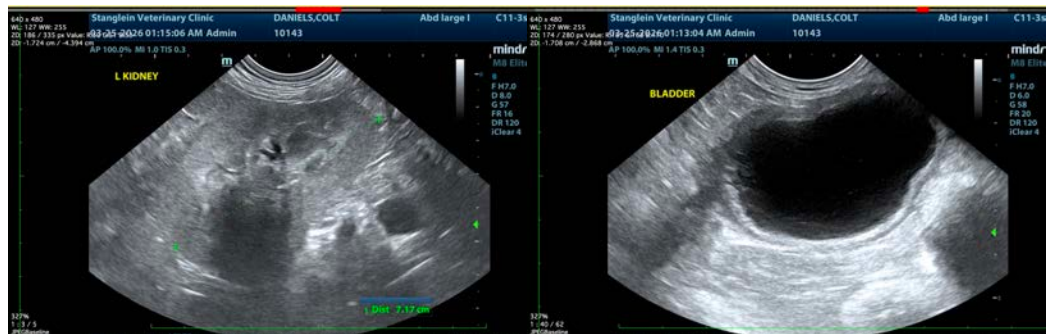
INTERPRETATION OF THE FINDINGS & FURTHER RECOMMENDATIONS

If not recently evaluated, a urinalysis and, if indicated based on urinalysis results, urine culture is recommended. If protein is present in an otherwise quiet sediment, protein quantification with a urine protein to creatinine ratio is recommended.

If/when patient's coagulation status is appropriate, fine needle aspirates of the spleen +/- liver could be considered. Having said that, the changes throughout this abdomen largely trend toward benign, especially in a patient receiving steroids, etc.

Beyond that, if a comprehensive visual evaluation for neoplasia has been unremarkable, and comprehensive infectious disease evaluation is negative, next diagnostics steps to consider include bone marrow sampling.

Other than supportive/symptomatic medical management of clinical signs, further treatment recommendations are largely dependent on results of the above.





PATIENT

Colt Daniels

SPECIES

Canine

BREED

Lab x

SEX

Neutered Male

AGE

10 Years 4 Months

WEIGHT

62

INTERPRETED BY

Beth Johnson, DVM
DACVIM

IMAGING PERFORMED BY

Jessica Green

HOSPITAL NAME

Stanglein Veterinary
Clinic

REFERRING VET

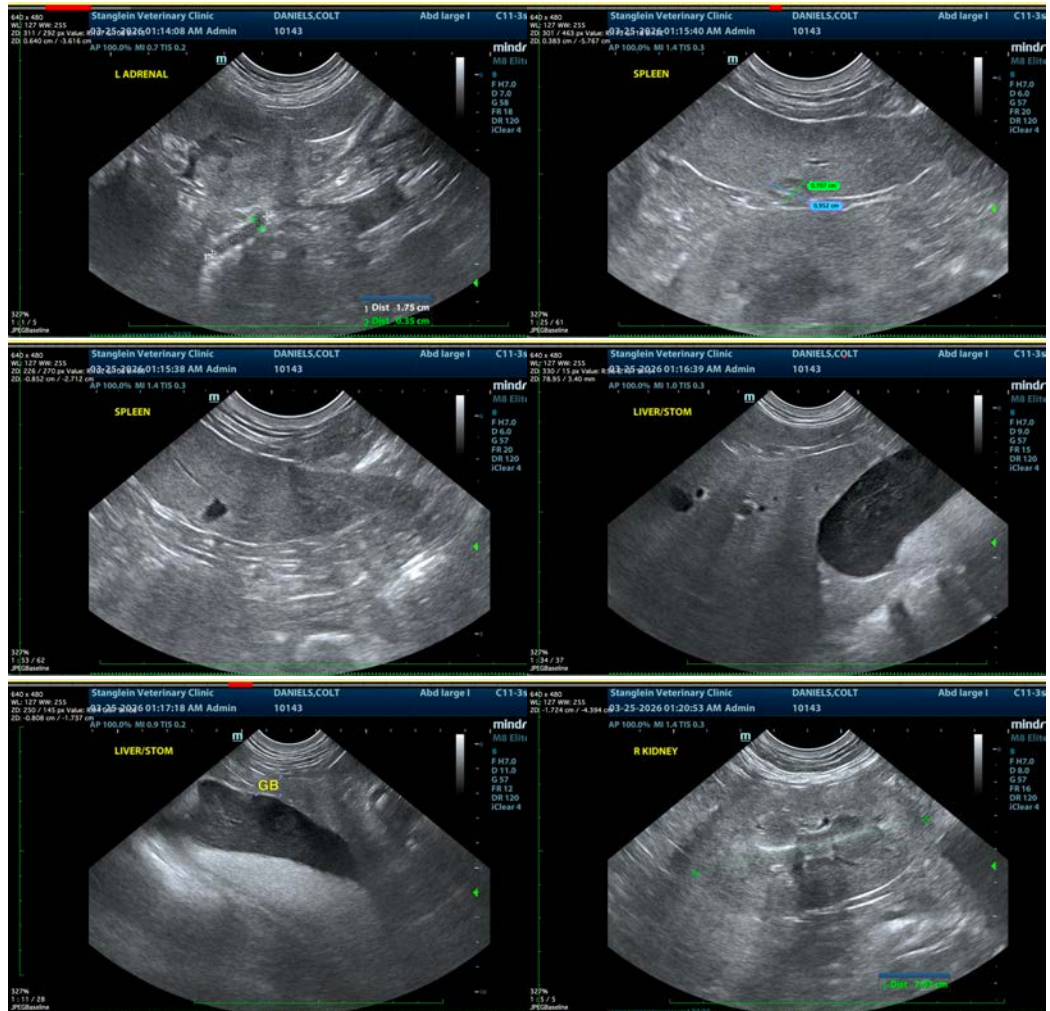
Dr. Katrina lobst

INVOICE

74013

DATE

3/25/26



The information and recommendations provided are based on the images presented by the referring veterinarian/sonographer. No evaluation can be communicated regarding pathology that was not visible in the image/video clips provided.

Thank you for this referral. If the clinical or image interpretation does not parallel your findings or if I can be of any further assistance please contact me.

Beth Johnson, DVM, DACVIM
info@sonopath.com