



PATIENT

Misty Kropf

SPECIES

Feline

BREED

DSH

SEX

Spayed Female

AGE

11 Years 11 Months

WEIGHT

15

INTERPRETED BY

Beth Johnson, DVM
DACVIM

IMAGING PERFORMED BY

Jessica Green

HOSPITAL NAME

Stanglein Veterinary
Clinic

REFERRING VET

Dr. Erin Rothrock

INVOICE

73964

DATE

3/24/26

PRESENTING CLINICAL SIGNS

Approx 3 week history of decreased appetite and weight loss. Patient has lost 1.5 lbs in 3 weeks. Physical exam fairly unremarkable but patient does seem slightly dull today

Abnormal PE/Chem/CBC/UA Results: BW Unremarkable RADS: Fairly significant thickening of gastric lining, concern for foreign material within stomach lumen vs tumor of the stomach

ULTRASONOGRAPHIC EXAMINATION OF THE ABDOMEN

Urinary System

Urinary bladder is only mildly distended (empty). Visible contents are anechoic. Urinary bladder wall is unable to be fully assessed for pathology without further distension. No visible masses or definitive cystoliths are observed. The trigone and visible pelvic urethra are normal thickness with a smooth mucosal surface. In the face of urinary signs and/or suspected urinary bladder pathology, reassessment after complete filling is recommended.

The right kidney is normal is size (4.35 cm), shape and echogenicity. It has smooth peripheral margination. There is a normal 1:3 cortex to medulla ratio with appropriate corticomedullary distinction. There is no evidence of pyelectasia, mineral or infarcts observed.

The left kidney is normal is size (3.91 cm), shape and echogenicity. It has smooth peripheral margination. There is a normal 1:3 cortex to medulla ratio with appropriate corticomedullary distinction. There is no evidence of pyelectasia, mineral or infarcts observed.

Adrenal Glands

The right adrenal gland is normal in size (0.25 cm), shape and overall architecture, echogenicity and echotexture. Visible surrounding vasculature appears normal.

The left adrenal gland is normal in size (0.30 cm), shape and overall architecture, echogenicity and echotexture. Visible surrounding vasculature appears normal.

Spleen

The spleen is subjectively normal in size with a normal smooth capsular contour. Parenchyma is appropriately finely textured and homogenous with normal echogenicity relative to surrounding tissue (hyperechoic to liver). No focal nodules or masses are observed. Splenic vasculature appears normal.

Liver

Liver is subjectively enlarged (swollen contour) without disruption of architecture. It has a normal homogenous echotexture. Parenchyma is diffusely hyperechoic characterized by less prominent than normal portal vein walls and increased echogenicity relative to the spleen and falciform fat. No focal lesions are observed. Visible vasculature and biliary tree appear normal without distension or congestion.

The gallbladder is non-distended in size. The wall is smooth without visible thickening. Luminal contents are primarily anechoic. There is no evidence of cystic or common bile duct dilation.



PATIENT

Misty Kropf

SPECIES

Feline

BREED

DSH

SEX

Spayed Female

AGE

11 Years 11 Months

WEIGHT

15

INTERPRETED BY

Beth Johnson, DVM
DACVIM

IMAGING PERFORMED BY

Jessica Green

HOSPITAL NAME

Stanglein Veterinary
Clinic

REFERRING VET

Dr. Erin Rothrock

INVOICE

73964

DATE

3/24/26

Gastrointestinal

Almost the entire gastric lumen appears to contain a homogeneous echogenic density/mass measuring approximately 2.3 cm x 3.6 cm. Luminal contents versus tissue can't be definitively ruled out, and doppler would be helpful in differentiating, but it appears to be tissue originating from the inner wall, especially given the concurrent lymphadenopathy.

The visible small intestine demonstrates areas of moderately thick muscularis layer relative to mucosa (disruption of the normal 1:3 muscularis:mucosa ratio). Small intestinal submucosa is slightly irregular, thick and hyperechoic, without evident loss of layering appreciated. The lumen of the small intestine is empty with no evidence of obstruction or foreign material.

The visible colon is normal in wall thickness (< 0.2 cm) and layering. Contents are consistent with normal formed feces and gas.

Pancreas

The pancreas that is observed appears appropriately isoechoic to surrounding omental fat. Visible capsule is smooth and normal in contour. Visible pancreatic parenchyma is homogenous and unremarkable. There is no visible pancreatic duct dilation. There is no evidence of active peripancreatic inflammation.

Free Abdomen

There is no visible free peritoneal effusion noted in these images.

Gastric lymph nodes are enlarged with swollen irregular capsular contour and loss of normal length to width ratio (rounded in shape). Nodes are hypoechoic with loss of normal parenchymal detail.

ULTRASONOGRAPHIC FINDINGS

- The gastric density described is concerning for an infiltrative neoplastic mass such as round cell neoplasia i.e., lymphoma versus other, especially given the concurrent adjacent lymphadenopathy. Having said that, a benign inflammatory process can't be ruled out without tissue sampling. Luminal contents such as a foreign object versus tissue is possible but considered much less likely based on appearance.
- Moderate inflammatory bowel disease (IBD) pattern – Thick muscularis has been reported with infiltrative bowel disease including both benign inflammatory disease as well as infiltrative neoplasia such as lymphoma. No loss of layering or distinct characteristics of malignancy are present. Therefore, differentials cannot be further ranked without tissue sampling.
- Hyperechoic hepatomegaly – This appearance is most consistent with benign hepatic lipodosis or endocrine/DM hepatopathy. Infiltrative disease such as amyloidosis or round cell neoplasia, such as mast cell tumor or less likely, lymphoma, is also possible.

INTERPRETATION OF THE FINDINGS & FURTHER RECOMMENDATIONS

Three view thoracic radiographs are recommended for further assessment of cardio-pulmonary status as well as to further evaluate for any evidence of metastatic disease, if not recently evaluated.

A gastrointestinal malabsorption panel (including cobalamin, folate, TLI and PLI) to Texas A&M GI Laboratory is recommended for further evaluation of GI and pancreatic function.



PATIENT

Misty Kropf

SPECIES

Feline

BREED

DSH

SEX

Spayed Female

AGE

11 Years 11 Months

WEIGHT

15

INTERPRETED BY

Beth Johnson, DVM
DACVIM

IMAGING PERFORMED BY

Jessica Green

HOSPITAL NAME

Stanglein Veterinary
Clinic

REFERRING VET

Dr. Erin Rothrock

INVOICE

73964

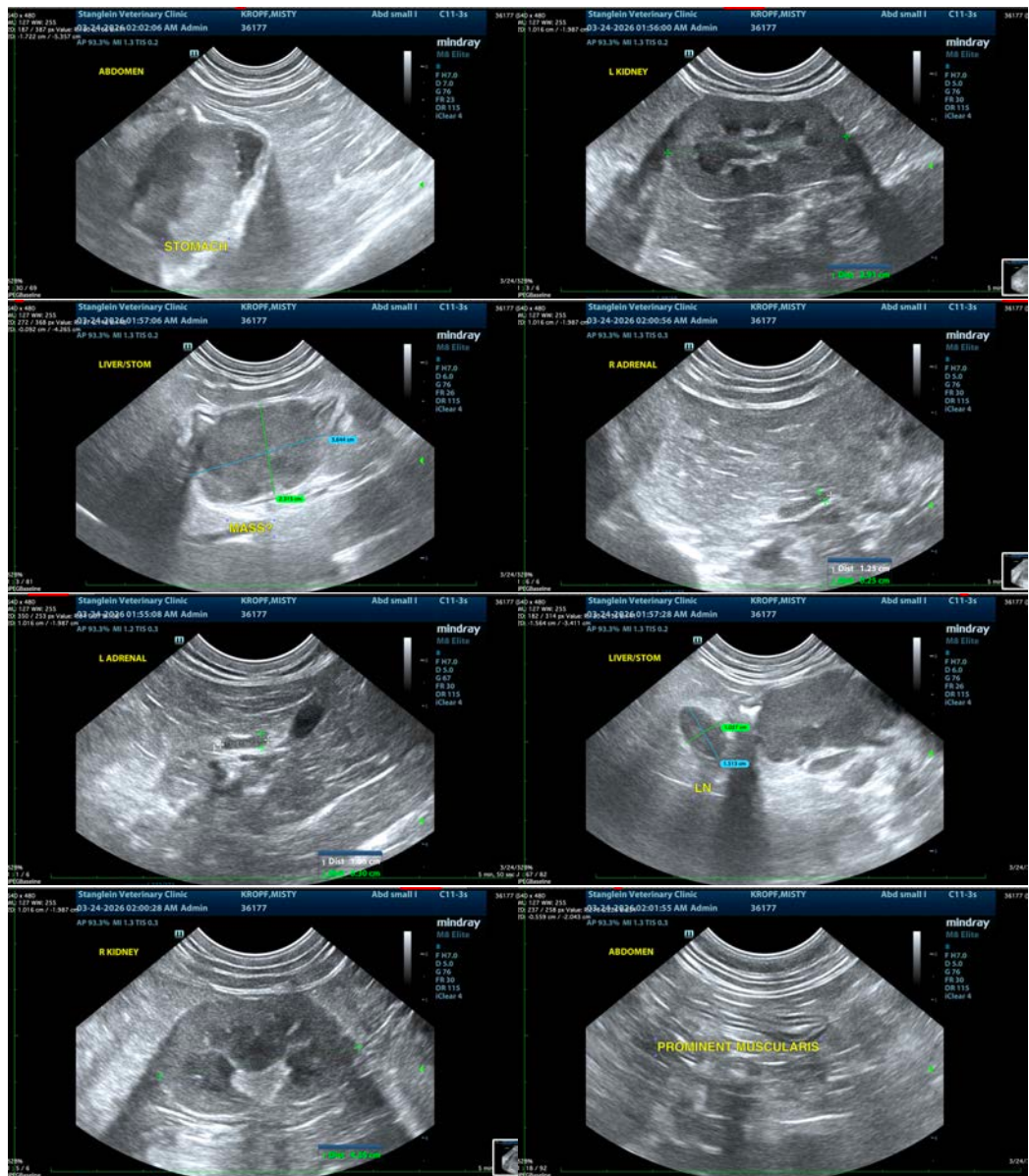
DATE

3/24/26

Fine needle aspirates of the suspected gastric mass and adjacent lymph nodes are recommended if patient's coagulation status is appropriate.

If a cytologic diagnosis is unable to be obtained, alternatively gastroscopy or an exploratory laparotomy could be considered for excisional biopsies and histopath.

Other than supportive/symptomatic medical management of clinical signs, further treatment recommendations are largely dependent on results of the above.





PATIENT

Misty Kropf

SPECIES

Feline

BREED

DSH

SEX

Spayed Female

AGE

11 Years 11 Months

WEIGHT

15

INTERPRETED BY

Beth Johnson, DVM
DACVIM

IMAGING PERFORMED BY

Jessica Green

HOSPITAL NAME

Stanglein Veterinary
Clinic

REFERRING VET

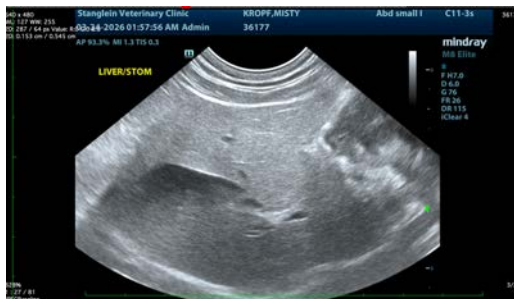Dr. Erin Rothrock

INVOICE

73964

DATE

3/24/26



The information and recommendations provided are based on the images presented by the referring veterinarian/sonographer. No evaluation can be communicated regarding pathology that was not visible in the image/video clips provided.

Thank you for this referral. If the clinical or image interpretation does not parallel your findings or if I can be of any further assistance please contact me.

Beth Johnson, DVM, DACVIM
info@sonopath.com