



PATIENT

Cooper Borso

SPECIES

Canine

BREED

Cocker Spaniel

SEX

Neutered Male

AGE

9 Years 2 Months

WEIGHT

36.8

INTERPRETED BY

Beth Johnson, DVM
DACVIM

IMAGING PERFORMED BY

Jessica Green

HOSPITAL NAME

Stanglein Veterinary
Clinic

REFERRING VET

Dr. Daniel Hoffman

INVOICE

73963

DATE

3/24/26

PRESENTING CLINICAL SIGNS

The patient has a long history of allergies and chronic/recurrent ear and skin infections.

He presented for an annual examination on 02/21/2026 and was noted to have lost about 10 pounds since the previous visit on 11/15/2025 (he was previously overweight to obese). The Owner reported that she had made several changes to Cooper's diet and feeding schedule, and was not overly concerned by the weight loss at that time. It was also reported that Cooper's allergies were doing well since the Owner started him on an "OTC allergy and itch supplement," which was later discovered to be Cyclosporine 50 mg from Wag! Laboratories. Aside from the weight loss, physical examination was relatively unremarkable and the patient's ears and skin looked better than they have in a long time. The Owner was reluctant to stop the Cyclosporine, but it was recommended that she at least halve the dose.

He presented again for a vaccine booster on 03/14/2026. The Owner now reported that the patient was PU/PD, and he had lost another 2.2 pounds since the previous visit. The Owner now consented to BW (results below).

Since these visits, I have seen some concerning reports about other dogs with similar issues (including severely elevated liver enzymes) following use of Wag! Laboratory's Cyclosporine, which can be obtained without a prescription.

Abnormal PE/Chem/CBC/UA Results: CBC: mild anemia (HCT = 38.1%), with mild reticulocytosis; stress leukogram; thrombocytosis (PLT = 758 K/uL) Chemistry: severe liver enzyme elevations - ALT = 441 U/L, ALKP = 2,768 U/L, and GGT = 197 U/L (but AST and TBIL WNL); there is also a mild hyperphosphatemia (PHOS = 6.4 mg/dL), but the kidney values are mildly low (BUN = 7 mg/dL, CREAT = 0.4 mg/dL) T4 = 1.7 ug/dL (normal) UA: USG = 1.021; marked bacteriuria, but suspected to be a contaminant from a free-catch sample since there were no WBC and the UA was otherwise normal A 4DX test was negative for HW and tick-borne diseases; a fecal screening was negative for ova and parasites.

ULTRASONOGRAPHIC EXAMINATION OF THE ABDOMEN

Urinary System

The urinary bladder is adequately distended with anechoic contents. No masses, inflammatory changes, echogenic sediment or cystoliths are observed. The urinary bladder, trigone and visible pelvic urethra are normal in thickness with a smooth mucosal surface.

The area of the prostate is examined without evident prostatic pathology.

The right kidney is normal is size (6.79 cm), shape and echogenicity. It has smooth peripheral margination. There is a normal 1:3 cortex to medulla ratio with appropriate corticomedullary distinction. There is no evidence of pyelectasia, mineral or infarcts observed.

The left kidney is normal is size (6.38 cm), shape and echogenicity. It has smooth peripheral margination. There is a normal 1:3 cortex to medulla ratio with appropriate corticomedullary distinction. There is no evidence of pyelectasia, mineral or infarcts observed.

Adrenal Glands

The right adrenal gland is normal in size (0.51 cm at cranial pole and 0.45 cm at caudal pole), shape and overall architecture, echogenicity and echotexture. Visible surrounding vasculature appears normal.



PATIENT

Cooper Borso

SPECIES

Canine

BREED

Cocker Spaniel

SEX

Neutered Male

AGE

9 Years 2 Months

WEIGHT

36.8

INTERPRETED BY

Beth Johnson, DVM
DACVIM

IMAGING PERFORMED BY

Jessica Green

HOSPITAL NAME

Stanglein Veterinary
Clinic

REFERRING VET

Dr. Daniel Hoffman

INVOICE

73963

DATE

3/24/26

The left adrenal gland is normal in size (0.54 cm at cranial pole and 0.44 cm at caudal pole), shape and overall architecture, echogenicity and echotexture. Visible surrounding vasculature appears normal.

Spleen

The spleen is subjectively normal in size with a normal smooth capsular contour. Parenchyma is appropriately finely textured and homogenous with normal echogenicity relative to surrounding tissue (hyperechoic to liver). No focal nodules or masses are observed. Splenic vasculature appears normal.

Liver

The liver is subjectively enlarged with mildly to moderately irregular margins. Parenchyma is mottled by multifocal discrete nodules of varying sizes, creating a “moth eaten” appearance. The nodules are largely hyperechoic in appearance, but many of them are surrounded by a hypoechoic rim, creating a “target lesion” appearance. Visible vasculature and biliary tree appear normal without distension or congestion.

Gallbladder is mildly overdistended with a moderate amount of non-dependent, mildly aggregated/inspissated sludge. Hypo to anechoic cystic areas are noted between the gallbladder sludge and luminal wall. The wall is otherwise smooth without visible thickening. There is no evidence of cystic or CBD dilation. There is no evidence of effusion.

Gastrointestinal

The visible stomach wall is normal in thickness and layering. The lumen of the stomach is empty with no evidence of obstruction, foreign material or infiltrative disease. Pyloric outflow tract appears patent.

The visible small intestines are normal in wall thickness and layering. Small intestinal motility appears adequate (1-3 contractions per min). The lumen is mildly distended with echogenic non-shadowing luminal contents and gas consistent with normal ingesta/chyme. There is no evidence of obstruction, foreign material or infiltrative disease.

The visible colon is normal in wall thickness (< 0.2 cm) and layering. Contents are consistent with normal formed feces and gas.

Pancreas

The pancreas that is observed appears appropriately isoechoic to surrounding omental fat. Visible capsule is smooth and normal in contour. Visible pancreatic parenchyma is homogenous and unremarkable. There is no visible pancreatic duct dilation. There is no evidence of active peripancreatic inflammation.

Free Abdomen

There is no visible free peritoneal effusion noted in these images.

There is no apparent pathologic lymphadenopathy noted in these images.

ULTRASONOGRAPHIC FINDINGS

- The nodular liver could represent a benign process such as nodular hyperplasia, fibrosis of old hematomas, granulomas, other chronic inflammatory change, with even some myelolipomas. However, especially given the “target lesion” appearance of some of the lesions, infiltrative neoplasia including metastatic versus other neoplasia, which can mimic benign lesions, can't be ruled out without tissue sampling.



PATIENT

Cooper Borso

SPECIES

Canine

BREED

Cocker Spaniel

SEX

Neutered Male

AGE

9 Years 2 Months

WEIGHT

36.8

INTERPRETED BY

Beth Johnson, DVM
DACVIM

IMAGING PERFORMED BY

Jessica Green

HOSPITAL NAME

Stanglein Veterinary
Clinic

REFERRING VET

Dr. Daniel Hoffman

INVOICE

73963

DATE

3/24/26

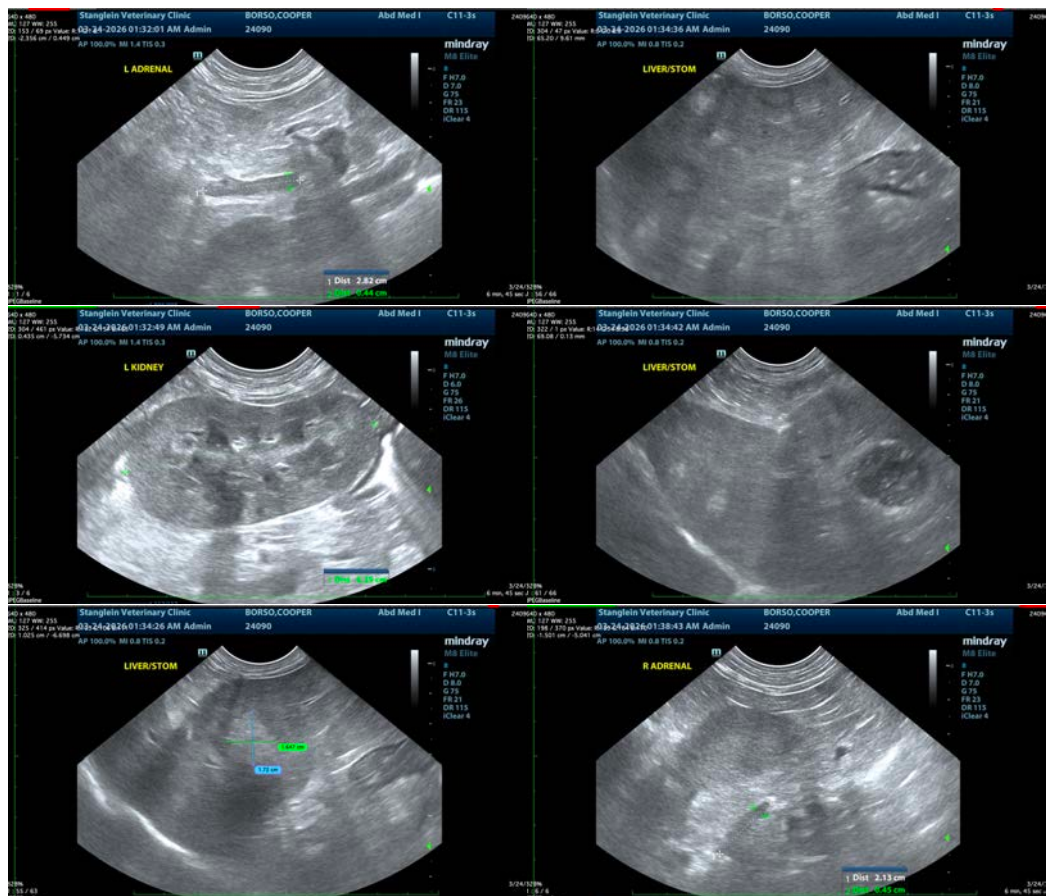
INTERPRETATION OF THE FINDINGS & FURTHER RECOMMENDATIONS

Three view thoracic radiographs are recommended for further assessment of cardio-pulmonary status as well as to further evaluate for any evidence of metastatic disease, if not recently evaluated.

Fine needle aspirates of the liver are recommended if patient's coagulation status is appropriate.

In the meantime, given the gallbladder debris, empirical hepatic nutraceuticals including Ursodiol could be considered while monitoring liver enzymes for improvement. This plan, however, should be instituted in combination with owner education about possible progression and the clinical signs of progression for an emerging gallbladder mucocele, as ultimately more aggressive intervention up to and including a possible cholecystectomy may be indicated.

Additionally, especially given patient's reported dietary changes combined with the weight loss, if not already evaluated, a thorough evaluation of daily caloric intake is recommended to assure an adequate daily caloric intake is occurring vs an inadvertent reduction in calories due to change in diet and/or feeding schedule, competitive eating environment, etc.





PATIENT

Cooper Borso

SPECIES

Canine

BREED

Cocker Spaniel

SEX

Neutered Male

AGE

9 Years 2 Months

WEIGHT

36.8

INTERPRETED BY

Beth Johnson, DVM
DACVIM

IMAGING PERFORMED BY

Jessica Green

HOSPITAL NAME

Stanglein Veterinary
Clinic

REFERRING VET

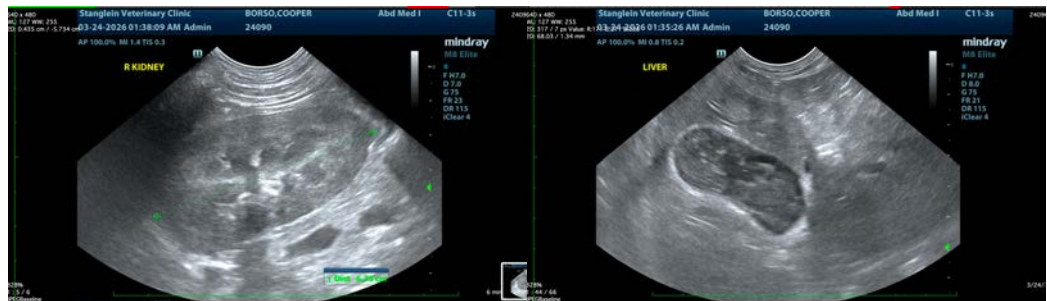
Dr. Daniel Hoffman

INVOICE

73963

DATE

3/24/26



The information and recommendations provided are based on the images presented by the referring veterinarian/sonographer. No evaluation can be communicated regarding pathology that was not visible in the image/video clips provided.

Thank you for this referral. If the clinical or image interpretation does not parallel your findings or if I can be of any further assistance please contact me.

Beth Johnson, DVM, DACVIM
info@sonopath.com