

PATIENT

Buddy Cutler

SPECIES

Feline

BREED

DSH

SEX

MN

AGE

13 years 7 months

WEIGHT

6.07 lbs

INTERPRETED BY

Beth Johnson, DVM
DACVIM

IMAGING PERFORMED BY

Loetitia Saint-Jacques,
LVT

HOSPITAL NAME

VCA Feline Animal
Hospital

REFERRING VET

Dr. Kaitlin Smith

INVOICE

11562

DATE

3/24/2026

PRESENTING CLINICAL SIGNS

- Chronic intermittent vomiting - progressive, Suspect polyphagia, Weight loss

Abnormal PE/Chem/CBC/UA Results: Labwork - CBC: HCT 42, mild eosinophilia 1008 (ref 0-1000), platelets 172 (d/t clumping) CHEM: BUN 49, creatinine 1.5, SDMA 27.2, precisionPSL 103 (ref 8-26) T4: 2.2 UA: USG 1.030, protein 1+.

ULTRASONOGRAPHIC EXAMINATION OF THE ABDOMEN

Urinary System

The urinary bladder is adequately distended with anechoic contents. No masses, inflammatory changes, echogenic sediment or cystoliths are observed. The urinary bladder, trigone and visible pelvic urethra are normal in thickness with a smooth mucosal surface.

Kidneys are overall normal in size and shape with smooth peripheral margination. A normal 1:3 cortex to medulla ratio is maintained. The medulla and cortices are uniform in texture with some mild increased cortical echogenicity and mild loss of corticomedullary distinction, expected in this age patient. There is no evidence of pyelectasia, mineral or infarcts observed. Left kidney measures 3.27 cm, and the right kidney measures 2.99 cm.

Adrenal Glands

The right adrenal gland is normal in size (0.34 cm), shape and overall architecture, echogenicity and echotexture. Visible surrounding vasculature appears normal.

The left adrenal gland is normal in size (0.34 cm), shape and overall architecture, echogenicity and echotexture. Visible surrounding vasculature appears normal.

Spleen

Spleen is subjectively large in size (1.3 cm thick at the hilus) with a mildly swollen but smooth capsule. Parenchyma is normal and homogenous in echogenicity and echotexture. No focal nodules or masses are observed. Splenic vasculature appears normal.

Liver

The liver is subjectively normal in size with normal smooth curvilinear peripheral contour. Parenchyma is appropriately hypoechoic to the spleen in echogenicity and appropriately mildly coarse and homogenous in echotexture. No focal lesions are observed. Visible vasculature and biliary tree appear normal without distension or congestion.

The gallbladder is non-distended in size. The wall is smooth without visible thickening. Luminal contents are primarily anechoic. There is no evidence of cystic or common bile duct dilation.

Gastrointestinal

The visible stomach wall is normal in thickness and layering. The lumen is mildly distended with primarily fluid as well as some echogenic non-shadowing luminal contents and gas consistent with normal chyme. There is no evidence of obstruction, foreign material, or infiltrative disease. Pyloric outflow tract appears patent.



PATIENT

Buddy Cutler

SPECIES

Feline

BREED

DSH

SEX

MN

AGE

13 years 7 months

WEIGHT

6.07 lbs

INTERPRETED BY

Beth Johnson, DVM
DACVIM

**IMAGING
PERFORMED BY**

Loetitia Saint-Jacques,
LVT

HOSPITAL NAME

VCA Feline Animal
Hospital

REFERRING VET

Dr. Kaitlin Smith

INVOICE

11562

DATE

3/24/2026

The visible small intestine demonstrates areas of very prominently thick muscularis layer relative to mucosa (disruption of the normal 1:3 muscularis:mucosa ratio). Small intestinal submucosa is slightly irregular, thick and hyperechoic, without evident loss of layering appreciated. The lumen of the small intestine is empty with no evidence of obstruction or foreign material.

The visible colon is normal in wall thickness (< 0.2 cm) and layering. Contents are consistent with normal formed feces and gas.

Pancreas

Pancreas is prominent (enlarged) in size, hypoechoic to surrounding tissue and has a mildly irregular undulating contour. Parenchyma is coarse with mixed echogenic remodeling noted. No pancreatic duct dilation is noted.

Free Abdomen

There is trace free fluid noted in these images.

Mesenteric lymph nodes are prominent in size with swollen capsular contour. Normal elongated shape (length to width ratio) is maintained. There is no loss of parenchymal detail.

PRIMARY FINDINGS

- Marked/significantly Inflammatory bowel disease (IBD) pattern – Thick muscularis has been reported with infiltrative bowel disease including both benign inflammatory disease as well as infiltrative neoplasia such as lymphoma. No loss of layering or distinct characteristics of malignancy are present. Therefore, differentials cannot be further ranked without tissue sampling.
- Splenomegaly– can be associated with congestion caused by sedation (if sedated) but can also be associated with diffuse infiltrative disease. Both benign conditions such as extramedullary hematopoiesis, lymphoid hyperplasia, amyloidosis as well as infiltrative neoplastic diseases such as round cell neoplasia should be considered.
- Marked/significant reactive lymph nodes – infiltrative neoplastic disease cannot be ruled out but is considered less likely.
- Trace free fluid is of unknown origin. Differentials (unless already ruled out) could include increased hydrostatic pressure (cardiac disease and/or vascular or lymph blockage), decreased oncotic pressure (low albumin), vasculitis, paraneoplastic fluid, rupture/leakage of/from an organ (GI, GB, UB, other), blood (hemoabdomen), other.
- Concurrent chronic low grade smoldering pancreatitis can't be ruled out and should be suspected in the face of appropriate clinical signs.

SECONDARY FINDINGS

- Age related kidney changes.

INTERPRETATION OF THE FINDINGS & FURTHER RECOMMENDATIONS

A routine fecal/giardia exam is recommended if not recently evaluated.



PATIENT

A gastrointestinal malabsorption panel (including cobalamin, folate, TLI and PLI) to Texas A&M GI Laboratory is recommended for further evaluation of GI and pancreatic function.

Buddy Cutler

SPECIES

A fecal enteropathogen PCR panel to Texas A&M GI Laboratory could be considered for further evaluation of possible infectious disease. Contact lab for recommendations on how long to discontinue antibiotics (if indicated) prior to obtaining a stool sample for submission.

Feline

BREED

Tissue sampling is recommended. Fine needle aspirates of the enlarged lymph nodes and the spleen +/- fluid sampling, if it can safely be reached, could all be considered if patient's coagulation status is appropriate but if a cytologic diagnosis is unable to be obtained, ultimately, biopsies of the GI tract being sure to include ileum, if possible, may be necessary for a definitive diagnosis and therefore to further guide medical management.

DSH

SEX

If biopsies cannot be obtained, empirical therapies could include a probiotic (if diarrhea is present, such as visbiome or proviable), empirical deworming with a 5-day course of Panacur and, if tolerated, a transition in diet, based on trial-and-error response, beginning with a hydrolyzed protein diet. Some patients respond to one brand/version of a hydrolyzed protein diet better than another brand, so several trials may be required.

MN

AGE

13 years 7 months

Additional considerations could include cobalamin supplementation (unless cobalamin level is evaluated and supplementation is not warranted) and prednisolone (if not contraindicated based on patient contraindications, co-morbidities, etc.).

WEIGHT

6.07 lbs

INTERPRETED BY

Beth Johnson, DVM
DACVIM

IMAGING PERFORMED BY

Loetitia Saint-Jacques,
LVT

HOSPITAL NAME

VCA Feline Animal
Hospital

REFERRING VET

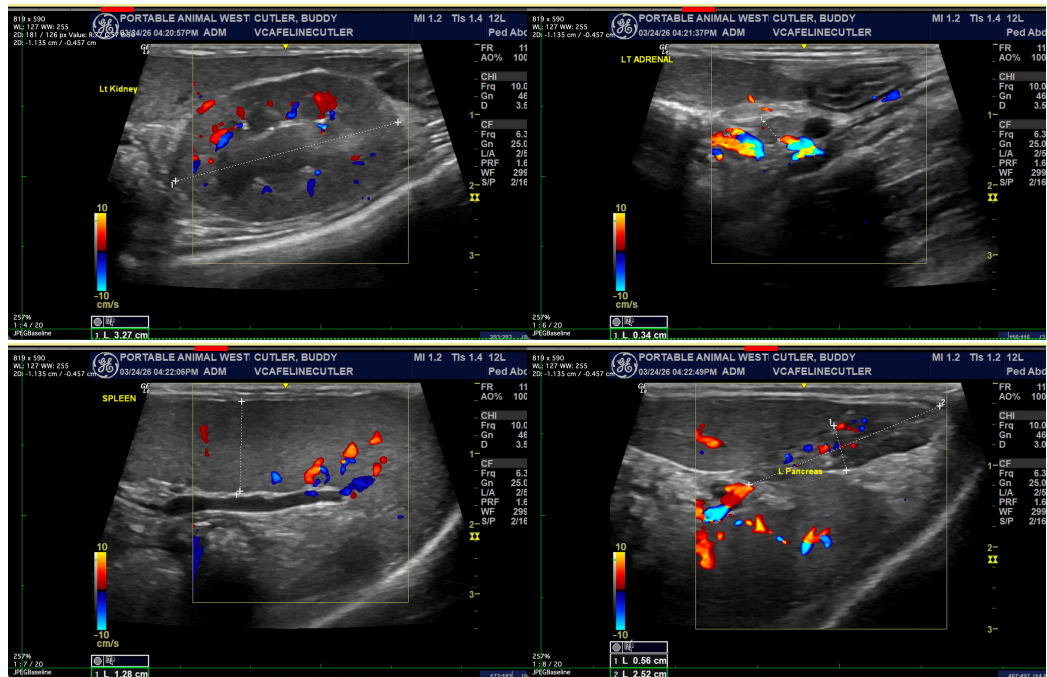
Dr. Kaitlin Smith

INVOICE

11562

DATE

3/24/2026



Imaging performed by



pawsonography@gmail.com
530-786-8340



Clinical Sonography & Telectylogy
Educational Teleconsultation Services™

SonoPath

FOSTERING THE ART OF VETERINARY MEDICINE™

SonoPath.com info@sonopath.com 1.800.838.4268

PATIENT

Buddy Cutler

SPECIES

Feline

BREED

DSH

SEX

MN

AGE

13 years 7 months

WEIGHT

6.07 lbs

INTERPRETED BY

Beth Johnson, DVM
DACVIM

IMAGING PERFORMED BY

Loetitia Saint-Jacques,
LVT

HOSPITAL NAME

VCA Feline Animal
Hospital

REFERRING VET

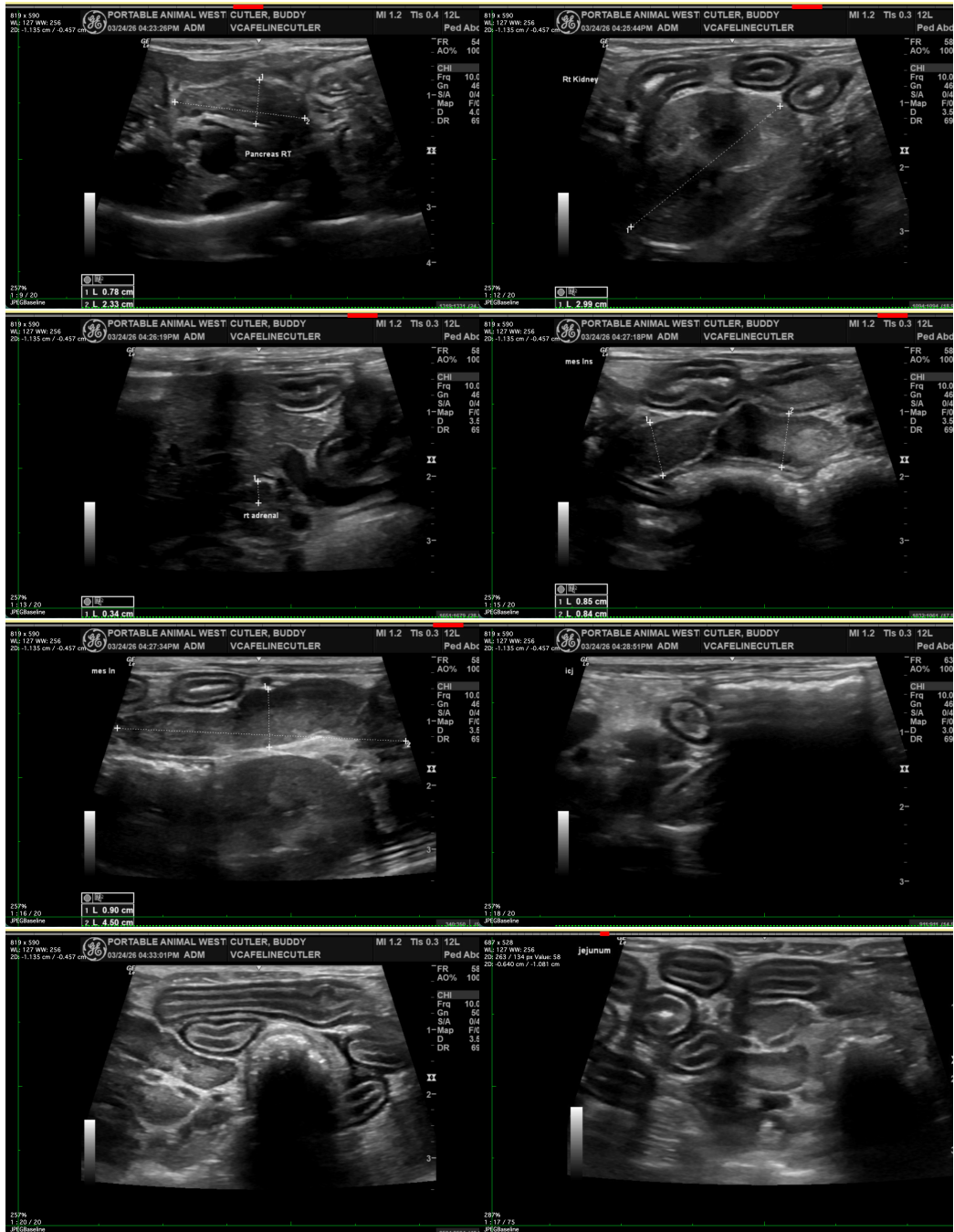
Dr. Kaitlin Smith

INVOICE

11562

DATE

3/24/2026



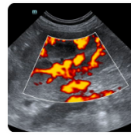
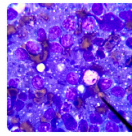
The information and recommendations provided are based on the images presented by the referring veterinarian/sonographer. No evaluation can be communicated regarding pathology that was not visible in the image/video clips provided.

Thank you for this referral. If the clinical or image interpretation does not parallel your findings or if I can be of any further assistance please contact me.

Imaging
performed by



Feline Animal Wellness Sonography, Inc.
pawsonography@gmail.com
530-786-8340



Clinical Sonography & Telectology
Educational Teleconsultation Services™

SonoPath

FOSTERING THE ART OF VETERINARY MEDICINE™

SonoPath.com  info@sonopath.com  1.800.838.4268

PATIENT

Beth Johnson, DVM, DACVIM
info@sonopath.com

Buddy Cutler

SPECIES

Feline

BREED

DSH

SEX

MN

AGE

13 years 7 months

WEIGHT

6.07 lbs

INTERPRETED BY

Beth Johnson, DVM
DACVIM

**IMAGING
PERFORMED BY**

Loetitia Saint-Jacques,
LVT

HOSPITAL NAME

VCA Feline Animal
Hospital

REFERRING VET

Dr. Kaitlin Smith

INVOICE

11562

DATE

3/24/2026