

**DATE PRESENTING CLINICAL SIGNS**

3/24/22

Presented March for recent hx of discomfort in hind region, biting /lungingat back area (not side specific) , can be painful with picking up sometimes, increased frequency of urination - wanting to go out multiple times at night and paces. Recent update: started on carprofen/Gabapentin- was sleeping better in the night but still have some of the biting /turning to back area. Right anal gland full difficult to express contents look infected started on amoxi clavamox on intended to start Monday but delayed due to GI upset post sedation.

PATIENT

Athenos Thomas

SPECIES

Canine

BREED

Bichon Frise

SEX

Neutered Male

AGE

7/11/10

WEIGHT

19.2 Pounds

INTERPRETED BYBeth Johnson, DVM
DACVIM**IMAGING PERFORMED BY**Stephanie Pearce
RDMS, RVT**HOSPITAL NAME**

Noah's Ark Veterinary

REFERRING VETDr. Martinez-
Hernandez**INVOICE**

36451

Current Medications: Carprofen- started 1-3-22, Gabapentin- started on 1-3-22, Amoxicillin /Clavamox- started sent home – postponed, Cerenia - 24 mg.

Lab Results: NSF. CPL/Clotting factors pending.

Radiographs: there was a large round soft tissue opacity in mid- ventral abdomen, I did not appreciate any uroliths/nephroliths with radiographs but quick US scan - I saw some changes to the left kidney but not sure if age vs. other.

Date of Previous IntraPet Ultrasound: No previous.

Sedation: Not required to complete full diagnostic ultrasound.

Stat Report: Not requested.

ULTRASONOGRAPHIC EXAMINATION OF THE ABDOMEN**Urinary System**

The urinary bladder is moderately distended with anechoic contents. No masses or inflammatory changes. Calculi exhibiting distal acoustic shadowing are present along the gravity dependent inner wall of the lumen of the urinary bladder and throughout the lumen of the urethra. In the urinary bladder, the mineral debris measures either a 0.45 cm stone or 0.45 cm length of accumulated smaller stones/sand/debris. The urinary bladder, trigone and visible pelvic urethra are normal in thickness with a smooth mucosal surface.

Prostate (neutered) is normal in size, echotexture and echogenicity for a neutered male.

The right kidney is normal in size (5.18 cm), shape and echogenicity. It has smooth peripheral margination. There is a normal 1:3 cortex to medulla ratio with appropriate corticomedullary distinction. There is no evidence of pyelectasia or infarcts observed. Non-obstructive areas of mineralization/nephroliths are noted, primarily in the diverticular of the kidney.

The left kidney is normal in size (4.64 cm), shape and echogenicity. It has smooth peripheral margination. There is a normal 1:3 cortex to medulla ratio with appropriate corticomedullary distinction. There is no evidence of pyelectasia or infarcts observed. Non-obstructive areas of mineralization/nephroliths are noted, primarily in the diverticular of the kidney.

Adrenal Glands

The right adrenal gland is normal in size (2.11 cm long x 0.50 cm at the cranial pole and 0.52 cm at the caudal pole), shape and contour. Corticomedullary structure is unremarkable. Visible surrounding vasculature appears normal.

The left adrenal gland is normal in size (2.22 cm long x 0.45 cm at the cranial pole and 0.61 cm at the caudal pole), shape and contour. Corticomedullary structure is unremarkable. Visible surrounding vasculature appears normal.

Spleen

The spleen is subjectively normal in size with a normal smooth capsular contour. Parenchyma is appropriately finely textured and homogenous with normal echogenicity relative to surrounding tissue (hyperechoic to liver). No focal nodules or masses are observed. Splenic vasculature appears normal.

Liver

The liver is subjectively normal in size with normal smooth curvilinear peripheral contour. Parenchyma is appropriately hypoechoic to the spleen in echogenicity and appropriately mildly coarse and homogenous in echotexture. No focal lesions are observed. Visible vasculature and biliary tree appear normal without distension or congestion.

GB is moderately distended with anechoic bile and gravity dependent echogenic sediment. The wall is smooth without visible thickening. There is no evidence of cystic or CBD dilation. There is no evidence of effusion or inflammation.

Gastrointestinal

The stomach wall is normal in thickness (canine < 0.5 cm and feline < 0.4 cm) and layering. The lumen of the stomach is empty with no evidence of obstruction, foreign material or infiltrative disease. Pyloric outflow tract appears patent.

The visible small intestines are normal in wall thickness and layering (canine duodenum < 0.5 cm and feline duodenum < 0.4 cm; other < 0.3 cm). Small intestinal motility appears adequate (1-3 contractions per min). The lumen of the small intestine is empty with no evidence of obstruction, foreign material or infiltrative disease.

The visible colon is normal in wall thickness (< 0.2 cm) and layering. Contents are consistent with normal formed feces and gas.

Pancreas

The pancreatic parenchyma is appropriately isoechoic to surrounding tissue. Visible capsule is smooth and normal in contour. There is no visible pancreatic duct dilation. There is no evidence of active peripancreatic inflammation.

Free Abdomen

There is no evidence of peritoneal effusion. There is no apparent lymphadenopathy. The suspected abdominal mass is not present in these images.

PRIMARY FINDINGS

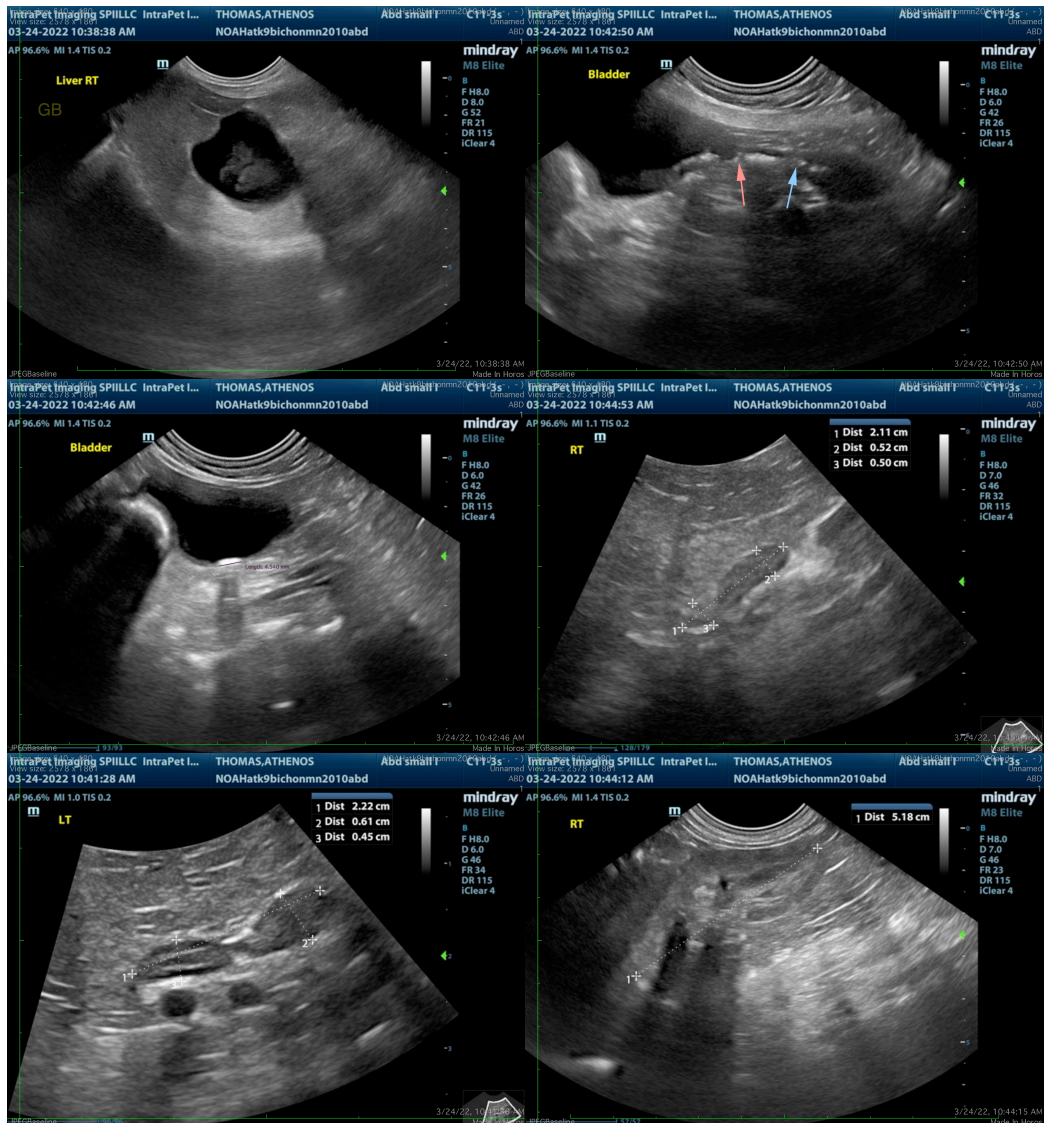
- Urinary bladder mineral sand/debris/calculus as well as mineral debris/sand throughout the lumen of the urethra
- Non-obstructive nephrolithiasis

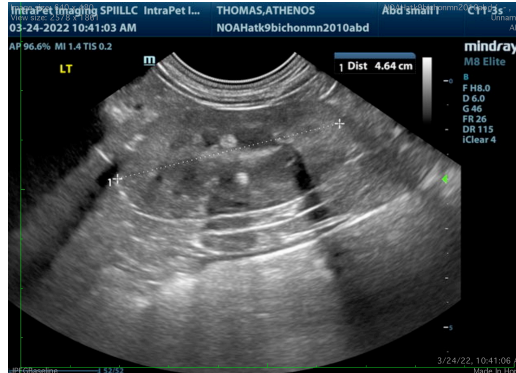SECONDARY FINDINGS

- Gallbladder debris - Cholecystic debris is of unknown clinical significance. It can be seen with biliary stasis from fasting or illness. Cholecystic debris is not necessarily related to hepatobiliary disease. Echogenic bile is most commonly an incidental finding in dogs and should be interpreted in combination with clinical signs such as nausea, inappetence, cranial abdominal discomfort and/or laboratory changes such as increased ALP and/or increased Tbili.

INTERPRETATION OF THE FINDINGS & FURTHER RECOMMENDATIONS

Recommendations include a urine culture if not recently evaluated as well as placement of a urinary catheter in an attempt to push the debris present in the urethra back into the lumen of the bladder, followed by a bladder flush/voiding urohydropropulsion for mineral collection/analysis/ID. If the accumulated debris in these images is actually one single urinary bladder cystoliths, removal via this method may not be possible, and cystotomy may be required for stone removal.





The information and recommendations provided are based on the images presented by the referring veterinarian/sonographer. No evaluation can be communicated regarding pathology that was not visible in the image/video clips provided.

Thank you for this referral. If the clinical or image interpretation does not parallel your findings or if I can be of any further assistance please contact me.

Beth Johnson, DVM, DACVIM
Beth.Johnson@sonopath.com