

PATIENT

Tokyo Wang

SPECIES

Canine

BREED

Chi X

SEX

MN

AGE

6Y

WEIGHT

6.93kg

INTERPRETED BY

Beth Johnson, DVM,
 DACVIM (SAIM)

IMAGING PERFORMED BY

Kelly Reschny

HOSPITAL NAME

Governors Road AH

REFERRING VET

Dogar

INVOICE

74297

DATE

3-23-26

PRESENTING CLINICAL SIGNS

- Small soft tissue swelling mid ventral abdomen/ umbilicus. Unable to reduce the size of swelling.
- MPL Grade I-II
- M1-2 plaque
- BCS 6/9
- Current Medications
- Cytopoint

Abnormal PE/Chem/CBC/UA Results: ALB: 41 (23-40) ALT: 145 (0-125) ALP< 10 BT: 21 (0-15)

ULTRASONOGRAPHIC EXAMINATION OF THE ABDOMEN

Urinary System

Urinary bladder is adequately distended with anechoic contents. No masses, inflammatory changes, echogenic sediment or cystoliths are observed. The urinary bladder, trigone and visible pelvic urethra are normal in thickness with a smooth mucosal surface.

Prostate is normal in size, echotexture and echogenicity for a neutered male.

Left kidney is normal in size (4.05 cm), shape and echogenicity. It has smooth peripheral margination. There is a normal 1:3 cortex to medulla ratio with appropriate corticomedullary distinction. There is no evidence of pyelectasia, mineral or infarcts observed.

Right kidney is normal in size (3.59 cm), shape and echogenicity. It has smooth peripheral margination. There is a normal 1:3 cortex to medulla ratio with appropriate corticomedullary distinction. There is no evidence of pyelectasia, mineral or infarcts observed.

Adrenal Glands

Left adrenal gland is normal in size (0.34 cm at cranial pole and 0.33 cm at caudal pole), shape and overall architecture, echogenicity and echotexture. Visible surrounding vasculature appears normal.

Right adrenal gland is normal in size (1.0 cm at cranial pole and 0.42 cm at caudal pole), shape and overall architecture, echogenicity and echotexture. Visible surrounding vasculature appears normal.

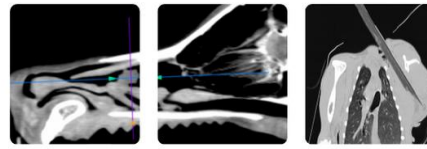
Spleen

Spleen is subjectively normal in size with a normal smooth capsular contour. Parenchyma is appropriately finely textured and homogenous with normal echogenicity relative to surrounding tissue (hyperechoic to liver). No focal nodules or masses are observed. Splenic vasculature appears normal.

Liver

Liver is subjectively normal in size with normal smooth curvilinear peripheral contour. Parenchyma is appropriately hypoechoic to the spleen in echogenicity and appropriately mildly coarse and homogenous in echotexture. No focal lesions are observed. Visible vasculature and biliary tree appear normal without distension or congestion.

Gallbladder is non-distended in size. The wall is smooth without visible thickening. Luminal contents are primarily anechoic. There is no evidence of cystic or common bile duct dilation.



PATIENT

Tokyo Wang

SPECIES

Canine

BREED

Chi X

SEX

MN

AGE

6Y

WEIGHT

6.93kg

INTERPRETED BY

Beth Johnson, DVM,
 DACVIM (SAIM)

IMAGING PERFORMED BY

Kelly Reschny

HOSPITAL NAME

Governors Road AH

REFERRING VET

Dogar

INVOICE

74297

DATE

3-23-26

Gastrointestinal

The visible stomach wall is normal in thickness and layering. The lumen of the stomach is mildly distended with very echogenic reverberation artifact from intraluminal gas. There is no evidence of obstruction, foreign material or infiltrative disease; however, complete visualization of far wall is partially inhibited by gas. Pyloric outflow tract appears patent.

The visible small intestines are normal in wall thickness and layering. Small intestinal motility appears adequate (1-3 contractions per min). The lumen of the small intestine is mildly distended with very echogenic reverberation artifact from intraluminal gas. There is no evidence of obstruction, foreign material, or infiltrative disease; however, visualization is partially inhibited by gas.

The visible colon is normal in wall thickness (< 0.2 cm) and layering. Contents are consistent with normal formed feces and gas.

Pancreas

The pancreas that is observed appears appropriately isoechoic to surrounding omental fat. Visible capsule is smooth and normal in contour. Visible pancreatic parenchyma is homogenous and unremarkable. There is no visible pancreatic duct dilation. There is no evidence of active peripancreatic inflammation.

Free Abdomen

There is no visible free peritoneal effusion noted in these images.

There is no apparent pathologic lymphadenopathy noted in these images.

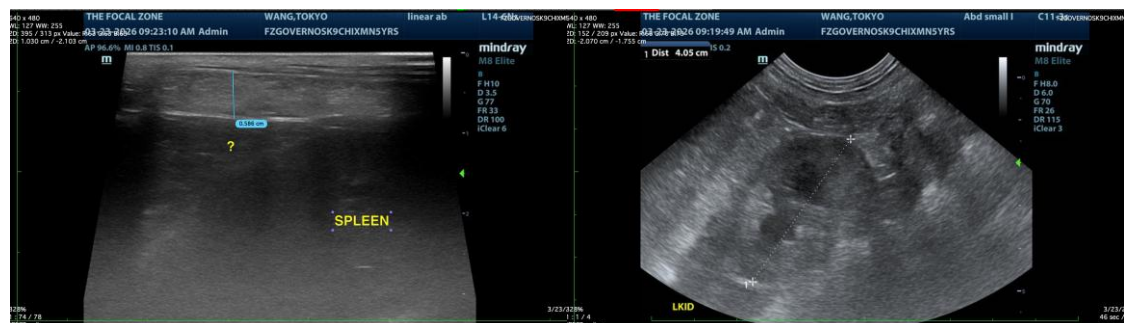At the end of the study with the linear probe, there is a subtle very mildly heterogeneous largely iso- to slightly hyper-echoic density subcutaneous measuring approximately 0.4 x 0.5 cm thick by 2.2 cm long.

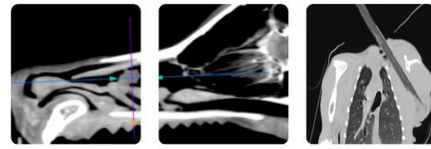
ULTRASONOGRAPHIC FINDINGS

- This is largely an unremarkable/normal structural abdomen except for the subtle suspect subcutaneous density which may represent the reported palpable structure.

INTERPRETATION OF THE FINDINGS & FURTHER RECOMMENDATIONS

The density appears solid tissue and potentially consistent with fat such as a lipoma although sampling via FNA should be considered for further information if patient's coagulation status is appropriate.





PATIENT

Tokyo Wang

SPECIES

Canine

BREED

Chi X

SEX

MN

AGE

6Y

WEIGHT

6.93kg

INTERPRETED BY

Beth Johnson, DVM,
 DACVIM (SAIM)

IMAGING PERFORMED BY

Kelly Reschny

HOSPITAL NAME

Governors Road AH

REFERRING VET

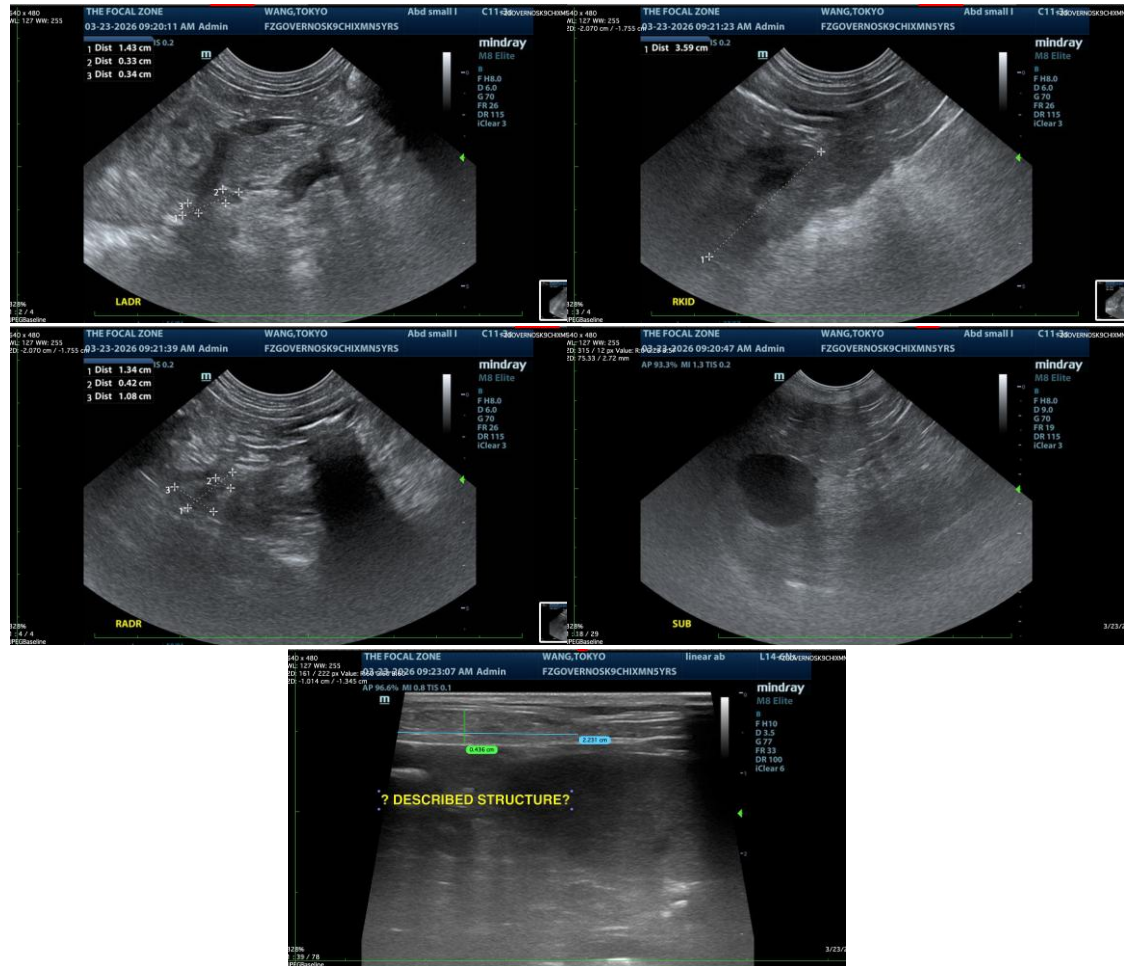
Dogar

INVOICE

74297

DATE

3-23-26



The information and recommendations provided are based on the images presented by the referring veterinarian/sonographer. No evaluation can be communicated regarding pathology that was not visible in the image/video clips provided.

Thank you for this referral. If the clinical or image interpretation does not parallel your findings or if I can be of any further assistance please contact me.

Beth Johnson, DVM DACVIM

info@sonopath.com