

PRESENTING CLINICAL SIGNS

PATIENT

Luna Bellizzi

Bloodwork February 2026: mild elevation in calcium 11.9, ALB 3, ALT 326 (last year was 37). No clinical signs. Progressive alopecia.

SPECIES

Canine

ULTRASONOGRAPHIC EXAMINATION OF THE ABDOMEN

Urinary System

BREED

Heeler Mix

Urinary bladder is adequately distended with anechoic contents. No masses, inflammatory changes, echogenic sediment or cystoliths are observed. The urinary bladder, trigone and visible pelvic urethra are normal in thickness with a smooth mucosal surface.

SEX

Spayed Female

Left kidney is normal in size (4.77 cm), shape and echogenicity. It has smooth peripheral margination. There is a normal 1:3 cortex to medulla ratio with appropriate corticomedullary distinction. There is no evidence of pyelectasia or infarcts observed. At least one small nonobstructive nephrolith, measuring 0.4 cm, is visible.

AGE

7 Years

Right kidney is normal in size (5.3 cm), shape and echogenicity. It has smooth peripheral margination. There is a normal 1:3 cortex to medulla ratio with appropriate corticomedullary distinction. There is no evidence of pyelectasia or infarcts observed. At least one small nonobstructive nephrolith, measuring 0.3 cm, is visible.

WEIGHT

33 Pounds

Adrenal Glands

INTERPRETED BY

Beth Johnson, DVM,
DACVIM (SAIM)

Left adrenal gland is normal in size (0.46 cm at cranial pole and 0.54 cm at caudal pole), shape and overall architecture, echogenicity and echotexture. Visible surrounding vasculature appears normal.

Right adrenal gland is normal in size (0.6 cm at cranial pole and 0.49 cm at caudal pole), shape and overall architecture, echogenicity and echotexture. Visible surrounding vasculature appears normal.

Spleen

IMAGING PERFORMED BY

Pamela Harrigan, RDCS,
Certified Veterinary
Sonographer (IVUSS)

Spleen is subjectively normal in size with a normal smooth capsular contour. Parenchyma is appropriately finely textured and homogenous with normal echogenicity relative to surrounding tissue (hyperechoic to liver). No focal nodules or masses are observed. Splenic vasculature appears normal.

HOSPITAL NAME

Rhode Island Animal
Medical Center

Liver

Liver is subjectively enlarged with mildly irregular margins. Parenchyma is mildly heterogenous characterized by multiple poorly defined hypoechoic nodules within otherwise hyperechoic liver parenchyma. Visible vasculature and biliary tree appear normal without distension or congestion.

REFERRING VET

Rachel Rogoff, DVM

Gallbladder is moderately distended with anechoic bile as well as suspended and gravity dependent echogenic debris. The wall is smooth without visible thickening. There is no evidence of cystic or CBD dilation. There is no evidence of effusion or inflammation. In some views, there appears to be an approximately 1.5 cm x 2.0 cm echogenic possibly mineral nonshadowing, non-visibly-obstructive density potentially representing a non-shadowing cholecystolith.

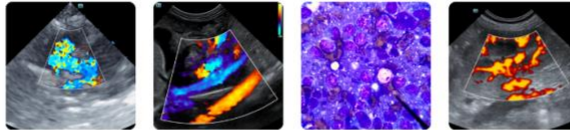
INVOICE

36353

Gastrointestinal

DATE

3/23/26



PATIENT

Luna Bellizzi

SPECIES

Canine

BREED

Heeler Mix

SEX

Spayed Female

AGE

7 Years

WEIGHT

33 Pounds

INTERPRETED BY

Beth Johnson, DVM,
DACVIM (SAIM)

IMAGING PERFORMED BY

Pamela Harrigan, RDCS,
Certified Veterinary
Sonographer (IVUSS)

HOSPITAL NAME

Rhode Island Animal
Medical Center

REFERRING VET

Rachel Rogoff, DVM

INVOICE

36353

DATE

3/23/26

The visible stomach wall is normal in thickness and layering. The lumen of the stomach is empty with no evidence of obstruction, foreign material or infiltrative disease. Pyloric outflow tract appears patent.

The visible small intestines are normal in wall thickness and layering. Small intestinal motility appears adequate (1-3 contractions per min). The lumen of the small intestine is empty with no evidence of obstruction, foreign material or infiltrative disease.

The visible colon is normal in wall thickness (< 0.2 cm) and layering. Contents are consistent with normal formed feces and gas.

Pancreas

The pancreas that is observed appears appropriately isoechoic to surrounding omental fat. Visible capsule is smooth and normal in contour. Visible pancreatic parenchyma is homogenous and unremarkable. There is no visible pancreatic duct dilation. There is no evidence of active peripancreatic inflammation.

Free Abdomen

There is no visible free peritoneal effusion noted in these images.

There is no apparent pathologic lymphadenopathy noted in these images.

ULTRASONOGRAPHIC FINDINGS

- An obvious cause for the subtle liver changes is not identified in these images. Microscopic disease such as Leptospirosis, bacterial cholangiohepatitis, chronic active hepatitis, copper-associated hepatotoxicity, other hepatotoxicity, other reactive hepatopathy, infiltrative neoplasia, etc. cannot be definitively ruled out.
- Moderate gallbladder debris- Cholecystic debris is of unknown clinical significance. It can be seen with biliary stasis from fasting or illness. Cholecystic debris is not necessarily related to hepatobiliary disease. Echogenic bile is most commonly an incidental finding in dogs and should be interpreted in combination with clinical signs such as nausea, inappetence, cranial abdominal discomfort and/or laboratory changes such as increased ALP and/or increased Tbili. A non-visibly-obstructive, non-shadowing cholelith is suspected.
- Bilateral nonobstructive nephroliths

INTERPRETATION OF THE FINDINGS & FURTHER RECOMMENDATIONS

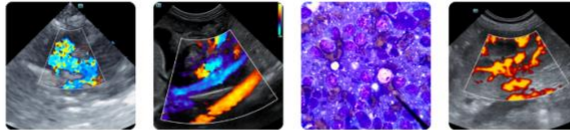
A malignancy panel (PTH, PTHrP, iCa) to Michigan State College of Veterinary Medicine is recommended for further investigation of the reported hypercalcemia.

If not recently evaluated, a thorough rectal and perianal exam is recommended.

Three view thoracic radiographs are recommended for further assessment of cardio-pulmonary status as well as to further evaluate for any evidence of metastatic disease, if not recently evaluated.

Pending results of the hypercalcemia work up:

Differentials for a primary hepatocellular injury liver enzyme pattern (increased ALT) depend partially on the level of increase. Mild increases (less than 2 times normal) are often a "reactive hepatopathy" or



PATIENT

Luna Bellizzi

SPECIES

Canine

BREED

Heeler Mix

SEX

Spayed Female

AGE

7 Years

WEIGHT

33 Pounds

INTERPRETED BY

Beth Johnson, DVM,
DACVIM (SAIM)

**IMAGING
PERFORMED BY**

Pamela Harrigan, RDCS,
Certified Veterinary
Sonographer (IVUSS)

HOSPITAL NAME

Rhode Island Animal
Medical Center

REFERRING VET

Rachel Rogoff, DVM

INVOICE

36353

DATE

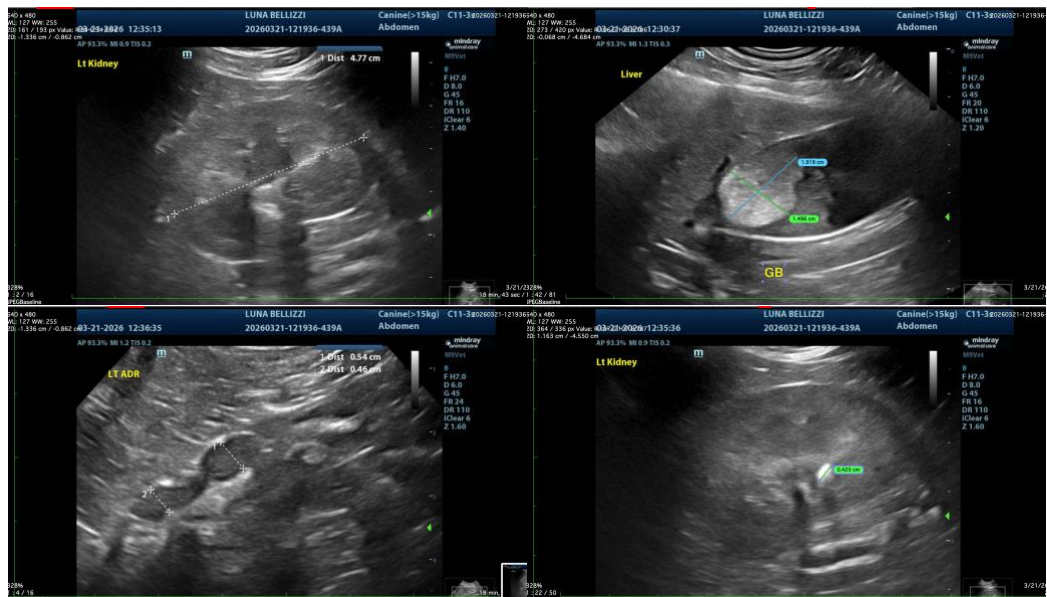
3/23/26

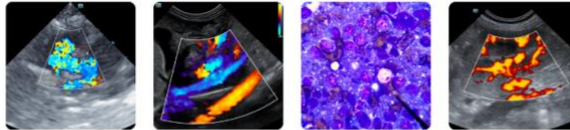
the liver's response to an insult elsewhere in the body including, but not limited to, pancreatitis, gastroenteritis, parasitic disease, dental disease, vacuolar or endocrine hepatopathy from diabetes mellitus or hyperadrenocorticism (steroid-induced), hypoadrenocorticism, certain drugs (e.g. phenobarbital, corticosteroids, azathioprine, etc.), and muscle ALT (more likely if AST and CK concurrently increased).

It is a good indicator of active liver damage (cell membrane disruption, cellular necrosis), however, if the value is increased by at least 3-4 times normal. Differentials include infectious disease, including Leptospirosis, inflammatory disease (ie. active hepatitis, copper, other), toxic insult as well as infiltrative neoplasia.

ALT levels vary in cases of vascular anomalies such as microvascular dysplasia and portosystemic shunts (PSS) but are often less significantly increased.

- Testing for Leptospirosis could be considered.
- Bile acids could be considered, if tбили is not increased.
- An empirical course of antibiotics and empirical hepatic nutraceuticals may be tried, with monitoring of ALT for improvement. If improvement is noted, antibiotics should be continued until liver enzymes either normalize or plateau (recheck every 2-3 weeks); however, if improvement is not noted and/or enzyme increase progresses, antibiotics should not be continued long term and liver tissue sampling is recommended.
- FNA of the liver can be performed to assess inflammatory cell type, rule in/out round cell neoplasia, etc. (if patient's coagulation status is appropriate).
- If round cell neoplasia is not diagnosed, a liver biopsy (including copper level assessment) may be required to definitively diagnose the underlying hepatopathy.





PATIENT

Luna Bellizzi

SPECIES

Canine

BREED

Heeler Mix

SEX

Spayed Female

AGE

7 Years

WEIGHT

33 Pounds

INTERPRETED BY

Beth Johnson, DVM,
DACVIM (SAIM)

**IMAGING
PERFORMED BY**

Pamela Harrigan, RDCS,
Certified Veterinary
Sonographer (IVUSS)

HOSPITAL NAME

Rhode Island Animal
Medical Center

REFERRING VET

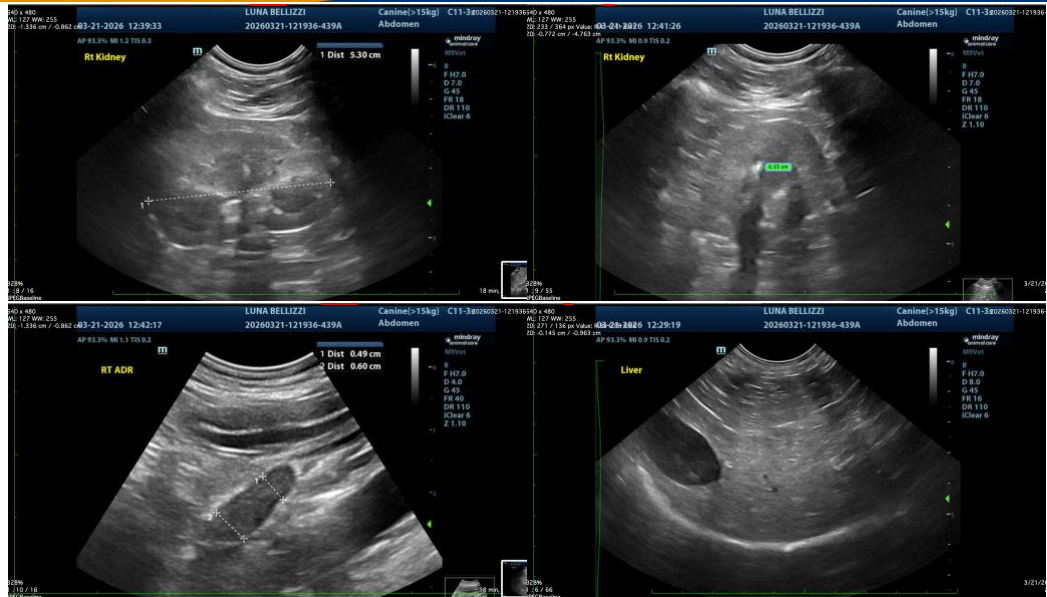
Rachel Rogoff, DVM

INVOICE

36353

DATE

3/23/26



The information and recommendations provided are based on the images presented by the referring veterinarian/sonographer. No evaluation can be communicated regarding pathology that was not visible in the image/video clips provided.

Thank you for this referral. If the clinical or image interpretation does not parallel your findings or if I can be of any further assistance please contact me.

Beth Johnson, DVM DACVIM

info@sonopath.com