



PATIENT

Rory Rutter

SPECIES

Canine

BREED

Mixed

SEX

Spayed Female

AGE

13 Years

WEIGHT

44 Pounds

INTERPRETED BY

Beth Johnson, DVM
DACVIM

IMAGING PERFORMED BY

Dr. Jack Reese

HOSPITAL NAME

Willow Run VC

REFERRING VET

Dr. Jack Reese

INVOICE

46106

DATE

3/22/23

PRESENTING CLINICAL SIGNS

Several week history of decreased appetite, pacing, disorientation at home. Concern for cognitive decline secondary to age - recent bloodwork unremarkable. Owner recently noted P straining to urinate more frequently outside, no obvious blood or change in drinking habits noted. History of splenic nodules noted at referral hospital - owner wishes to pursue U/S to rule out other causes of behavioral and appetite changes at home.

Abnormal PE/Chem/CBC/UA Results: BUN 36 (9 - 31 mg/dL) Labwork otherwise unremarkable
Urinalysis pending

ULTRASONOGRAPHIC EXAMINATION OF THE ABDOMEN

Urinary System

The urinary bladder is only mildly distended/empty. Visible contents are anechoic except for at the level of the trigone entering the proximal urethra, where echogenic shadowing mineral densities are present. Surrounding the mineral, the tissue appears irregular and heterogeneous and thick, so mineralization of a mass is possible. However, given the empty urinary bladder, artifactual thick, irregular wall around a cystolith is also very possible.

Kidneys are overall normal in size and shape with smooth peripheral margination. A normal 1:3 cortex to medulla ratio is maintained. The medulla and cortices are uniform in texture with some mild increased cortical echogenicity and mild loss of corticomedullary distinction, expected in this age patient. There is no evidence of pyelectasia, mineral or infarcts observed. A 3.5 cm x 3.1 cm cortical cyst is noted on the caudal pole of the right kidney. The right kidney measures 7.12 cm. A cyst is noted in the caudal pole of the left kidney measuring 1.0 cm in diameter. The left kidney measures 6.98 cm.

Adrenal Glands

The right adrenal gland is normal in size (1.8 cm at the cranial pole and 0.53 cm at the caudal pole), shape and contour. Corticomedullary structure is unremarkable. Visible surrounding vasculature appears normal.

The left adrenal gland is normal in size (1.0 cm at the cranial pole and 0.74 cm at the caudal pole), shape and contour. Corticomedullary structure is unremarkable. Visible surrounding vasculature appears normal.

Spleen

The spleen is subjectively normal in size with a normal smooth capsular contour. Parenchyma is appropriately finely textured and homogenous with normal echogenicity relative to surrounding tissue (hyperechoic to liver). No focal nodules or masses are observed. Splenic vasculature appears normal.

Liver

The liver is subjectively normal in size with normal smooth curvilinear peripheral contour. Parenchyma is appropriately hypoechoic to the spleen in echogenicity and appropriately mildly coarse and homogenous in echotexture. No focal lesions are observed. Visible vasculature and biliary tree appear normal without distension or congestion.

Gallbladder is moderately distended with anechoic bile as well as moderate suspended and gravity dependent echogenic debris. The wall is smooth without visible thickening. There is no evidence of cystic or CBD dilation. There is no evidence of effusion or inflammation.



PATIENT

Rory Rutter

SPECIES

Canine

BREED

Mixed

SEX

Spayed Female

AGE

13 Years

WEIGHT

44 Pounds

INTERPRETED BY

Beth Johnson, DVM
DACVIM

IMAGING PERFORMED BY

Dr. Jack Reese

HOSPITAL NAME

Willow Run VC

REFERRING VET

Dr. Jack Reese

INVOICE

46106

DATE

3/22/23

Gastrointestinal

The stomach wall is normal in thickness (canine < 0.5 cm and feline < 0.4 cm) and layering. The lumen of the stomach is empty with no evidence of obstruction, foreign material or infiltrative disease. Pyloric outflow tract appears patent.

The visible small intestines are normal in wall thickness and layering (canine duodenum < 0.5 cm and feline duodenum < 0.4 cm; other < 0.3 cm). Small intestinal motility appears adequate (1-3 contractions per min). The lumen of the small intestine is empty with no evidence of obstruction, foreign material or infiltrative disease.

The visible colon is normal in wall thickness (< 0.2 cm) and layering. Contents are consistent with normal formed feces and gas.

Pancreas

The pancreatic parenchyma is appropriately isoechoic to surrounding tissue. Visible capsule is smooth and normal in contour. There is no visible pancreatic duct dilation. There is no evidence of active peripancreatic inflammation.

Free Abdomen

There is no evidence of free peritoneal effusion noted in these images.

There is no apparent lymphadenopathy noted in these images.

PRIMARY FINDINGS

- Mineral within the trigone of the urinary bladder – Mineralized tissue, as could be seen with a mass, versus mineral sand/debris/cystoliths and concurrent cystitis is difficult to try to differentiate in an empty bladder.
- **Moderate gallbladder debris** - Cholelithic debris is of unknown clinical significance. It can be seen with biliary stasis from fasting or illness. Cholelithic debris is not necessarily related to hepatobiliary disease. Echogenic bile is most commonly an incidental finding in dogs and should be interpreted in combination with clinical signs such as nausea, inappetence, cranial abdominal discomfort and/or laboratory changes such as increased ALP and/or increased Tbili.

SECONDARY FINDINGS

- Age related kidney changes with bilateral cortical cysts

INTERPRETATION OF THE FINDINGS & FURTHER RECOMMENDATIONS

Urinalysis and urine culture, if indicated based on urinalysis results, are recommended. Submission of urine to look for BRAF gene mutation, which is associated with urinary bladder cancer, could be considered. Other diagnostic options include traumatic catheterization, fine needle aspirate (with small risk of tumor seeding/trailing) or cystoscopy for further sampling. If traumatic catheterization is elected, then a bladder flush/urohydropropulsion should be considered at the same time to try to retrieve any of the mineral sand debris/small cystoliths that are possible to be retrieved to help analyze and therefore guide medical management.

Additionally, or alternatively to start, recheck of a full urinary bladder would be helpful.



PATIENT

Rory Rutter

SPECIES

Canine

BREED

Mixed

SEX

Spayed Female

AGE

13 Years

WEIGHT

44 Pounds

INTERPRETED BY

Beth Johnson, DVM
DACVIM

IMAGING PERFORMED BY

Dr. Jack Reese

HOSPITAL NAME

Willow Run VC

REFERRING VET

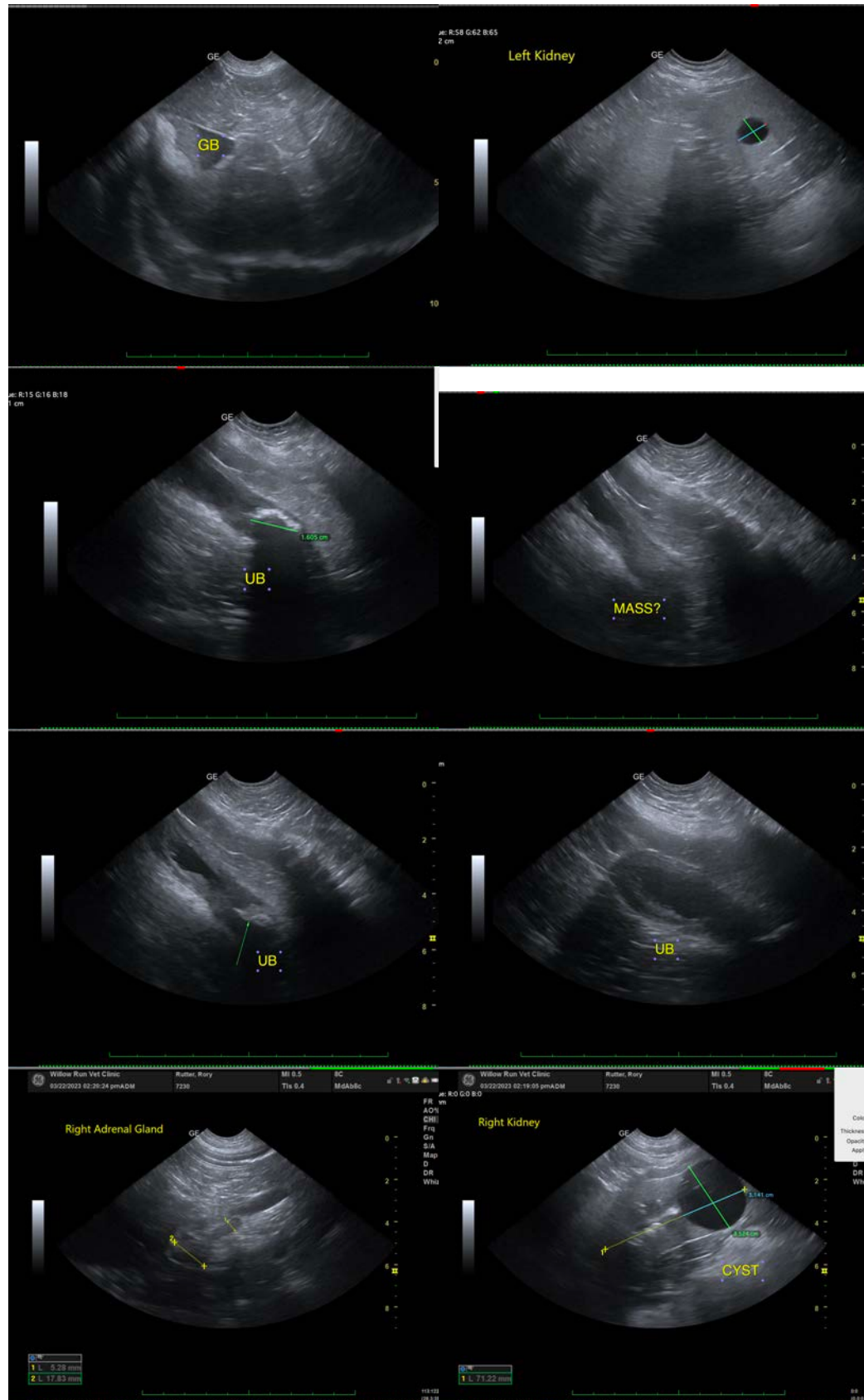
Dr. Jack Reese

INVOICE

46106

DATE

3/22/23





PATIENT

Rory Rutter

SPECIES

Canine

BREED

Mixed

SEX

Spayed Female

AGE

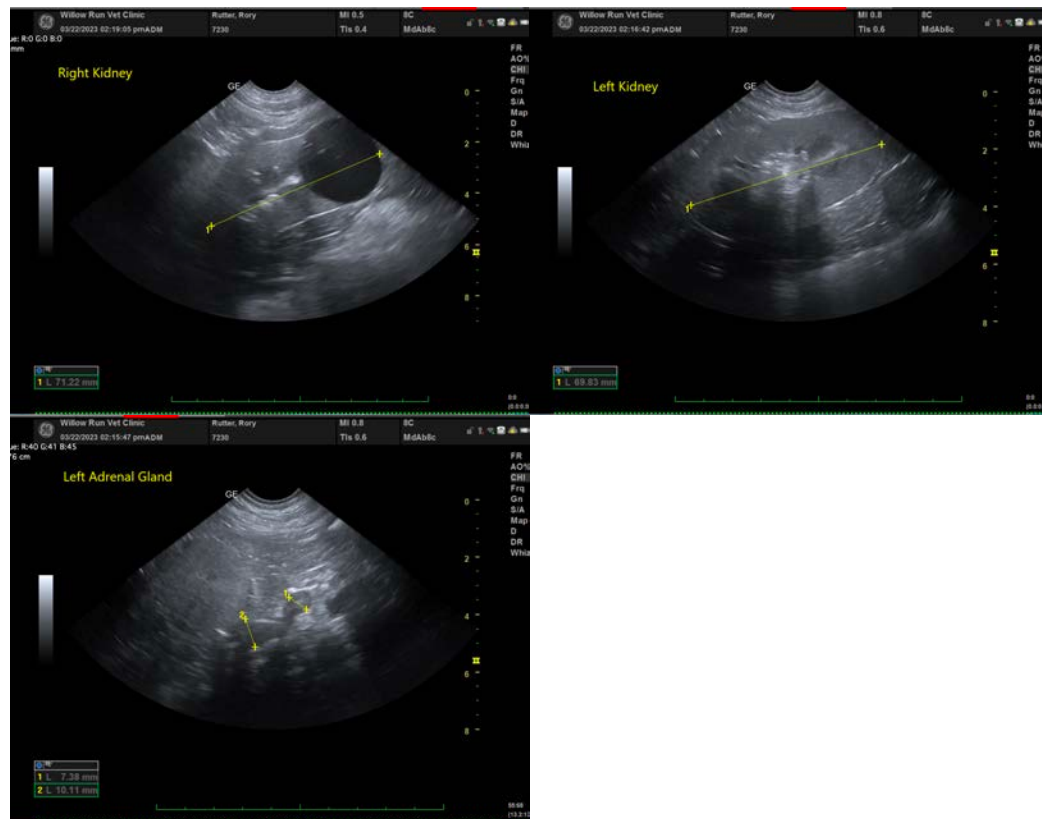
13 Years

WEIGHT

44 Pounds

INTERPRETED BY

Beth Johnson, DVM
DACVIM



IMAGING PERFORMED BY

Dr. Jack Reese

HOSPITAL NAME

Willow Run VC

REFERRING VET

Dr. Jack Reese

INVOICE

46106

DATE

3/22/23

The information and recommendations provided are based on the images presented by the referring veterinarian/sonographer. No evaluation can be communicated regarding pathology that was not visible in the image/video clips provided.

Thank you for this referral. If the clinical or image interpretation does not parallel your findings or if I can be of any further assistance please contact me.

Beth Johnson, DVM, DACVIM
Beth.Johnson@sonopath.com