



PATIENT

Minnie Farris

SPECIES

Canine

BREED

DSH

SEX

Spayed Female

AGE

18

WEIGHT

5.2 Pounds

INTERPRETED BY

Beth Johnson, DVM
DACVIM

IMAGING PERFORMED BY

Dr. Danielle Lanz

HOSPITAL NAME

New Holland VH

REFERRING VET

Dr. Danielle Lanz

INVOICE

46074

DATE

3/22/23

PRESENTING CLINICAL SIGNS

Presenting for weight loss (2lb), ravenous appetite, polydipsia (chronic), vomiting 4-5x weekly. Will walk around crying continually unless eating or sleeping.

Abnormal PE/Chem/CBC/UA Results: Thickened, ropey intestines on palpation Thyroid slip CBC: WNL Chem: BUN 46, Lipase 126, T4 5.1 otherwise WNL

ULTRASONOGRAPHIC EXAMINATION OF THE ABDOMEN

Urinary System

The urinary bladder is moderately distended with anechoic contents. No masses, inflammatory changes, echogenic sediment or cystoliths are observed. The urinary bladder, trigone and visible pelvic urethra are normal in thickness with a smooth mucosal surface.

Kidneys are overall normal in size and shape with smooth peripheral margination. A normal 1:3 cortex to medulla ratio is maintained. The medulla and cortices are uniform in texture with some mild increased cortical echogenicity and mild loss of corticomedullary distinction, expected in this age patient. There is no evidence of pyelectasia, mineral or infarcts observed. The left kidney measures 3.33 cm. The right kidney measures 3.26 cm.

Adrenal Glands

The adrenal glands are unable to be well visualized in these images.

Spleen

Spleen is subjectively normal in size with a normal smooth capsular contour. Parenchyma is appropriately finely textured and homogenous with normal echogenicity relative to surrounding tissue (hyperechoic to liver). Multifocal well-demarcated hyperechoic homogenous nodules are noted. Splenic vasculature appears normal.

Liver

Liver is subjectively enlarged (swollen contour). Mild parenchymal remodeling with diffusely mildly coarse architecture and increased portal markings is present. No focal nodules or masses are observed. Visible vasculature and biliary tree appear normal without distension or congestion.

The gallbladder is non-distended in size. The wall is smooth without visible thickening. Luminal contents are primarily anechoic. There is no evidence of cystic or common bile duct dilation.

Gastrointestinal

The stomach wall is normal in thickness (canine < 0.5 cm and feline < 0.4 cm) and layering. The lumen of the stomach is empty with no evidence of obstruction, foreign material or infiltrative disease. Pyloric outflow tract appears patent.

The visible small intestines are normal in wall thickness and layering (canine duodenum < 0.5 cm and feline duodenum < 0.4 cm; other < 0.3 cm). Small intestinal motility appears adequate (1-3 contractions per min). The lumen of the small intestine is empty with no evidence of obstruction, foreign material or infiltrative disease.

The visible colon is normal in wall thickness (< 0.2 cm) and layering. Contents are consistent with normal formed feces and gas.



PATIENT

Minnie Farris

SPECIES

Canine

BREED

DSH

SEX

Spayed Female

AGE

18

WEIGHT

5.2 Pounds

INTERPRETED BY

Beth Johnson, DVM
DACVIM

IMAGING PERFORMED BY

Dr. Danielle Lanz

HOSPITAL NAME

New Holland VH

REFERRING VET

Dr. Danielle Lanz

INVOICE

46074

DATE

3/22/23

Pancreas

The pancreatic parenchyma is appropriately isoechoic to surrounding tissue. Visible capsule is smooth and normal in contour. There is no visible pancreatic duct dilation. There is no evidence of active peripancreatic inflammation.

Free Abdomen

There is no evidence of free peritoneal effusion noted in these images.

The mesenteric lymph nodes are prominent in size with swollen capsular contour. Normal elongated shape (length to width ratio) is maintained. There is no loss of parenchymal detail.

PRIMARY FINDINGS

- **Hypoechoic hepatomegaly** – This appearance is consistent with an acute hepatopathy or acute cholangiohepatitis. Infiltrative neoplasia (round cell neoplasia) should also be considered.
- **Reactive mesenteric lymph nodes** – infiltrative neoplastic disease cannot be ruled out but is considered less likely.

SECONDARY FINDINGS

- Age related kidney changes
- **Hyperechoic splenic nodules** – most consistent with benign myelolipomas. Other differentials such as fibrosis or calcification caused by old hematomas or infarcts, chronic inflammation, granulomatous disease or metastatic disease cannot be ruled out, but are considered less likely.

INTERPRETATION OF THE FINDINGS & FURTHER RECOMMENDATIONS

If not recently evaluated, a urinalysis and, if indicated based on urinalysis results, urine culture are recommended. If protein is present in an otherwise quiet sediment, protein quantification with a urine protein to creatinine ration is recommended.

Given the new diagnosis of hyperthyroidism, a blood pressure is recommended if not recently evaluated.

Following that, recommendations are to begin medical management of the hyperthyroidism and see if clinical signs improve. If not, next diagnostic steps to consider include:

A gastrointestinal malabsorption panel (including cobalamin, folate, TLI and PLI) to Texas A&M GI Laboratory is recommended for further evaluation of GI and pancreatic function.

A fine needle aspirate of the liver could be considered if patient's coagulation status is appropriate.



PATIENT

Minnie Farris

SPECIES

Canine

BREED

DSH

SEX

Spayed Female

AGE

18

WEIGHT

5.2 Pounds

INTERPRETED BY

Beth Johnson, DVM
DACVIM

IMAGING PERFORMED BY

Dr. Danielle Lanz

HOSPITAL NAME

New Holland VH

REFERRING VET

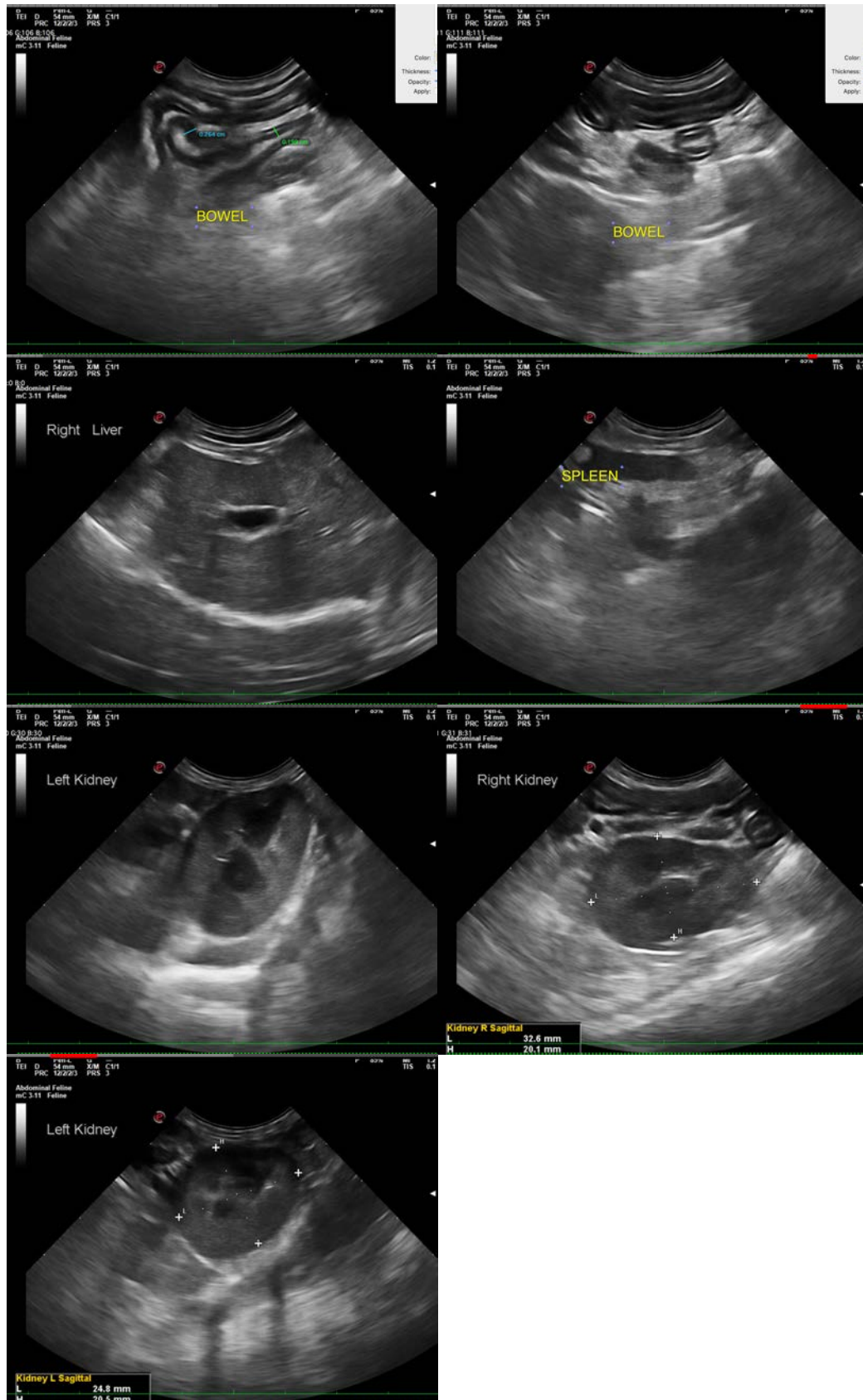
Dr. Danielle Lanz

INVOICE

46074

DATE

3/22/23





PATIENT

Minnie Farris

SPECIES

Canine

BREED

DSH

SEX

Spayed Female

AGE

18

WEIGHT

5.2 Pounds

INTERPRETED BY

Beth Johnson, DVM
DACVIM

**IMAGING
PERFORMED BY**

Dr. Danielle Lanz

HOSPITAL NAME

New Holland VH

REFERRING VET

Dr. Danielle Lanz

INVOICE

46074

DATE

3/22/23

The information and recommendations provided are based on the images presented by the referring veterinarian/sonographer. No evaluation can be communicated regarding pathology that was not visible in the image/video clips provided.

Thank you for this referral. If the clinical or image interpretation does not parallel your findings or if I can be of any further assistance please contact me.

Beth Johnson, DVM, DACVIM
Beth.Johnson@sonopath.com