

**DATE PRESENTING CLINICAL SIGNS**

3/22/23

For the last couple days O has noted a malodor from pt's hind end. O states that last time this occurred pt had a UTI (Dec 6, 2022), however this time pt is not exhibiting symptoms of a UTI (She is urinating normally, not having accidents, drinking a normal amount). E/D normally no V/D/C/S noted.

PATIENT

Maddie Herring

Current Medications: None current.
Lab Results: See attached.

SPECIES

Canine

Radiographs: mild/mod splenomegaly w/ radiopaque circumscribed density at caudal pole on R lat view; several metallic densities in sq; radiopaque "sludge" cranioventral bladder?; intestines appear bunched along w/ colon but colon has normal amt of feces and does not appear obstructive; loss of contrast cranioventral abd (xs adipose?); partial view of thorax appears clear; mild spondylosis noted thoracolumbar.

BREED

Australian
Shepherd/Great
Pyrenees

Date of Previous IntraPet Ultrasound: No previous.
Sedation: Not required to complete full diagnostic ultrasound.
Stat Report: Not requested.

Imaging Performed By: Stephanie Warga RDCS, RVT.

SEX

Spayed Female

Urinary System

Urinary bladder is adequately distended. It has a normal uniform wall thickness. Contents include primarily anechoic fluid with a large amount of echogenic non-shadowing debris as well as mineral/sand debris, most consistent with exfoliated cells, mucous and/or small blood clots, crystals, etc. Both sterile inflammation as well as urinary tract infection can also present with echogenic debris. No masses or cystoliths are observed. The trigone and visible pelvic urethra are normal in thickness with a smooth mucosal surface.

AGE

2/17/09

WEIGHT

97 Pounds

The right kidney is normal in size (6.97 cm), shape and echogenicity. It has smooth peripheral margination. There is a normal 1:3 cortex to medulla ratio with appropriate corticomedullary distinction. There is no evidence of pyelectasia or infarcts observed. Punctate non-obstructive nephroliths noted.

INTERPRETED BY

Beth Johnson, DVM
DACVIM

The left kidney is normal in size (6.4 cm), shape and echogenicity. It has smooth peripheral margination. There is a normal 1:3 cortex to medulla ratio with appropriate corticomedullary distinction. There is no evidence of pyelectasia or infarcts observed. Punctate non-obstructive nephroliths noted.

HOSPITAL NAME

Eldersburg Vet

Adrenal Glands

The right adrenal gland is normal in size (2.38 cm long x 0.77 cm at the cranial pole and 0.64 cm at the caudal pole), shape and contour. Corticomedullary structure is unremarkable. Visible surrounding vasculature appears normal.

REFERRING VET

Dr. James

The left adrenal gland is normal in size (2.01 cm long x 0.63 cm at the cranial pole and 0.64 cm at the caudal pole), shape and contour. Corticomedullary structure is unremarkable. Visible surrounding vasculature appears normal.

INVOICE

46086

Spleen

The spleen is subjectively normal in size with a normal smooth capsular contour. Parenchyma is appropriately finely textured and homogenous with normal echogenicity relative to surrounding tissue (hyperechoic to liver). A 2.0 cm x 2.3 cm mildly heterogeneous but primarily solid iso- to slightly hypoechoic nodule is noted near the tail of the spleen that results in a mild capsular bulge. Splenic vasculature appears normal.

Liver

The liver is subjectively normal in size with normal smooth curvilinear peripheral contour. Parenchyma is appropriately hypoechoic to the spleen in echogenicity and appropriately mildly coarse and homogenous in

echotexture. No focal lesions are observed. Visible vasculature and biliary tree appear normal without distension or congestion.

The gallbladder is non-distended in size. The wall is smooth without visible thickening. Luminal contents are primarily anechoic. There is no evidence of cystic or common bile duct dilation.

Gastrointestinal

The visible stomach wall is normal in thickness and layering. The lumen of the stomach is mildly distended with echogenic non-shadowing luminal contents and gas consistent with normal ingesta. There is no evidence of obstruction, foreign material or infiltrative disease. Pyloric outflow tract appears patent.

The visible small intestines are normal in wall thickness and layering. Small intestinal motility appears adequate (1-3 contractions per min). The lumen of the small intestine is mildly distended with echogenic non-shadowing luminal contents and gas consistent with normal ingesta. There is no evidence of obstruction, foreign material or infiltrative disease.

The visible colon is normal in wall thickness (< 0.2 cm) and layering. Contents are consistent with normal formed feces and gas.

Pancreas

The pancreatic parenchyma is appropriately isoechoic to surrounding tissue. Visible capsule is smooth and normal in contour. There is no visible pancreatic duct dilation. There is no evidence of active peripancreatic inflammation.

Free Abdomen

There is no evidence of free peritoneal effusion noted in these images.

There is no apparent lymphadenopathy noted in these images.

There is no evidence of heart base or pericardial pathology noted in these images at this time. If cardiac function evaluation is desired a full echocardiogram is recommended.

ULTRASONOGRAPHIC FINDINGS

- Non-cavitated splenic nodule – may represent a benign lesion such as nodular hyperplasia, extramedullary hematopoiesis, etc. However, infiltrative neoplasia can mimic benign lesions (i.e., round cell neoplasia versus sarcoma versus other) and cannot be ruled out.
- Large amount of urinary bladder debris
- Non-obstructive punctate bilateral nephroliths

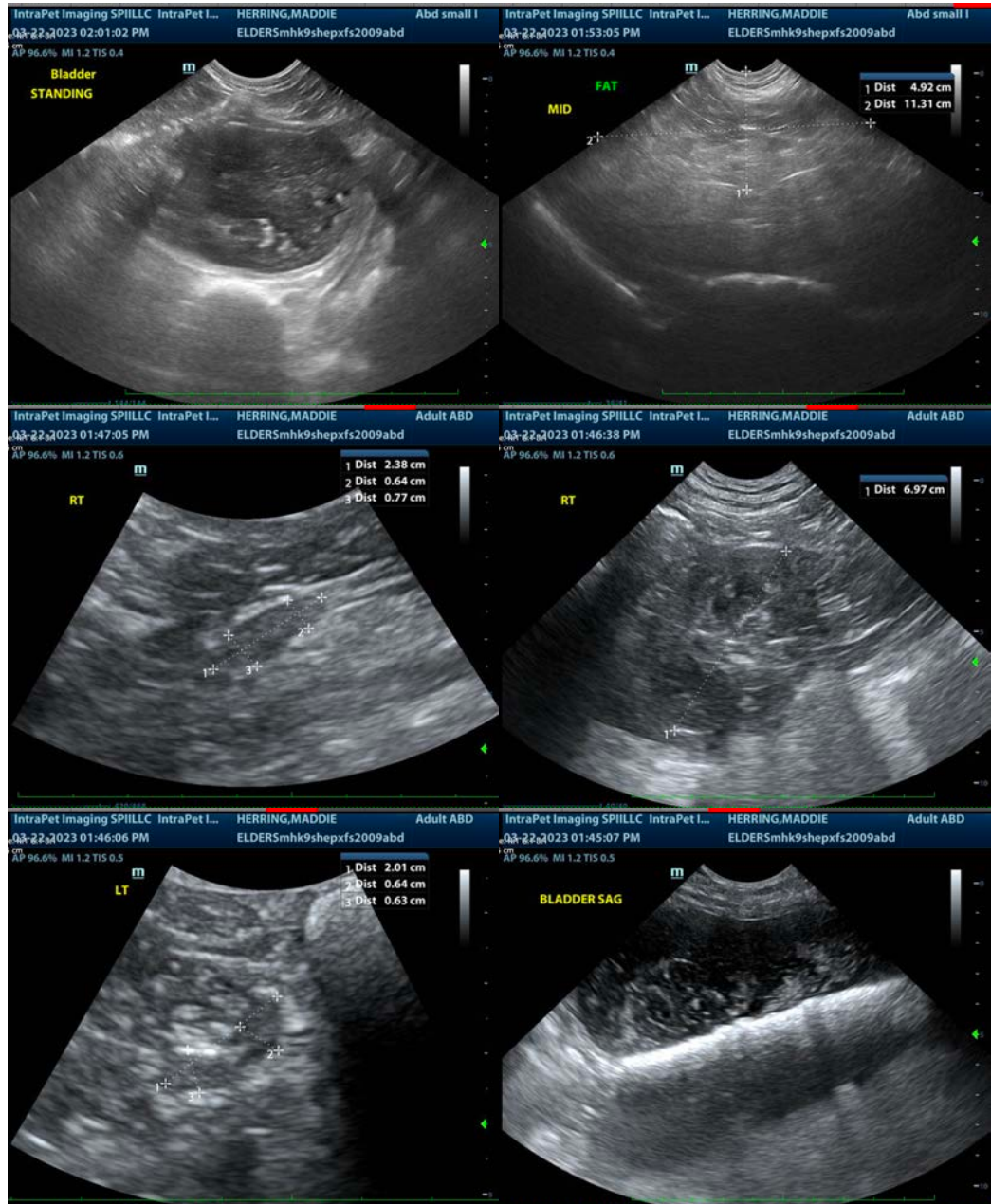
INTERPRETATION OF THE FINDINGS & FURTHER RECOMMENDATIONS

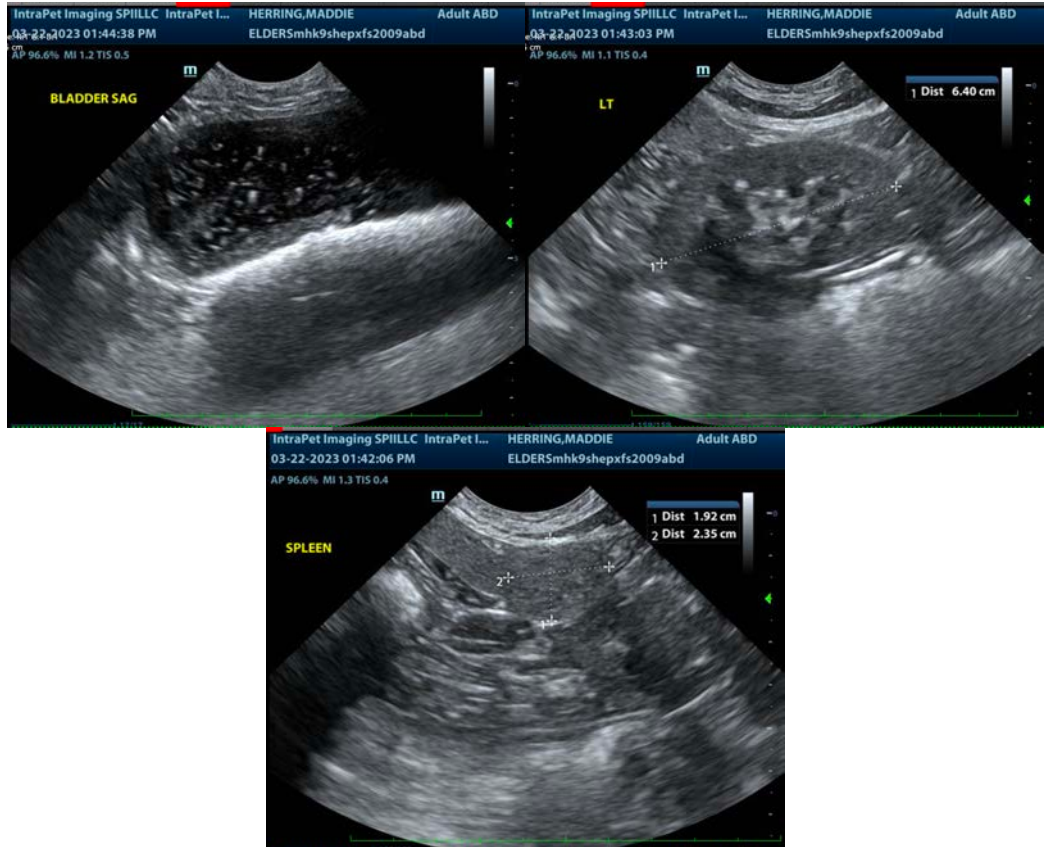
Several urinalyses were provided with this patient history. However, CBC/Chem panel and electrolytes were not viewed. Therefore, if not recently evaluated, a general metabolic health screen is recommended in the form of a CBC/Chem panel and electrolytes.

A urine culture is recommended to help guide therapy of the suspected urinary tract infection.

Three view thoracic radiographs are recommended for further assessment of cardio-pulmonary status as well as to further evaluate for any evidence of metastatic disease, if not recently evaluated.

A fine needle aspirate of the splenic nodule could be considered if patient's coagulation status is appropriate.





The information and recommendations provided are based on the images presented by the referring veterinarian/sonographer. No evaluation can be communicated regarding pathology that was not visible in the image/video clips provided.

Thank you for this referral. If the clinical or image interpretation does not parallel your findings or if I can be of any further assistance please contact me.

Beth Johnson, DVM, DACVIM
Beth.Johnson@sonopath.com