



PATIENT PRESENTING CLINICAL SIGNS

Bud Bryson Weight loss despite a good appetite and lethargy over the last 2 to 3 months.

SPECIES Abnormal PE/Chem/CBC/UA Results: ABNORMAL Laboratory Findings No real abnormalities on CBC, Chemistry, lytes or UA Current Medications bravecto Radiographic Findings Splenomegaly, hepatomegaly with rounded edges
Canine

BREED ULTRASONOGRAPHIC EXAMINATION OF THE ABDOMEN

Labrador Retriever **Urinary System**

SEX The urinary bladder is moderately distended with anechoic contents. No masses, inflammatory changes, echogenic sediment or cystoliths are observed. The urinary bladder, trigone and visible pelvic urethra are normal in thickness with a smooth mucosal surface.

Neutered Male

Prostate is normal in size, echotexture and echogenicity for a neutered male.

AGE

8 Years

The right kidney is normal in size (7.3 cm), shape and echogenicity. It has smooth peripheral margination. There is a normal 1:3 cortex to medulla ratio with appropriate corticomedullary distinction. There is no evidence of pyelectasia, mineral or infarcts observed.

WEIGHT

78 Pounds

The left kidney is normal in size (6.58 cm), shape and echogenicity. It has smooth peripheral margination. There is a normal 1:3 cortex to medulla ratio with appropriate corticomedullary distinction. There is no evidence of pyelectasia, mineral or infarcts observed.

INTERPRETED BY

Beth Johnson, DVM
DACVIM

Adrenal Glands

The right adrenal gland is normal in size (2.94 cm long x 1.34 cm at the cranial pole and 0.71 cm at the caudal pole), shape and contour. Corticomedullary structure is unremarkable. Visible surrounding vasculature appears normal.

IMAGING PERFORMED BY

Sara Hansen

The left adrenal gland is normal in size (3.1 cm long x 0.73 cm at the cranial pole and 0.75 cm at the caudal pole), shape and contour. Corticomedullary structure is unremarkable. Visible surrounding vasculature appears normal.

Spleen

HOSPITAL NAME

South Willamette VC

The spleen is subjectively normal in size with a normal smooth capsular contour. Parenchyma is appropriately finely textured and homogenous with normal echogenicity relative to surrounding tissue (hyperechoic to liver). No focal nodules or masses are observed. Splenic vasculature appears normal.

REFERRING VET

Dr. Shelton

Liver

The liver is subjectively normal in size with normal smooth curvilinear peripheral contour. Parenchyma is appropriately hypoechoic to the spleen in echogenicity and appropriately mildly coarse and homogenous in echotexture. No focal lesions are observed. Visible vasculature and biliary tree appear normal without distension or congestion.

INVOICE

46116

The gallbladder is non-distended in size. The wall is smooth without visible thickening. Luminal contents are primarily anechoic. There is no evidence of cystic or common bile duct dilation.

DATE

3/22/23



PATIENT

Gastrointestinal

Bud Bryson

The visible stomach wall is normal in thickness and layering. The lumen of the stomach is mildly distended with very echogenic reverberation artifact from intraluminal gas. There is no evidence of obstruction, foreign material or infiltrative disease; however, complete visualization of far wall is partially inhibited by gas. Pyloric outflow tract appears patent.

SPECIES

Canine

BREED

Labrador Retriever

The visible small intestines are normal in wall thickness and layering. Subtle hyperechoic mucosal fogging or speckling is noted. Small intestinal motility appears adequate (1-3 contractions per min). The lumen is empty with no evidence of obstruction or foreign material.

SEX

The visible colon is normal in wall thickness (< 0.2 cm) and layering. Contents are consistent with normal formed feces and gas.

Neutered Male

AGE

8 Years

Pancreas

The pancreatic parenchyma is appropriately isoechoic to surrounding tissue. Visible capsule is smooth and normal in contour. There is no visible pancreatic duct dilation. There is no evidence of active peripancreatic inflammation.

WEIGHT

78 Pounds

Free Abdomen

There is no evidence of free peritoneal effusion noted in these images.

There is no apparent lymphadenopathy noted in these images.

INTERPRETED BY

Beth Johnson, DVM
DACVIM

ULTRASONOGRAPHIC FINDINGS

- **Subtle mucosal speckling** – Mucosal speckling is often present with inflammatory bowel disease (IBD). It is not specific for type or severity of disease. Mild speckling change can occur as a normal patient variant in the post-prandial state.

IMAGING PERFORMED BY

Sara Hansen

INTERPRETATION OF THE FINDINGS & FURTHER RECOMMENDATIONS

A gastrointestinal malabsorption panel (including cobalamin, folate, TLI and PLI) to Texas A&M GI Laboratory is recommended for further evaluation of GI and pancreatic function.

HOSPITAL NAME

South Willamette VC

While awaiting results, close evaluation/calculation of patient's daily caloric intake is recommended to ensure there hasn't been an inadvertent decrease in calories caused by a diet change or feeding competition in the house, etc.

REFERRING VET

Dr. Shelton

Empirical deworming with a 5-day course of Panacur is also recommended, as is, if tolerated, potentially transition in diet, beginning with a hydrolyzed protein diet. Some patients respond better to one brand or variety of hydrolyzed protein diet versus another, so sometimes several trials are necessary.

INVOICE

46116

DATE

3/22/23



PATIENT

Bud Bryson

SPECIES

Canine

BREED

Labrador Retriever

SEX

Neutered Male

AGE

8 Years

WEIGHT

78 Pounds

INTERPRETED BY

Beth Johnson, DVM
DACVIM

IMAGING PERFORMED BY

Sara Hansen

HOSPITAL NAME

South Willamette VC

REFERRING VET

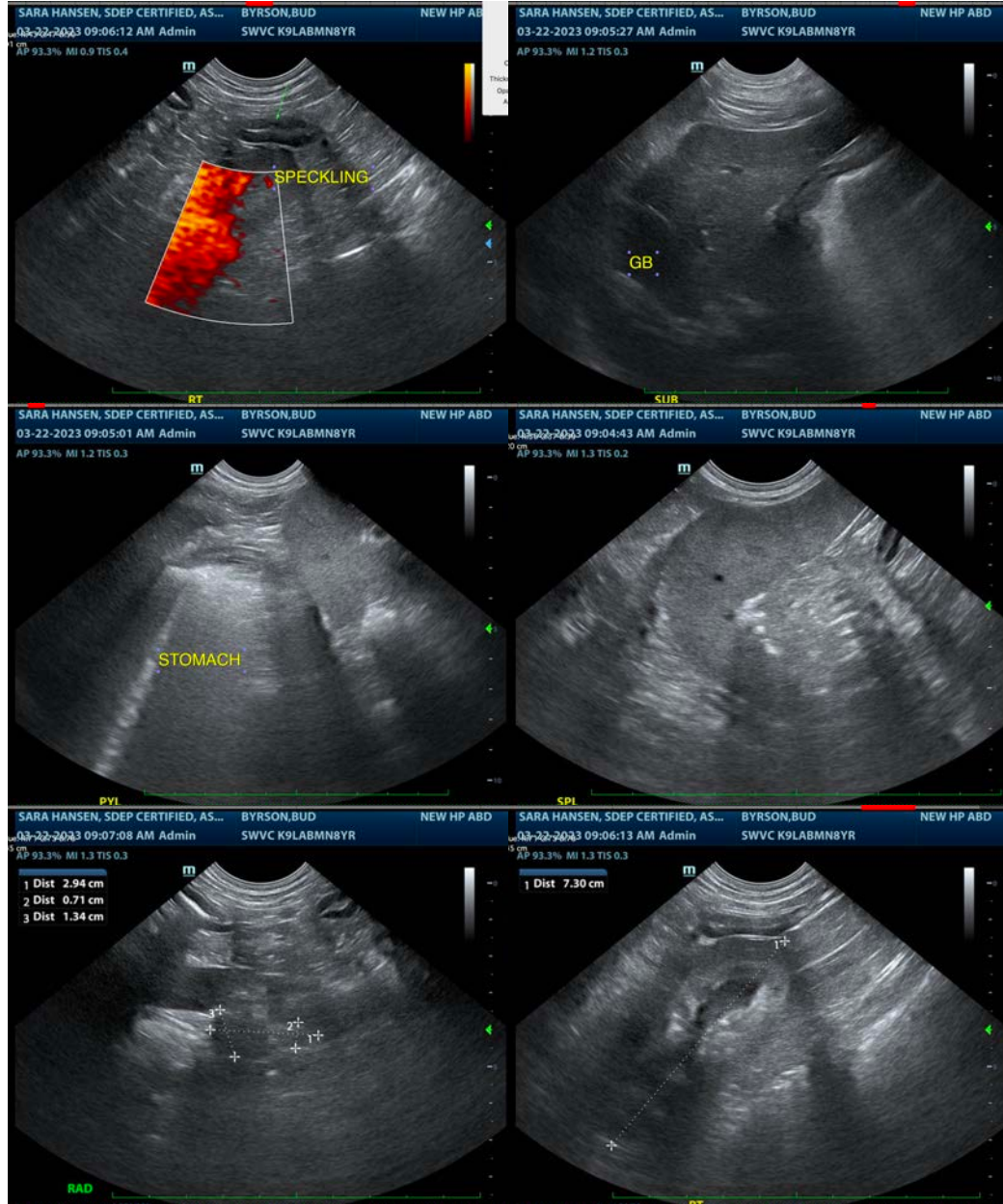
Dr. Shelton

INVOICE

46116

DATE

3/22/23





PATIENT

Bud Bryson

SPECIES

Canine

BREED

Labrador Retriever

SEX

Neutered Male

AGE

8 Years

WEIGHT

78 Pounds

INTERPRETED BY

Beth Johnson, DVM
DACVIM

IMAGING PERFORMED BY

Sara Hansen

HOSPITAL NAME

South Willamette VC

REFERRING VET

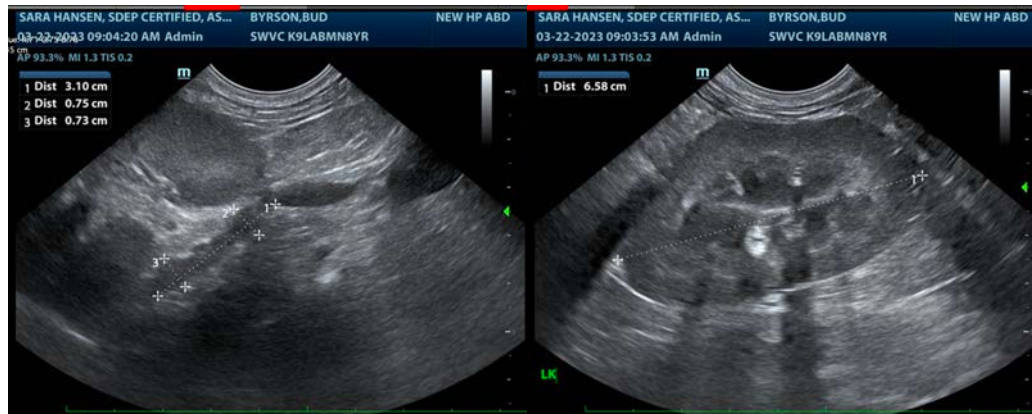
Dr. Shelton

INVOICE

46116

DATE

3/22/23



The information and recommendations provided are based on the images presented by the referring veterinarian/sonographer. No evaluation can be communicated regarding pathology that was not visible in the image/video clips provided.

Thank you for this referral. If the clinical or image interpretation does not parallel your findings or if I can be of any further assistance please contact me.

Beth Johnson, DVM, DACVIM
Beth.Johnson@sonopath.com