



PATIENT

Rexi Dattolico

SPECIES

Canine

BREED

Pug X

SEX

Neutered Male

AGE

12 Years

WEIGHT

22 Pounds

INTERPRETED BY

Beth Johnson, DVM
DACVIM

IMAGING PERFORMED BY

Dr. Elaina Petrone

HOSPITAL NAME

Long Branch AH

REFERRING VET

Dr. Elaina Petrone

INVOICE

46035

DATE

3/21/23

PRESENTING CLINICAL SIGNS

Recheck bladder scan for luminal masses and hematuria, see previous report.

LIMITED ULTRASONOGRAPHIC EXAMINATION

Urinary bladder is adequately distended with primarily anechoic contents and occasional echogenic non-shadowing debris. Mucosa is diffusely hyperechoic and irregular with multiple pedunculated masses extending into the lumen of the bladder. No cystoliths are observed. The trigone and visible pelvic urethra are normal thickness with a smooth mucosal surface.

Prostate is normal in size, echotexture and echogenicity for a neutered male.

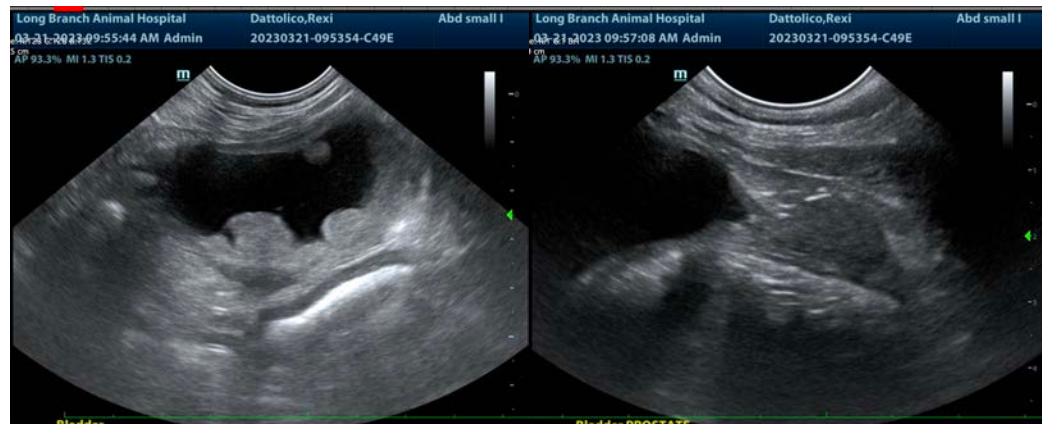
ULTRASONOGRAPHIC FINDINGS

- **Polypoid Cystitis** – Urinary bladder wall changes are most consistent with polypoid cystitis. Infiltrative neoplasia cannot be ruled out but is considered less likely given the appearance of the polyps. The appearance and number of the polyp like lesions have progressed/increased since last year’s ultrasound. Progression can occur however with benign and/or infiltrative neoplastic disease.

INTERPRETATION OF THE FINDINGS & FURTHER RECOMMENDATIONS

Three view thoracic radiographs are recommended for further assessment of cardio-pulmonary status as well as to further evaluate for any evidence of metastatic disease, if not recently evaluated.

As is reportedly already pending, urinalysis and urine culture, if indicated based on urinalysis results, are recommended. Submission of urine to look for BRAF gene mutation, which is associated with urinary bladder cancer, could be considered. Other diagnostic options include traumatic catheterization, fine needle aspirate (with small risk of tumor seeding/trailing) or cystoscopy for further sampling.





PATIENT

Rexi Dattolico

SPECIES

Canine

BREED

Pug X

SEX

Neutered Male

AGE

12 Years

WEIGHT

22 Pounds

INTERPRETED BY

Beth Johnson, DVM
DACVIM

IMAGING PERFORMED BY

Dr. Elaina Petrone

HOSPITAL NAME

Long Branch AH

REFERRING VET

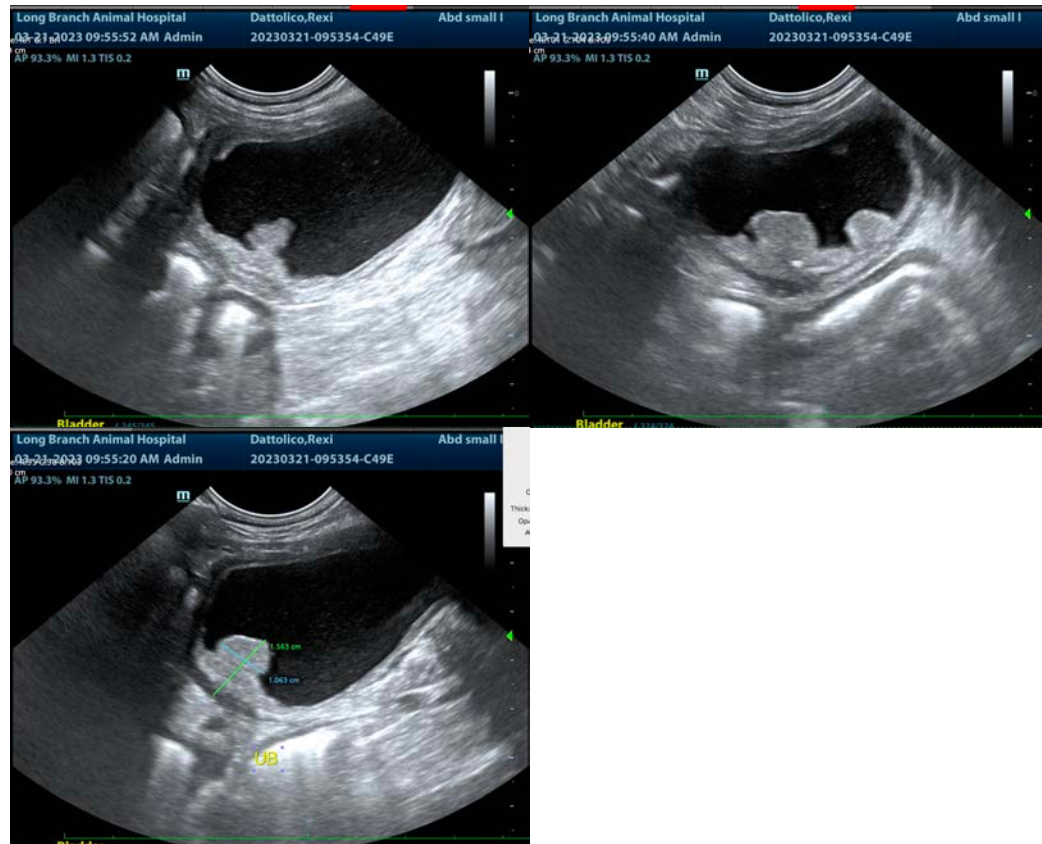
Dr. Elaina Petrone

INVOICE

46035

DATE

3/21/23



The information and recommendations provided are based on the images presented by the referring veterinarian/sonographer. No evaluation can be communicated regarding pathology that was not visible in the image/video clips provided.

Thank you for this referral. If the clinical or image interpretation does not parallel your findings or if I can be of any further assistance please contact me.

Beth Johnson, DVM, DACVIM
Beth.Johnson@sonopath.com