



PATIENT

Gator Lambert

SPECIES

Canine

BREED

Dutch Shepherd

SEX

Neutered Male

AGE

8 Years

WEIGHT

76 Pounds

INTERPRETED BY

Beth Johnson, DVM
DACVIM

IMAGING PERFORMED BY

Dr. Harasimowicz

HOSPITAL NAME

Waterbury Vet
Hospital

REFERRING VET

Dr. Harasimowicz

INVOICE

46046

DATE

3/21/23

PRESENTING CLINICAL SIGNS

Adopted recently (6/2022) and was told that p had renal disease and hypothyroidism. P was on thyroxine. BW showed elevated creatinine of 2.4 with USG of 1.008, 2+ protein in urine. Owner declined BP and urine culture at that time, but started k/d diet and decreased thyroxine. O did not follow up initially and stopped giving k/d diet. Recheck BW in December 2022 showed mild worsening of renal values with creatinine of 3.4 with USG of 1.010. P was proteinuric at 2.1, but otherwise quiet sediment. T4 WNL at 2.2. P was feeling well at this time. Owner again declined BP and urine culture, but planned to restart renal diet and recheck BW in 1-2 months. O had exam yesterday for decreased appetite and weight loss. P has lost 15 pounds over the last few months. Occasional vomiting and loose stool. Lethargic and drinking/urinating less. Owner reports that he initially liked his k/d diet but then stopped wanting to eat it. She is now feeding Fresh Pet but he will only eat about 1/2 of recommended amount. Recheck BW yesterday showed dramatic worsening of renal values (see below). P was dropped off this morning for BP, IV fluids/treatments and abdominal ultrasound. Golf ball sized left-sided anal sac mass was palpable on rectal exam.

Abnormal PE/Chem/CBC/UA Results: 3/20/23: CBC WNL Chem: SDMA - 53, Crea - 15.6, BUN - 172, Ph - 19.1, Cl - 106, Bicarb - 11, Amylase - 2068, Liver values all WNL UA: USG - 1.011, pH of 5.5, 1+ protein, quiet sediment otherwise T4: 2.6 BP today was WNL: 112 mmHg via doppler on hind leg. Collected urine and submitted urine culture today.

ULTRASONOGRAPHIC EXAMINATION OF THE ABDOMEN

Urinary System

Urinary bladder is adequately distended. It has a normal uniform wall thickness. Contents include primarily anechoic fluid with occasional echogenic non-shadowing debris, most consistent with exfoliated cells, mucous and/or small blood clots. Both sterile inflammation as well as urinary tract infection can also present with echogenic debris. No masses or cystoliths are observed. The trigone and visible pelvic urethra are normal in thickness with a smooth mucosal surface.

Prostate is normal in size, echotexture and echogenicity for a neutered male.

Kidneys are normal in size and contour. A relatively uniform hyperechogenicity is observed with mildly decreased corticomedullary distinction. There is no pyelectasia noted and no mineral is observed. No overt masses/nodules are observed. The left kidney measures 7.01 cm. The right kidney measures 7.27 cm.

Adrenal Glands

The area of the adrenal glands is examined without evident adrenal gland pathology.

Spleen

Spleen is subjectively large in size with a mildly swollen but smooth capsule. Parenchyma is normal and homogenous in echogenicity and echotexture. An approximately 1.0 cm in diameter non-capsule disrupting hypo- to anechoic nodule is noted in the mid spleen. Splenic vasculature appears normal.

Liver

The liver is subjectively normal in size with normal smooth curvilinear peripheral contour. Parenchyma is appropriately hypoechoic to the spleen in echogenicity and appropriately mildly coarse and homogenous in echotexture. No focal lesions are observed. Visible vasculature and biliary tree appear normal without distension or congestion.



PATIENT

Gator Lambert

The gallbladder is non-distended in size. The wall is smooth without visible thickening. Luminal contents are primarily anechoic. There is no evidence of cystic or common bile duct dilation.

SPECIES

Canine

Gastrointestinal

The stomach wall is normal in thickness (canine < 0.5 cm and feline < 0.4 cm) and layering. The lumen of the stomach is empty with no evidence of obstruction, foreign material or infiltrative disease. Pyloric outflow tract appears patent.

BREED

Dutch Shepherd

The visible small intestines are normal in wall thickness and layering (canine duodenum < 0.5 cm and feline duodenum < 0.4 cm; other < 0.3 cm). Small intestinal motility appears adequate (1-3 contractions per min). The lumen of the small intestine is empty with no evidence of obstruction, foreign material or infiltrative disease.

SEX

Neutered Male

The visible colon is normal in wall thickness (< 0.2 cm) and layering. Contents are consistent with normal formed feces and gas.

AGE

8 Years

Pancreas

The pancreatic parenchyma is appropriately isoechoic to surrounding tissue. Visible capsule is smooth and normal in contour. There is no visible pancreatic duct dilation. There is no evidence of active peripancreatic inflammation.

WEIGHT

76 Pounds

Free Abdomen

INTERPRETED BY

Beth Johnson, DVM
DACVIM

There is no evidence of free peritoneal effusion noted in these images.

Sublumbar lymph nodes are enlarged with swollen irregular capsular contour and loss of normal length to width ratio (rounded in shape). Nodes are hypoechoic with loss of normal parenchymal detail.

PRIMARY FINDINGS

IMAGING PERFORMED BY

Dr. Harasimowicz

- **Nephritis** – This appearance can be consistent with chronic interstitial nephritis or glomerulonephritis. Toxic insult and/or infectious disease (pyelonephritis, Leptospirosis, etc.) cannot be ruled out. This finding should be interpreted in combination with suspicion for renal disease and/or supporting laboratory or urinalysis changes.

HOSPITAL NAME

Waterbury Vet
Hospital

- **Hypersplenism** – can be associated with congestion caused by sedation (if sedated) but can also be associated with diffuse infiltrative disease. Both benign conditions such as extramedullary hematopoiesis, lymphoid hyperplasia, as well as infiltrative neoplastic diseases such as round cell neoplasia should be considered.

REFERRING VET

Dr. Harasimowicz

- **Hypo to anechoic splenic nodule** – likely represents a benign lesion such as a cyst, hematoma, nodular hyperplasia, extramedullary hematopoiesis, etc., however while considered less likely, infiltrative neoplasia can mimic benign lesions, and cannot be ruled out.

INVOICE

46046

- **Aggressive sublumbar lymph nodes** – most consistent with infiltrative round cell or metastatic neoplasia. A benign aggressive inflammatory response cannot be ruled out without tissue sampling +/- culture.

DATE

3/21/23

SECONDARY FINDINGS

- Urinary bladder debris



PATIENT

Gator Lambert

SPECIES

Canine

BREED

Dutch Shepherd

SEX

Neutered Male

AGE

8 Years

WEIGHT

76 Pounds

INTERPRETED BY

Beth Johnson, DVM
DACVIM

IMAGING PERFORMED BY

Dr. Harasimowicz

HOSPITAL NAME

Waterbury Vet
Hospital

REFERRING VET

Dr. Harasimowicz

INVOICE

46046

DATE

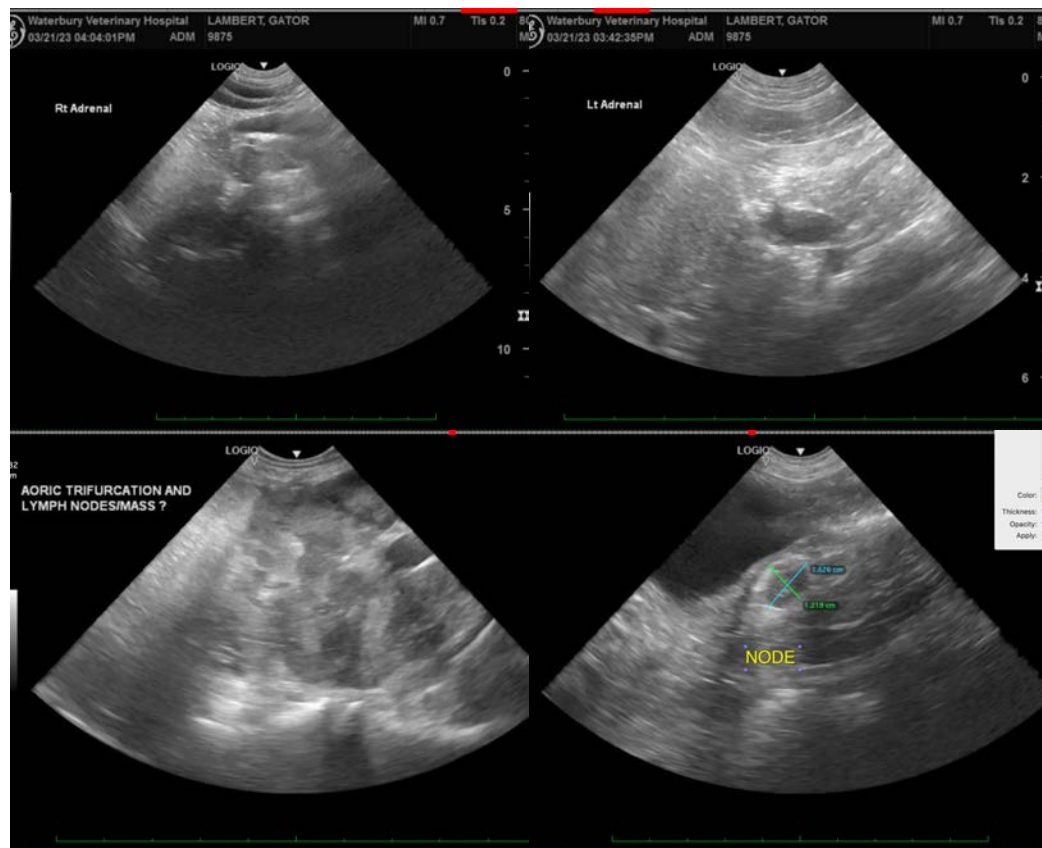
3/21/23

INTERPRETATION OF THE FINDINGS & FURTHER RECOMMENDATIONS

Given this patient's reported kidney disease, as is reportedly already pending, a urine culture is recommended. If the culture is negative and sediment otherwise quiet except for proteinuria, then a urine protein to creatinine ratio would be recommended to help determine whether therapy for proteinuria is warranted, especially given this patient's reported weight loss.

Additionally, comprehensive infectious disease testing based on geographically appropriate infectious disease but including testing for Leptospirosis could be considered, as the kidney disease may or may not be related to the sublumbar lymphadenopathy. Having said that, the sublumbar lymphadenopathy is very concerning for infiltrative neoplasia/metastatic neoplasia, and should ideally be worked up first, beginning with a thorough rectal and perianal exam if not recently evaluated, followed by fine needle aspirates of the enlarged lymph nodes if patient's coagulation status is appropriate.

Three view thoracic radiographs are recommended for further assessment of cardio-pulmonary status as well as to further evaluate for any evidence of metastatic disease, if not recently evaluated.





PATIENT

Gator Lambert

SPECIES

Canine

BREED

Dutch Shepherd

SEX

Neutered Male

AGE

8 Years

WEIGHT

76 Pounds

INTERPRETED BY

Beth Johnson, DVM
DACVIM

IMAGING PERFORMED BY

Dr. Harasimowicz

HOSPITAL NAME

Waterbury Vet
Hospital

REFERRING VET

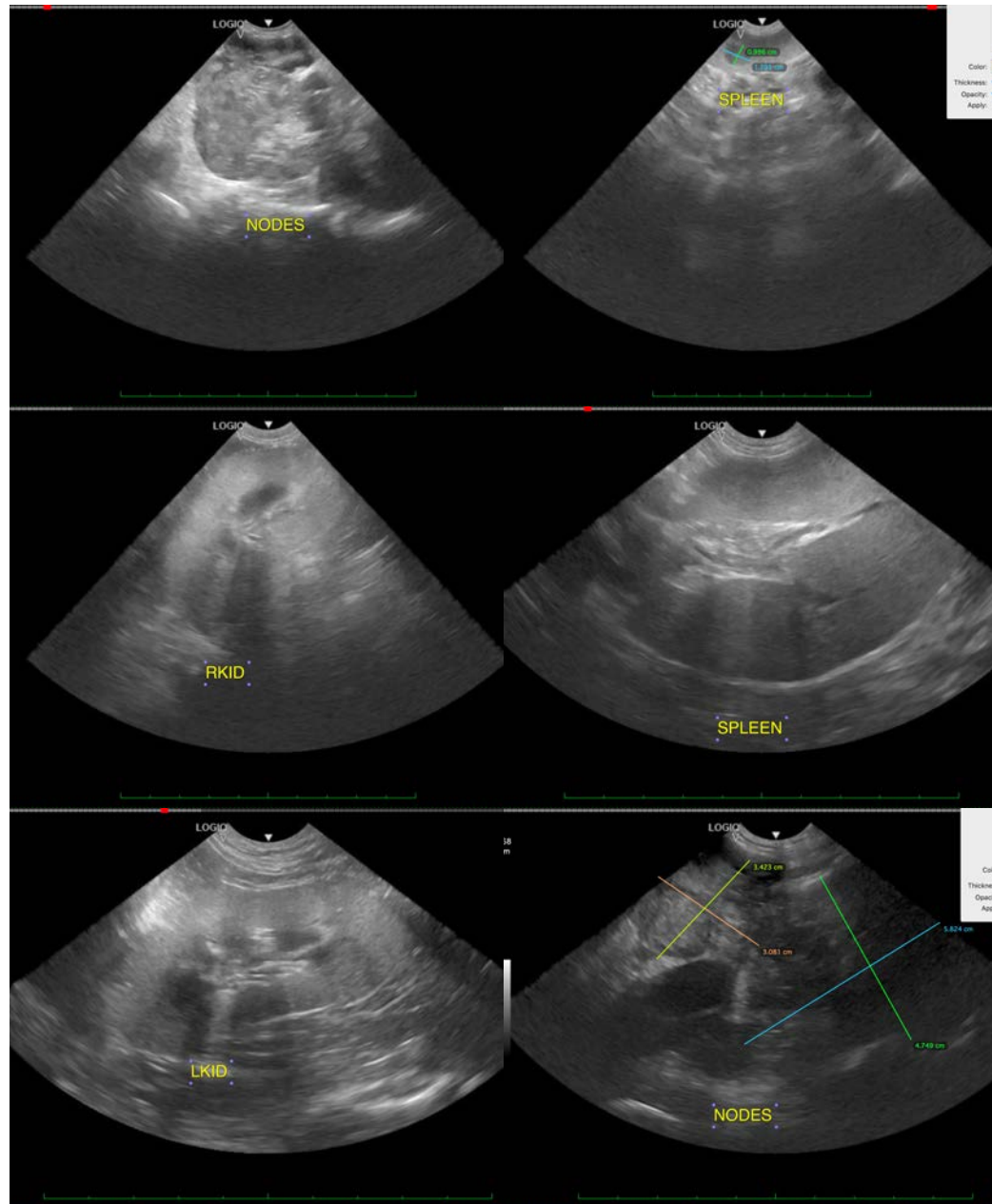
Dr. Harasimowicz

INVOICE

46046

DATE

3/21/23



The information and recommendations provided are based on the images presented by the referring veterinarian/sonographer. No evaluation can be communicated regarding pathology that was not visible in the image/video clips provided.

Thank you for this referral. If the clinical or image interpretation does not parallel your findings or if I can be of any further assistance please contact me.

Beth Johnson, DVM, DACVIM
Beth.Johnson@sonopath.com