



**PATIENT**

Basil Miller

**SPECIES**

Feline

**BREED**

DSH

**SEX**

Spayed Female

**AGE**

1 Year

**WEIGHT**

6.7 Pounds

**INTERPRETED BY**

Beth Johnson, DVM  
DACVIM

**IMAGING PERFORMED BY**

Dr. Danielle Lanz

**HOSPITAL NAME**

New Holland VH

**REFERRING VET**

Dr. Danielle Lanz

**INVOICE**

46058

**DATE**

3/21/23

**PRESENTING CLINICAL SIGNS**

Intermittent vomiting (once weekly). Typically undigested food, no correlation with time of eating. No diarrhea. Hyporexia. No improvement on laxotone and famotidine.

Abnormal PE/Chem/CBC/UA Results: FeLV/FIV: negative Fecal: negative CBC: RBC 6.58 (L), Neutrophils 1.947 (L), Eosinophils 0.033 (L) Chemistry: SDMA 15, Albumin 4.1, Globulin 2.6, Albumin/Globulin ration 1.6, Cholesterol 71, Amylase 368

**ULTRASONOGRAPHIC EXAMINATION OF THE ABDOMEN**

**Urinary System**

The urinary bladder is moderately distended with anechoic contents. No masses, inflammatory changes, echogenic sediment or cystoliths are observed. The urinary bladder, trigone and visible pelvic urethra are normal in thickness with a smooth mucosal surface.

The right kidney is normal in size (3.93 cm), shape and echogenicity. It has smooth peripheral margination. There is a normal 1:3 cortex to medulla ratio with appropriate corticomedullary distinction. There is no evidence of pyelectasia, mineral or infarcts observed.

The left kidney is normal in size (3.42 cm), shape and echogenicity. It has smooth peripheral margination. There is a normal 1:3 cortex to medulla ratio with appropriate corticomedullary distinction. There is no evidence of pyelectasia, mineral or infarcts observed.

**Adrenal Glands**

The area of both adrenal glands is examined without evident pathology.

**Spleen**

The spleen is subjectively normal in size with a normal smooth capsular contour. Parenchyma is appropriately finely textured and homogenous with normal echogenicity relative to surrounding tissue (hyperechoic to liver). No focal nodules or masses are observed. Splenic vasculature appears normal.

**Liver**

The liver is subjectively normal in size with normal smooth curvilinear peripheral contour. Parenchyma is appropriately hypoechoic to the spleen in echogenicity and appropriately mildly coarse and homogenous in echotexture. No focal lesions are observed. Visible vasculature and biliary tree appear normal without distension or congestion.

The gallbladder is non-distended in size. The wall is smooth without visible thickening. Luminal contents are primarily anechoic. There is no evidence of cystic or common bile duct dilation.

**Gastrointestinal**

The stomach wall is normal in thickness (canine < 0.5 cm and feline < 0.4 cm) and layering. The lumen of the stomach is empty with no evidence of obstruction, foreign material or infiltrative disease. Pyloric outflow tract appears patent.

The visible small intestine demonstrates areas of thick muscularis layer relative to mucosa (disruption of the normal 1:3 muscularis:mucosa ratio). Small intestinal submucosa is slightly irregular, thick and hyperechoic, without evident loss of layering appreciated. The lumen is empty with no evidence of obstruction or foreign material.



**PATIENT**

Basil Miller

The visible colon is normal in wall thickness (< 0.2 cm) and layering. Contents are consistent with normal formed feces and gas.

**SPECIES**

Feline

**Pancreas**

The pancreatic parenchyma is appropriately isoechoic to surrounding tissue. Visible capsule is smooth and normal in contour. There is no visible pancreatic duct dilation. There is no evidence of active peripancreatic inflammation.

**BREED**

DSH

**Free Abdomen**

There is no evidence of free peritoneal effusion noted in these images.

**SEX**

Spayed Female

There is no apparent lymphadenopathy noted in these images.

**AGE**

1 Year

**ULTRASONOGRAPHIC FINDINGS**

- **Inflammatory bowel disease (IBD) pattern** – Thick muscularis has been reported with infiltrative bowel disease including both benign inflammatory disease as well as infiltrative neoplasia such as lymphoma. No aggressive lymphadenopathy, loss of layering, etc. is noted to make lymphoma more probable, but lymphoma cannot be definitively ruled out without tissue sampling.

**WEIGHT**

6.7 Pounds

**INTERPRETATION OF THE FINDINGS & FURTHER RECOMMENDATIONS**

**INTERPRETED BY**

Beth Johnson, DVM  
DACVIM

Given this patient's young age and neutropenia, first recommendation is a comprehensive infectious disease screening and ruling out infectious diseases including panleukopenia. If an infectious disease cannot be diagnosed, and neutropenia persists, bone marrow cytology could also be considered. Beyond that, given the bowel changes, a gastrointestinal malabsorption panel (including cobalamin, folate, TLI and PLI) to Texas A&M GI Laboratory is recommended for further evaluation of GI and pancreatic function.

**IMAGING PERFORMED BY**

Dr. Danielle Lanz

Ideally, biopsies of the GI tract, being sure to include ileum if possible, are recommended to definitively diagnose and therefore manage the infiltrative bowel disease.

**HOSPITAL NAME**

New Holland VH

If biopsies cannot be obtained, empirical therapies could include diet change, empirical deworming with a 5 day course of Panacur, cobalamin supplementation (unless cobalamin level is evaluated and supplementation is not warranted) and prednisolone (if not contraindicated based on patient contraindications, co-morbidities, etc.). Other supportive therapeutic considerations could include fiber supplementation, especially with large bowel diarrhea and/or a probiotic.

**REFERRING VET**

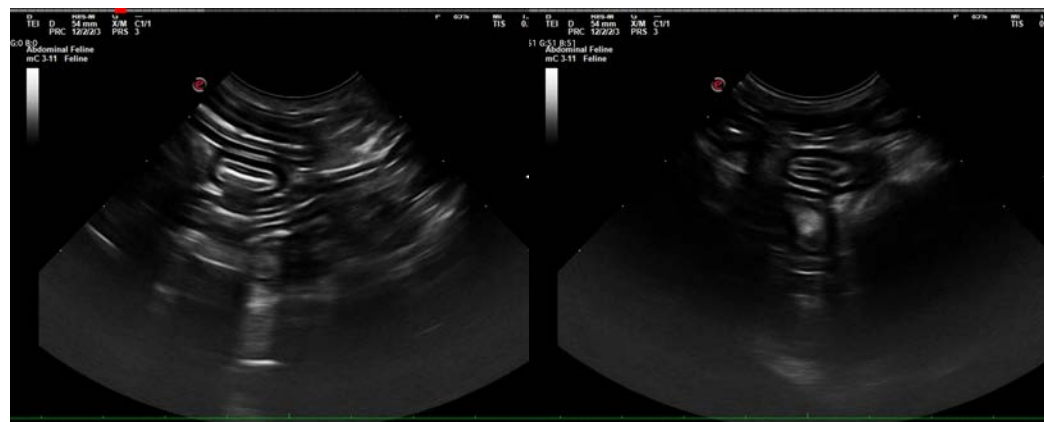Dr. Danielle Lanz

**INVOICE**

46058

**DATE**

3/21/23





**PATIENT**

Basil Miller

**SPECIES**

Feline

**BREED**

DSH

**SEX**

Spayed Female

**AGE**

1 Year

**WEIGHT**

6.7 Pounds

**INTERPRETED BY**

Beth Johnson, DVM  
DACVIM

**IMAGING PERFORMED BY**

Dr. Danielle Lanz

**HOSPITAL NAME**

New Holland VH

**REFERRING VET**

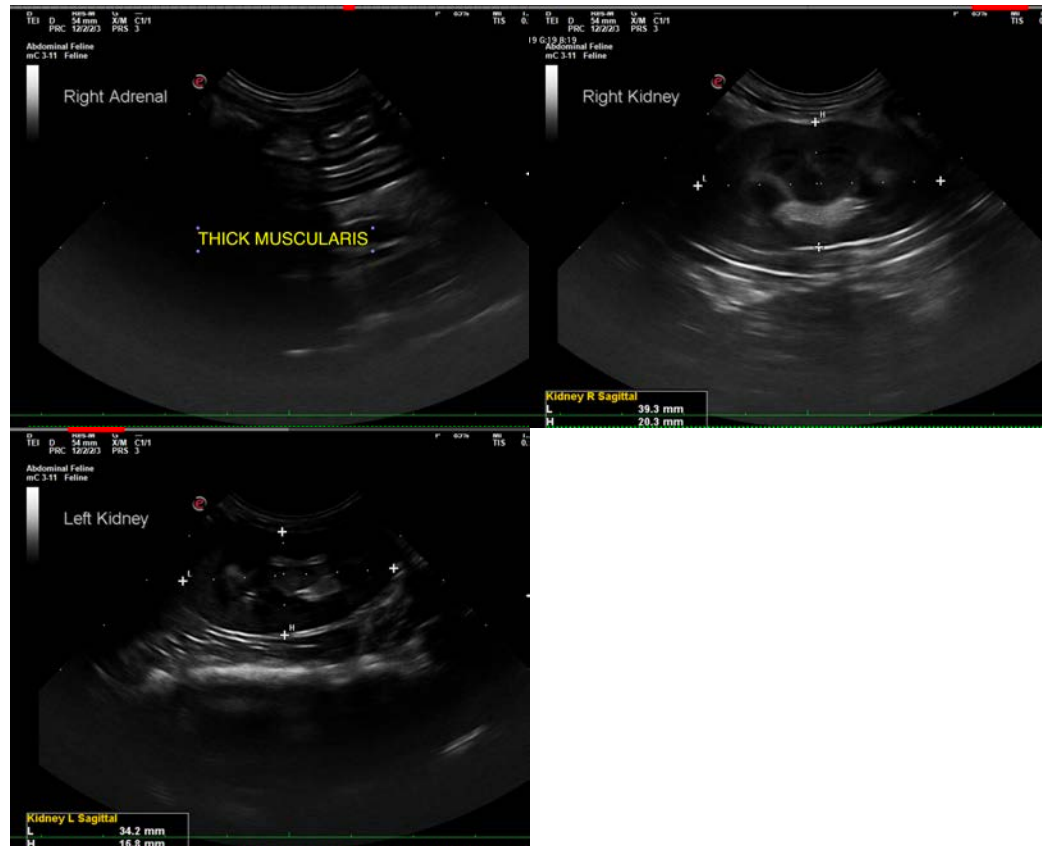
Dr. Danielle Lanz

**INVOICE**

46058

**DATE**

3/21/23



The information and recommendations provided are based on the images presented by the referring veterinarian/sonographer. No evaluation can be communicated regarding pathology that was not visible in the image/video clips provided.

Thank you for this referral. If the clinical or image interpretation does not parallel your findings or if I can be of any further assistance please contact me.

**Beth Johnson, DVM, DACVIM**  
Beth.Johnson@sonopath.com