



PATIENT

Bentley Rudisill

SPECIES

Canine

BREED

Labrador Retriever

SEX

Neutered Male

AGE

5 Years 8 Months

WEIGHT

113 lbs

INTERPRETED BY

Beth Johnson, DVM
DACVIM

IMAGING PERFORMED BY

Ashley Whitesell

HOSPITAL NAME

Dickson Animal Clinic

REFERRING VET

Dr. Richard Hovis

INVOICE

73830

DATE

3/20/26

PRESENTING CLINICAL SIGNS

Vomiting- with blood. Black tar stools- with blood. Lethargic, very weak.

Abnormal PE/Chem/CBC/UA Results: ALT 410 ALP 257 WBC 25.47 RBC 2.60 Going to Attach X-ray to be reviewed as well

ULTRASONOGRAPHIC EXAMINATION OF THE ABDOMEN

Urinary System

The urinary bladder is adequately distended with anechoic contents. No masses, inflammatory changes, echogenic sediment or cystoliths are observed. The urinary bladder, trigone and visible pelvic urethra are normal in thickness with a smooth mucosal surface.

The prostate is unable to be visualized in these images.

The right kidney is normal is size (7.83 cm), shape and echogenicity. It has smooth peripheral margination. There is a normal 1:3 cortex to medulla ratio with appropriate corticomedullary distinction. There is no evidence of pyelectasia, mineral or infarcts observed.

The left kidney is normal is size (7.24 cm), shape and echogenicity. It has smooth peripheral margination. There is a normal 1:3 cortex to medulla ratio with appropriate corticomedullary distinction. There is no evidence of pyelectasia, mineral or infarcts observed.

Adrenal Glands

Adrenal glands are mildly subjectively small (flattened contour). Corticomedullary structure is unremarkable. Visible surrounding vasculature appears normal. Left measures 0.53 cm at the cranial pole and 0.58 cm at the caudal pole. Right measures 0.70 cm at the cranial pole and 0.59 cm at the caudal pole.

Spleen

The spleen is subjectively normal in size with a normal smooth capsular contour. Parenchyma is appropriately finely textured and homogenous with normal echogenicity relative to surrounding tissue (hyperechoic to liver). No focal nodules or masses are observed. Splenic vasculature appears normal.

Liver

The liver is subjectively normal in size with normal smooth curvilinear peripheral contour. Parenchyma is appropriately hypoechoic to the spleen in echogenicity and appropriately mildly coarse and homogenous in echotexture. No focal lesions are observed. Visible vasculature and biliary tree appear normal without distension or congestion.

The gallbladder is non-distended in size. The wall is smooth without visible thickening. Luminal contents are primarily anechoic. There is no evidence of cystic or common bile duct dilation.

Gastrointestinal

The visible stomach wall is normal in thickness and layering. The lumen is mildly distended with primarily fluid as well as some echogenic non-shadowing luminal contents and gas consistent with normal chyme. There is no evidence of obstruction, foreign material, or infiltrative disease. Pyloric outflow tract appears patent.



PATIENT

Bentley Rudisill

SPECIES

Canine

BREED

Labrador Retriever

SEX

Neutered Male

AGE

5 Years 8 Months

WEIGHT

113 lbs

INTERPRETED BY

Beth Johnson, DVM
DACVIM

IMAGING PERFORMED BY

Ashley Whitesell

HOSPITAL NAME

Dickson Animal Clinic

REFERRING VET

Dr. Richard Hovis

INVOICE

73830

DATE

3/20/26

The visible small intestines are normal in wall thickness and layering. Small intestinal motility appears adequate (1-3 contractions per min). The lumen of the small intestine is empty with no evidence of obstruction, foreign material or infiltrative disease.

The visible colon is normal in wall thickness (< 0.2 cm) and layering. Contents are consistent with normal formed feces and gas.

Pancreas

The pancreas that is observed appears appropriately isoechoic to surrounding omental fat. Visible capsule is smooth and normal in contour. Visible pancreatic parenchyma is homogenous and unremarkable. There is no visible pancreatic duct dilation. There is no evidence of active peripancreatic inflammation.

Free Abdomen

There is no visible free peritoneal effusion noted in these images.

There is no apparent pathologic lymphadenopathy noted in these images.

ULTRASONOGRAPHIC FINDINGS

- Subjectively mildly flat adrenal glands – This can be a normal patient variant and/or a sign of exogenous cortisol administration. If exogenous steroids are not being administered, hypoadrenocorticism (either relative or absolute) should be considered.

INTERPRETATION OF THE FINDINGS & FURTHER RECOMMENDATIONS

A baseline cortisol is recommended. If baseline cortisol is less than 2, a full ACTH stimulation test is recommended to rule out hypoadrenocorticism.

Additional gastrointestinal workup recommendations to consider include a routine fecal/giardia exam if not recently evaluated.

A gastrointestinal malabsorption panel (including cobalamin, folate, TLI and PLI) to Texas A&M GI Laboratory is recommended for further evaluation of GI and pancreatic function.

A fecal enteropathogen PCR panel to Texas A&M GI Laboratory could be considered for further evaluation of possible infectious disease. Contact lab for recommendations on how long to discontinue antibiotics (if indicated) prior to obtaining a stool sample for submission.

Additionally, assessment of patient's coagulation status is recommended.

In the meantime:

- Supportive/symptomatic medical management of clinical signs is recommended, including anti-emetics, gastroprotectants (+/- sucralfate, especially with any history of hematemesis), an appetite stimulant and fluid therapy if indicated, etc.
- Additionally, empirical deworming with a 5-day course of Panacur is recommended.
- A full course of empirical Helicobacter triple therapy could be considered.
- A probiotic, such as a visbiome or proviable, may be helpful.



PATIENT

Bentley Rudisill

SPECIES

Canine

BREED

Labrador Retriever

SEX

Neutered Male

AGE

5 Years 8 Months

WEIGHT

113 lbs

INTERPRETED BY

Beth Johnson, DVM
DACVIM

IMAGING PERFORMED BY

Ashley Whitesell

HOSPITAL NAME

Dickson Animal Clinic

REFERRING VET

Dr. Richard Hovis

INVOICE

73830

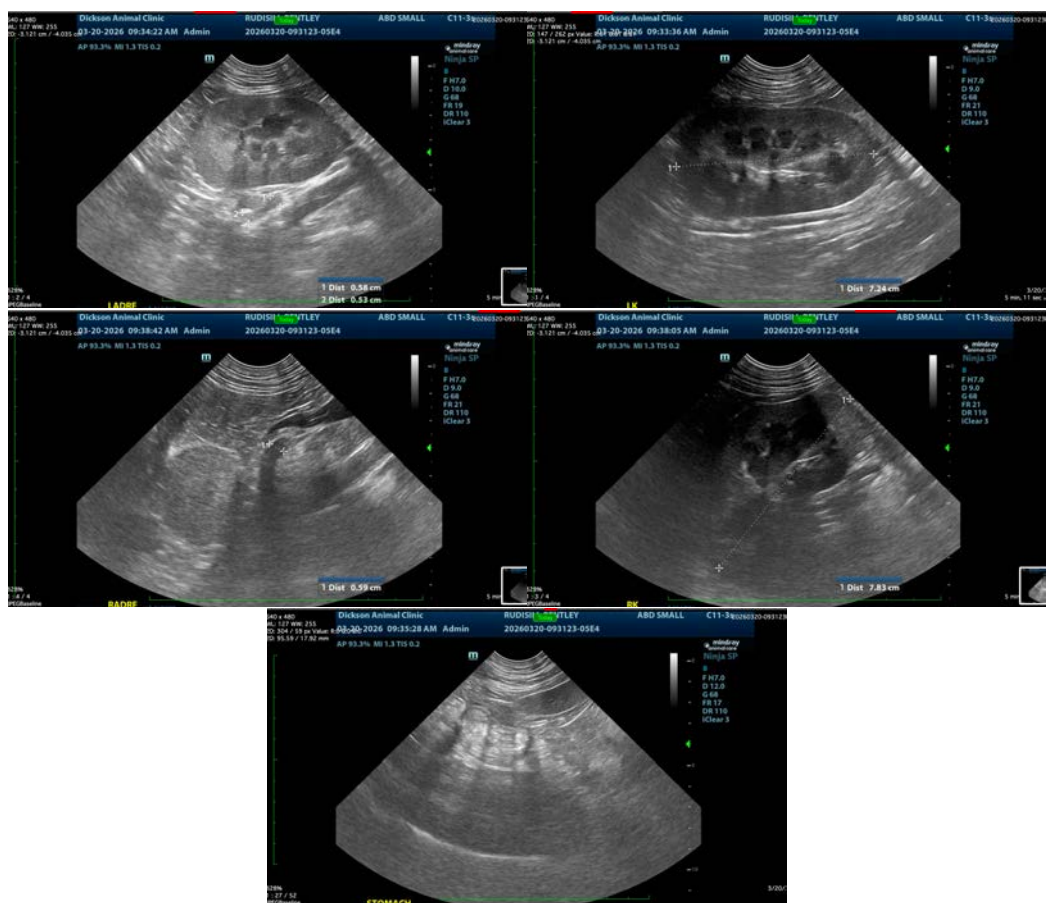
DATE

3/20/26

- Finally, if tolerated, a transition in diet could be considered, based on trial-and-error response with some options to consider including a gastrointestinal biome diet vs a hydrolyzed protein diet (sometimes several trials with different brands are necessary) vs an easy to digest, bland or low-fat diet vs other.

Given the reported anemia, close monitoring, and if indicated, transfusion may also be warranted while finding and treating the suspected gastrointestinal bleed. If a diagnosis is not made and bleeding continues, upper GI gastroscopy/endoscopy could be considered for further visual evaluation and sampling of the stomach and proximal small bowel.

If a radiograph report is elected, submission of radiographs for radiologist review is recommended.



The information and recommendations provided are based on the images presented by the referring veterinarian/sonographer. No evaluation can be communicated regarding pathology that was not visible in the image/video clips provided.

Thank you for this referral. If the clinical or image interpretation does not parallel your findings or if I can be of any further assistance please contact me.

Beth Johnson, DVM, DACVIM
info@sonopath.com