



DATE	PRESENTING CLINICAL SIGNS
3/20/23	History: On Tuesday AM: vomited food - owner was concerned about stomach bug - night before has a bully stick. Next day: wasn't interested in eating - started feeding boiled chicken and rice - no vomiting after When owner came home from work yesterday: no vomiting observed - had episode of vomiting at around 1030p Today: was not interested in eating Drinking with no vomiting. Did have a small bowel movement earlier in the week Known to unstuff his toys - owner well take away from him when he does Presented to rdvm: - vomiting, decreased defecation - Bw: Wbc 20.7 (6-17), Lym 8.87 (1-4.8), Hct 58.48 (37-55), Plt 5 (165-500), macro-platelets - Rads: dilated stomach.
PATIENT	
Winston Cudworth	
SPECIES	
Canine	
BREED	
King Charles Cavalier	Current Medications: Omeprazole, Ondansetron, Baytril, Buprenorphine, Entyce, Gabapentin, Cerenia, Protonix, Metoclopramide. Lab Results: See attached. Date of Previous IntraPet Ultrasound: No previous. Sedation: Not required to complete full diagnostic ultrasound. Stat Report: Not requested. Imaging Performed By: Rachel Brillhart, RDMS.
SEX	
Neutered Male	
AGE	
2/15/14	
WEIGHT	
24.7 Pounds	
INTERPRETED BY	
Beth Johnson, DVM DACVIM	
HOSPITAL NAME	
Animal Emergency Hospital	
REFERRING VET	
Dr. Nacke-Horney	
INVOICE	
21735	

ULTRASONOGRAPHIC EXAMINATION OF THE ABDOMEN

Urinary System

Urinary bladder is adequately distended with anechoic contents. No masses, inflammatory changes, echogenic sediment or cystoliths are observed. The urinary bladder, trigone and visible pelvic urethra are normal in thickness with a smooth mucosal surface.

Prostate is normal in size, echotexture and echogenicity for a neutered male.

Left kidney is normal is size (4.81 cm), shape and echogenicity. It has smooth peripheral margination. There is a normal 1:3 cortex to medulla ratio with appropriate corticomedullary distinction. There is no evidence of pyelectasia, mineral or infarcts observed.

Right kidney is normal is size (4.96 cm), shape and echogenicity. It has smooth peripheral margination. There is a normal 1:3 cortex to medulla ratio with appropriate corticomedullary distinction. There is no evidence of pyelectasia, mineral or infarcts observed.

Adrenal Glands

Left adrenal gland is normal in size (2.28 cm long x 0.83 cm at cranial pole and 0.72 cm at caudal pole), shape and overall architecture, echogenicity and echotexture. Visible surrounding vasculature appears normal.

Right adrenal gland is normal in size (2.22 cm long x 0.6 cm at cranial pole and 0.51 cm at caudal pole), shape and overall architecture, echogenicity and echotexture. Visible surrounding vasculature appears normal.

Spleen

Spleen is subjectively normal in size with a normal smooth capsular contour. Parenchyma is appropriately finely textured and homogenous with normal echogenicity relative to surrounding tissue (hyperechoic to liver). A 0.7 cm x 0.9 cm anechoic non-capsule-disrupting nodule is noted in the mid body. Splenic vasculature appears normal.

Liver

Liver is subjectively normal in size with normal smooth curvilinear peripheral contour. Parenchyma is appropriately hypoechoic to the spleen in echogenicity and appropriately mildly coarse and homogenous in echotexture. No focal lesions are observed. Visible vasculature and biliary tree appear normal without distension or congestion.

Gallbladder is non-distended in size. The wall is smooth without visible thickening. Luminal contents are primarily anechoic. There is no evidence of cystic or common bile duct dilation.

Gastrointestinal

The visible stomach wall is normal in thickness and layering. The lumen of the stomach is empty with no evidence of obstruction, foreign material or infiltrative disease. Pyloric outflow tract appears patent.

The visible small intestines are normal in wall thickness and layering. Small intestinal motility appears adequate (1-3 contractions per min). The lumen of the small intestine is empty with no evidence of obstruction, foreign material or infiltrative disease.

The visible colon is normal in wall thickness and layering. Contents are consistent with normal formed feces and gas.

Pancreas

The observed pancreas appears appropriately isoechoic to surrounding omental fat. The capsule is mildly irregular in shape. Parenchyma is mildly heterogenous and coarse. There is no visible pancreatic duct dilation. There is no evidence of active peripancreatic inflammation.

Free Abdomen

There is no evidence of peritoneal effusion. There is no apparent lymphadenopathy.

Other

There is no evidence of heart base or pericardial pathology noted in these images at this time. If cardiac function evaluation is desired a full echocardiogram is recommended.

ULTRASONOGRAPHIC FINDINGS

Primary Findings

- Hypo to anechoic splenic nodule – likely represents a benign lesion such as a cyst, hematoma, nodular hyperplasia, extramedullary hematopoiesis, etc., however while considered less likely, infiltrative neoplasia can mimic benign lesions, and cannot be ruled out.

Secondary Findings

- Pancreatic age-related remodeling – Mild irregularities are consistent with benign age-related change. Low-grade smoldering chronic pancreatitis cannot be ruled out and should be suspected in the face of appropriate clinical signs.

INTERPRETATION OF THE FINDINGS & FURTHER RECOMMENDATIONS

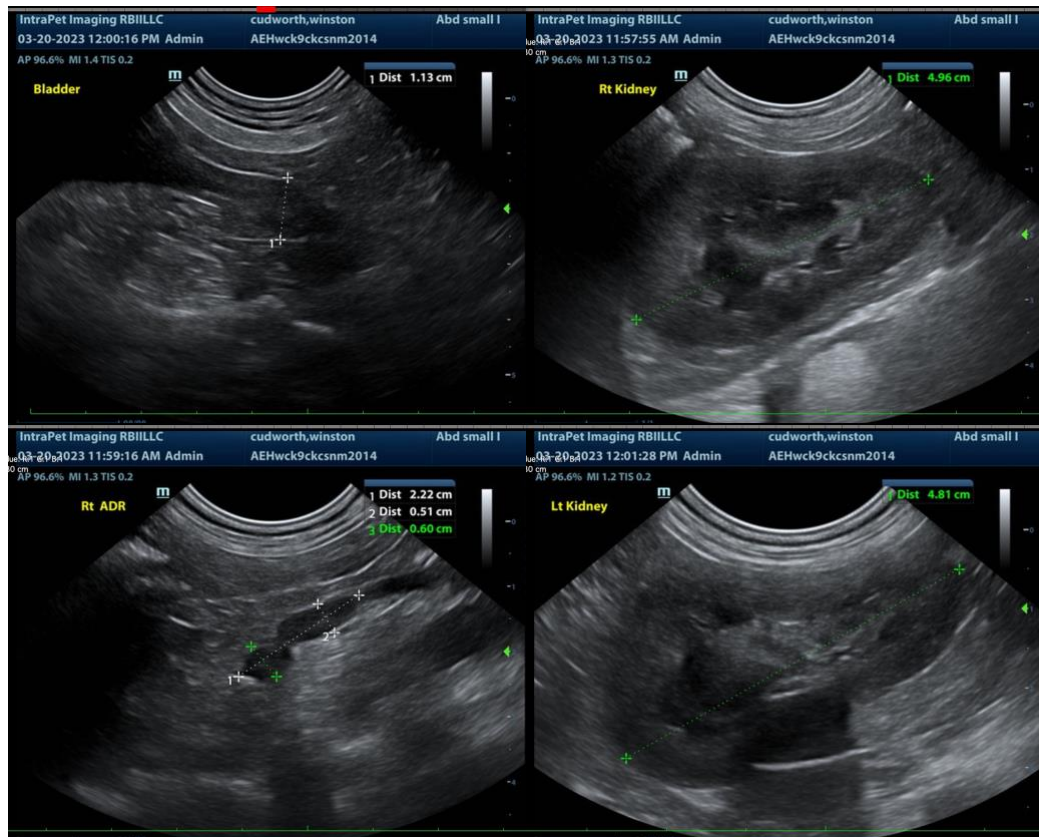
There is no ultrasonographically visible explanation for this patients gastrointestinal signs present in these images at this time. Recommendations include a baseline cortisol is recommended. If baseline cortisol is

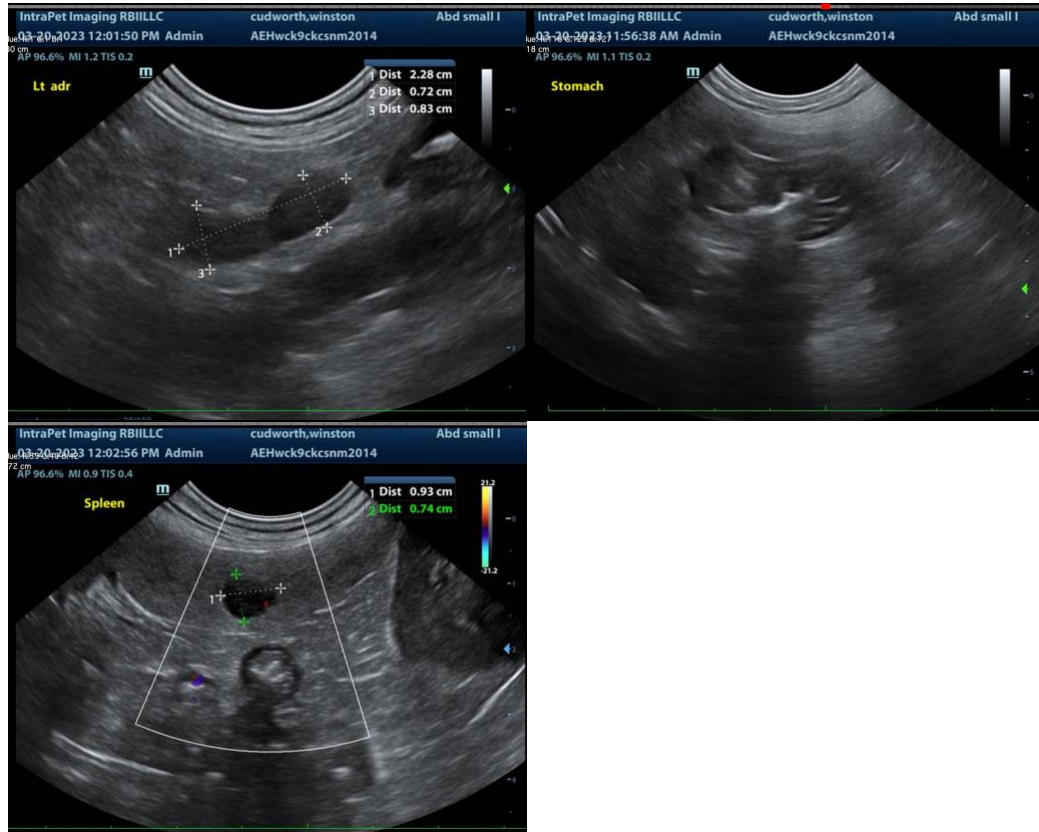
less than 2, a full ACTH stimulation test is recommended to rule out hypoadrenocorticism.

A gastrointestinal malabsorption panel (including cobalamin, folate, TLI and PLI) to Texas A&M GI Laboratory is recommended for further evaluation of GI and pancreatic function. Pending results of that, further evaluation of the reported lymphocytosis, beginning potentially with a pathology review of the cells should be considered.

In the meantime, supportive/symptomatic medical management of gastritis with antiemetics, gastroprotectants, etc., is recommended.

If tolerated, a transition in diet could also be considered based on trial-and-error response, with options including a bland easy-to-digest diet, potentially a low fat diet or hydrolyzed protein diet.





The information and recommendations provided are based on the images presented by the referring veterinarian. No evaluation can be communicated regarding pathology that was not visible in the image/video clips provided.

Thank you for this referral. If the clinical or image interpretation does not parallel your findings or if I can be of any further assistance please contact me.

Beth Johnson, DVM DACVIM
Beth.Johnson@SonoPath.com