

**DATE PRESENTING CLINICAL SIGNS**

3/20/23

History: Lost half pound since February. Decreased appetite, vocal at night.

**PATIENT**

Starburst Cox

Current Medications: Shen calmer- Chinese herbs daily.  
 Lab Results: Elevated liver enzymes, other values unremarkable.  
 Date of Previous IntraPet Ultrasound: No previous.  
 Sedation: Not required to complete full diagnostic ultrasound.  
 Stat Report: Not requested.  
 Imaging Performed By: Rachel Brillhart, RDMS.

**SPECIES**

Feline

**BREED**

DSH

**SEX**

Spayed Female

**AGE**

5/20/14

**WEIGHT**

2.63 kg

**INTERPRETED BY**Beth Johnson, DVM  
DACVIM**HOSPITAL NAME**Cat Hospital at  
Towson**REFERRING VET**

Dr. Slaughter

**INVOICE**

21737

**ULTRASONOGRAPHIC EXAMINATION OF THE ABDOMEN****Urinary System**

Urinary bladder is adequately distended with anechoic contents. No masses, inflammatory changes, echogenic sediment or cystoliths are observed. The urinary bladder, trigone and visible pelvic urethra are normal in thickness with a smooth mucosal surface.

Left kidney is normal is size (3.01 cm), shape and echogenicity. It has smooth peripheral margination. There is a normal 1:3 cortex to medulla ratio with appropriate corticomedullary distinction. There is no evidence of pyelectasia or infarcts observed.

Right kidney is normal is size (3.11 cm), shape and echogenicity. It has smooth peripheral margination. There is a normal 1:3 cortex to medulla ratio with appropriate corticomedullary distinction. There is no evidence of pyelectasia or infarcts observed.

Bilaterally in the kidneys, there are multiple, too numerous to count, small punctate hyperechoic/mineral foci throughout the cortices, consistent with punctate mineral or potentially subcapsular infarcts, likely of no clinical consequence.

**Adrenal Glands**

Left adrenal gland is normal in size (0.41 cm), shape and overall architecture, echogenicity and echotexture. Visible surrounding vasculature appears normal.

Right adrenal gland is normal in size (0.46 cm), shape and overall architecture, echogenicity and echotexture. Visible surrounding vasculature appears normal.

**Spleen**

Spleen is subjectively normal in size with a normal smooth capsular contour. Parenchyma is appropriately finely textured and homogenous with normal echogenicity relative to surrounding tissue (hyperechoic to liver). No focal nodules or masses are observed. Splenic vasculature appears normal.

**Liver**

Liver is subjectively normal in size with normal smooth curvilinear peripheral contour. Parenchyma is appropriately hypoechoic to the spleen in echogenicity and appropriately mildly coarse and homogenous in echotexture. No focal lesions are observed. Visible vasculature and biliary tree appear normal without distension or congestion.

Gallbladder is non-distended in size. The wall is smooth without visible thickening. Luminal contents are primarily anechoic. There is no evidence of cystic or common bile duct dilation.

### ***Gastrointestinal***

The visible stomach wall is normal in thickness and layering. The lumen of the stomach is empty with no evidence of obstruction, foreign material or infiltrative disease. Pyloric outflow tract appears patent.

The visible small intestine demonstrates areas of mildly thick muscularis layer relative to mucosa (disruption of the normal 1:3 muscularis:mucosa ratio). Small intestinal submucosa is slightly irregular, thick and hyperechoic, without evident loss of layering appreciated. The lumen of the small intestine is empty with no evidence of obstruction or foreign material.

The visible colon is normal in wall thickness and layering. Contents are consistent with normal formed feces and gas.

### ***Pancreas***

The observed pancreas appears appropriately isoechoic to surrounding omental fat. Visible capsule is smooth and normal in contour. Visible pancreatic parenchyma is homogenous and unremarkable. There is no visible pancreatic duct dilation. There is no evidence of active peripancreatic inflammation.

### ***Free Abdomen***

There is no evidence of peritoneal effusion. The mesenteric lymph nodes are prominent in size with swollen capsular contour. Normal elongated shape (length to width ratio) is maintained. There is no loss of parenchymal detail.

## **ULTRASONOGRAPHIC FINDINGS**

- Mild inflammatory bowel disease (IBD) pattern – Thick muscularis has been reported with infiltrative bowel disease including both benign inflammatory disease as well as infiltrative neoplasia such as lymphoma. No aggressive lymphadenopathy, loss of layering, etc. is noted to make lymphoma more probable, but lymphoma cannot be definitively ruled out without tissue sampling.
- Reactive mesenteric lymph nodes – infiltrative neoplastic disease cannot be ruled out but is considered less likely.
- Punctate mineralizations throughout the renal cortices bilaterally, likely of no clinical consequence

## **INTERPRETATION OF THE FINDINGS & FURTHER RECOMMENDATIONS**

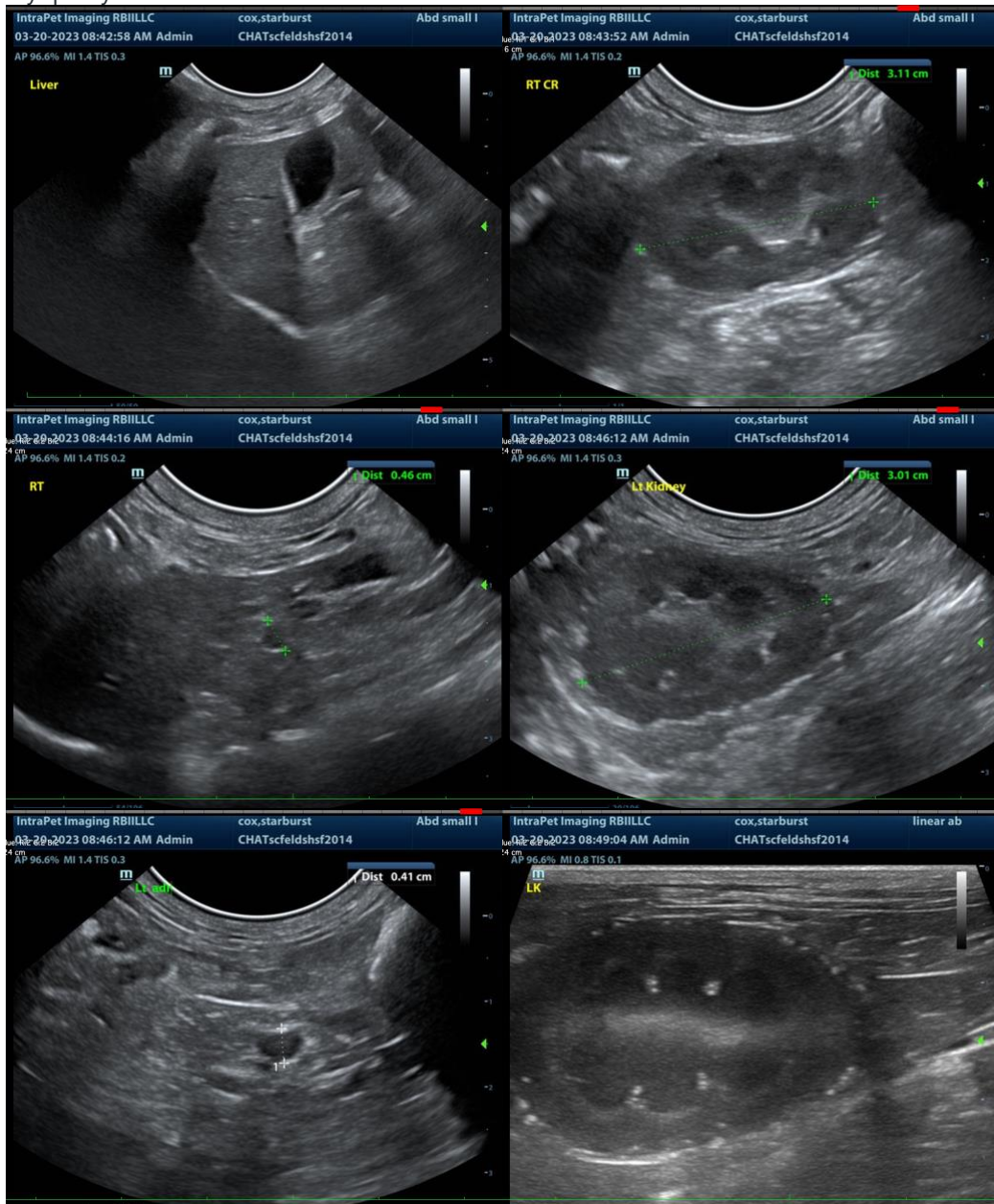
A gastrointestinal malabsorption panel (including cobalamin, folate, TLI and PLI) to Texas A&M GI Laboratory is recommended for further evaluation of GI and pancreatic function.

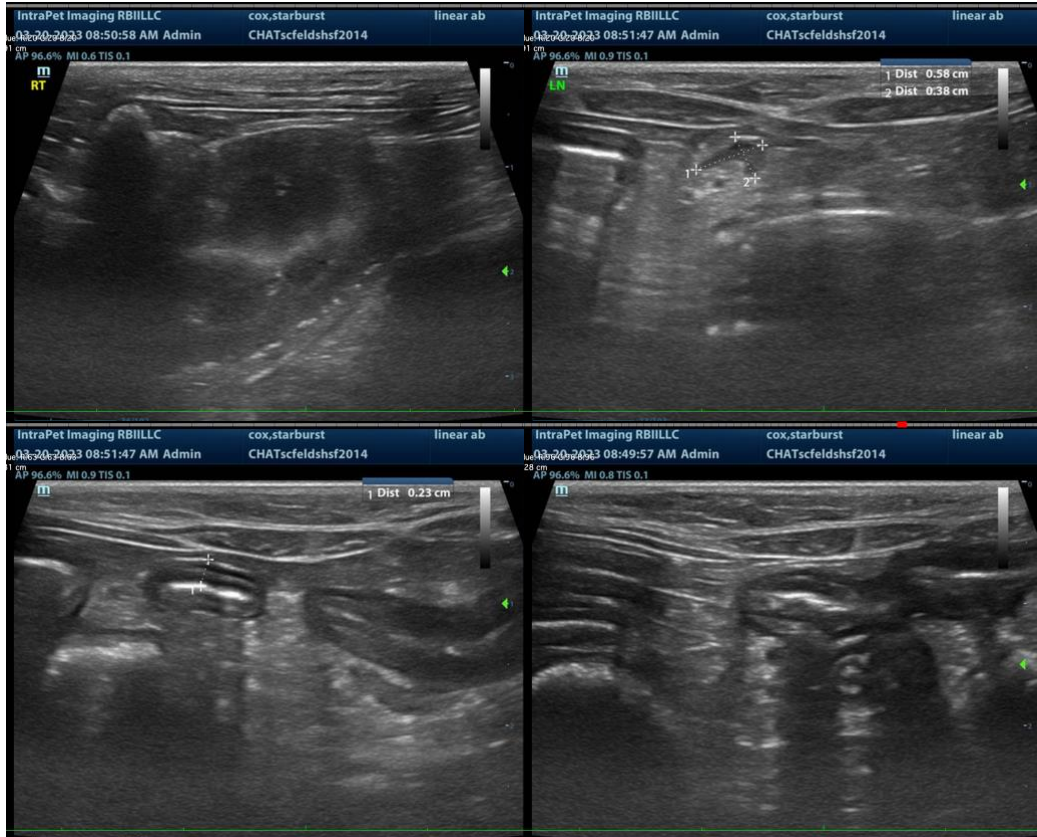
Ideally, biopsies of the GI tract, being sure to include ileum, if possible, are recommended to definitively diagnose and therefore manage the infiltrative bowel disease.

If biopsies cannot be obtained, empirical therapies could include a probiotic (if diarrhea is present, such as Visbiome or Provable), empirical deworming with a 5-day course of Panacur and, if tolerated, a transition in diet, based on trial-and-error response, beginning with a hydrolyzed protein diet. Some patients respond to one brand/version of a hydrolyzed protein diet better than another brand, so several trials may be required. Additional considerations could include cobalamin supplementation (unless cobalamin level is evaluated and supplementation is not warranted) and prednisolone (if not contraindicated based on patient contraindications, co-morbidities, etc.).

Additionally, or prior to more invasive diagnostics, given this patients mildly increased liver enzymes and

markedly increased CK, further comprehensive evaluation for possible infectious diseases, including toxoplasma, and/or other myopathies that may be contributing to clinical signs, is also recommended, especially given this patients reported nighttime vocalization, which could be pain secondary to a myopathy.





The information and recommendations provided are based on the images presented by the referring veterinarian. No evaluation can be communicated regarding pathology that was not visible in the image/video clips provided.

Thank you for this referral. If the clinical or image interpretation does not parallel your findings or if I can be of any further assistance please contact me.

**Beth Johnson, DVM DACVIM**  
Beth.Johnson@SonoPath.com