

**DATE PRESENTING CLINICAL SIGNS**

3/20/23 History: Chronically elevated liver values; significant increase since September 2022.

**PATIENT**

Copper Almond

Current Medications: Denamarin large dog advanced.  
 Lab Results: ALT 749, ALKP 1767. Bloodwork performed 3/6.  
 Date of Previous IntraPet Ultrasound: No previous.  
 Sedation: Not required to complete full diagnostic ultrasound.  
 Stat Report: Not requested.  
 Imaging performed by: Rachel Brillhart, CVT, RDMS

**SPECIES**

Canine

**BREED**

Labrador Mix

**SEX**

Neutered Male

**AGE**

12/1/2008

**WEIGHT**

58.2 Pounds

**ULTRASONOGRAPHIC EXAMINATION OF THE ABDOMEN****Urinary System**

Urinary bladder is adequately distended with anechoic contents. No masses, inflammatory changes, echogenic sediment or cystoliths are observed. The urinary bladder, trigone and visible pelvic urethra are normal in thickness with a smooth mucosal surface.

Prostate is normal in size, echotexture and echogenicity for a neutered male.

Left kidney is normal is size (6.78 cm), shape and echogenicity. It has smooth peripheral margination. There is a normal 1:3 cortex to medulla ratio with appropriate corticomedullary distinction. There is no evidence of pyelectasia, mineral or infarcts observed.

Right kidney is normal is size (6.63 cm), shape and echogenicity. It has smooth peripheral margination. There is a normal 1:3 cortex to medulla ratio with appropriate corticomedullary distinction. There is no evidence of pyelectasia, mineral or infarcts observed.

**INTERPRETED BY**

Beth Johnson, DVM  
 DACVIM

**Adrenal Glands**

Left adrenal gland is normal in size (3.72 cm long x 0.7 cm at cranial pole and 0.86 cm at caudal pole), shape and overall architecture, echogenicity and echotexture. Visible surrounding vasculature appears normal.

Right adrenal gland is normal in size (3.01 cm long x 1.11 cm at cranial pole and 0.88 cm at caudal pole), shape and overall architecture, echogenicity and echotexture. Visible surrounding vasculature appears normal.

**HOSPITAL NAME**

Banfield Timonium

**Spleen**

Spleen is generally normal in size and shape with a smooth capsular contour. Parenchyma is diffusely nodular in appearance characterized by small discrete hypoechoic nodules. Splenic vasculature appears normal.

**REFERRING VET**

Dr. Borrison

**Liver****INVOICE**

21732

Liver is subjectively enlarged with mildly irregular margins. Parenchyma is markedly heterogenous, characterized by multiple poorly defined hypoechoic nodules, as well as multifocal heterogenous hyperechoic nodules within an otherwise overall mildly hyperechoic liver parenchyma. Visible vasculature and biliary tree appear normal without distension or congestion.

Gallbladder is moderately distended with anechoic bile as well as moderate suspended and gravity dependent echogenic debris. The wall is smooth without visible thickening. There is no evidence of cystic or CBD dilation. There is no evidence of effusion or inflammation.

### ***Gastrointestinal***

The visible stomach wall is normal in thickness and layering. The lumen of the stomach is mildly distended with very echogenic reverberation artifact from intraluminal gas. There is no evidence of obstruction, foreign material or infiltrative disease; however, complete visualization of far wall is partially inhibited by gas. Pyloric outflow tract appears patent.

The visible small intestines are normal in wall thickness and layering. Small intestinal motility appears adequate (1-3 contractions per min). The lumen of the small intestine is empty with no evidence of obstruction, foreign material or infiltrative disease.

The visible colon is normal in wall thickness and layering. Contents are consistent with normal formed feces and gas.

### ***Pancreas***

The observed pancreas appears appropriately isoechoic to surrounding omental fat. The capsule is mildly irregular in shape. Parenchyma is mildly heterogenous and coarse. There is no visible pancreatic duct dilation. There is no evidence of active peripancreatic inflammation.

### ***Free Abdomen***

There is no evidence of peritoneal effusion. Multiple prominent heterogenous cystic cranial abdominal/portal lymph nodes are noted.

### ***Other***

There is no evidence of heart base or pericardial pathology noted in these images at this time. If cardiac function evaluation is desired a full echocardiogram is recommended.

## **ULTRASONOGRAPHIC FINDINGS**

### **Primary Findings**

- A markedly heterogenous liver, which can be seen with benign processes, such as nodular hyperplasia, steroid or vacuolar hepatopathy, extramedullary hematopoiesis, or even chronic inflammatory disease with concurrent fibrosis of old hematomas or granulomas, or myelolipomas resulting in the hyperechoic nodules. However, infiltrative neoplasia, such as round cell neoplasia, or even metastatic disease can mimic the changes seen, and cannot be ruled out without tissue sampling, especially, given the concurrent presence of heterogenous cavitated portal lymph nodes, which may represent reactive lymphadenopathy, or infiltrative neoplasia, and also cannot be differentiated without tissue sampling.
- Splenic micronodular hyperplasia – This nodular change is often associated with benign aging nodular hyperplasia. Infiltrative neoplasia, however, including both early hemangiosarcoma as well as round cell neoplasia cannot be ruled out.
- Moderate gallbladder debris - Cholecystic debris is of unknown clinical significance. It can be seen with biliary stasis from fasting or illness. Cholecystic debris is not necessarily related to hepatobiliary disease. Echogenic bile is most commonly an incidental finding in dogs and should be interpreted in combination with clinical signs such as nausea, inappetence, cranial abdominal discomfort and/or laboratory changes such as increased ALP and/or increased Tbili.

### **Secondary Findings**

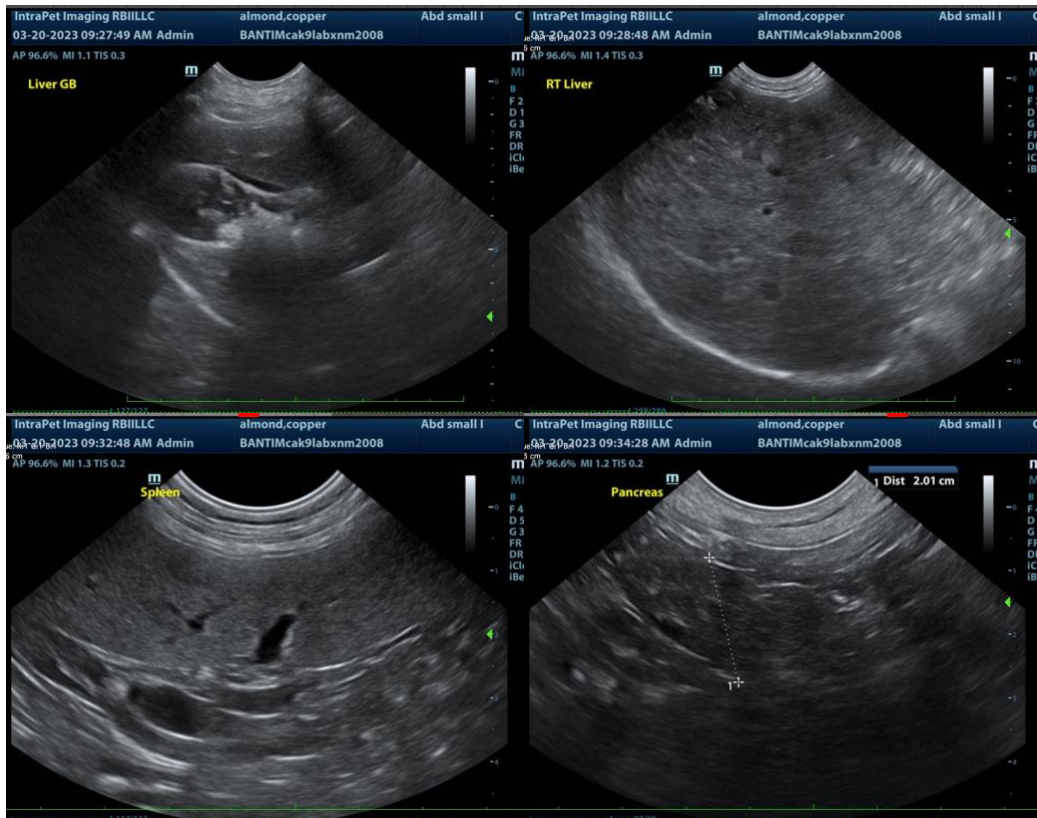
- Pancreatic age-related remodeling – Mild irregularities are consistent with benign age-related change. Low-grade smoldering chronic pancreatitis cannot be ruled out and should be suspected in the face of appropriate clinical signs.

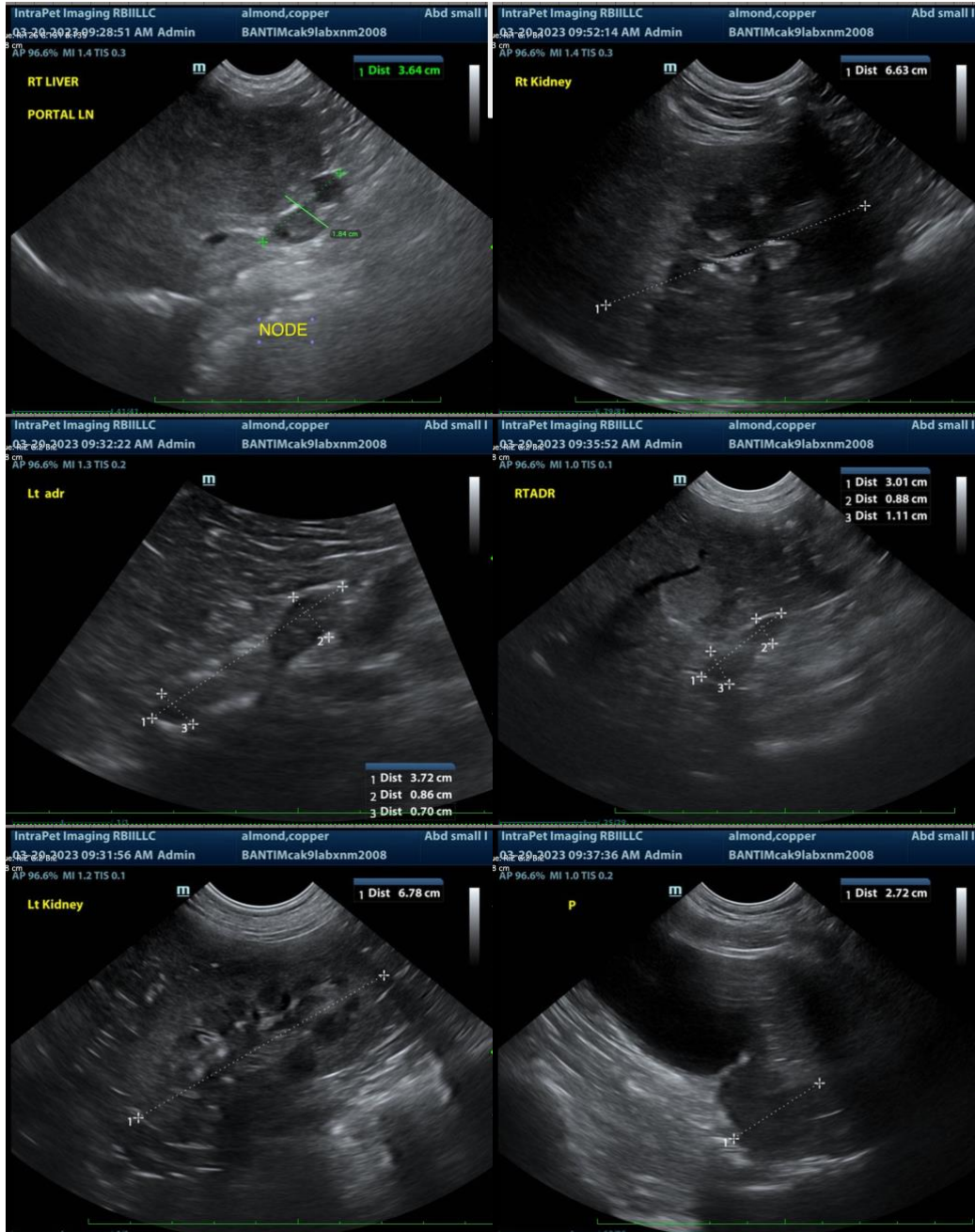
### **INTERPRETATION OF THE FINDINGS & FURTHER RECOMMENDATIONS**

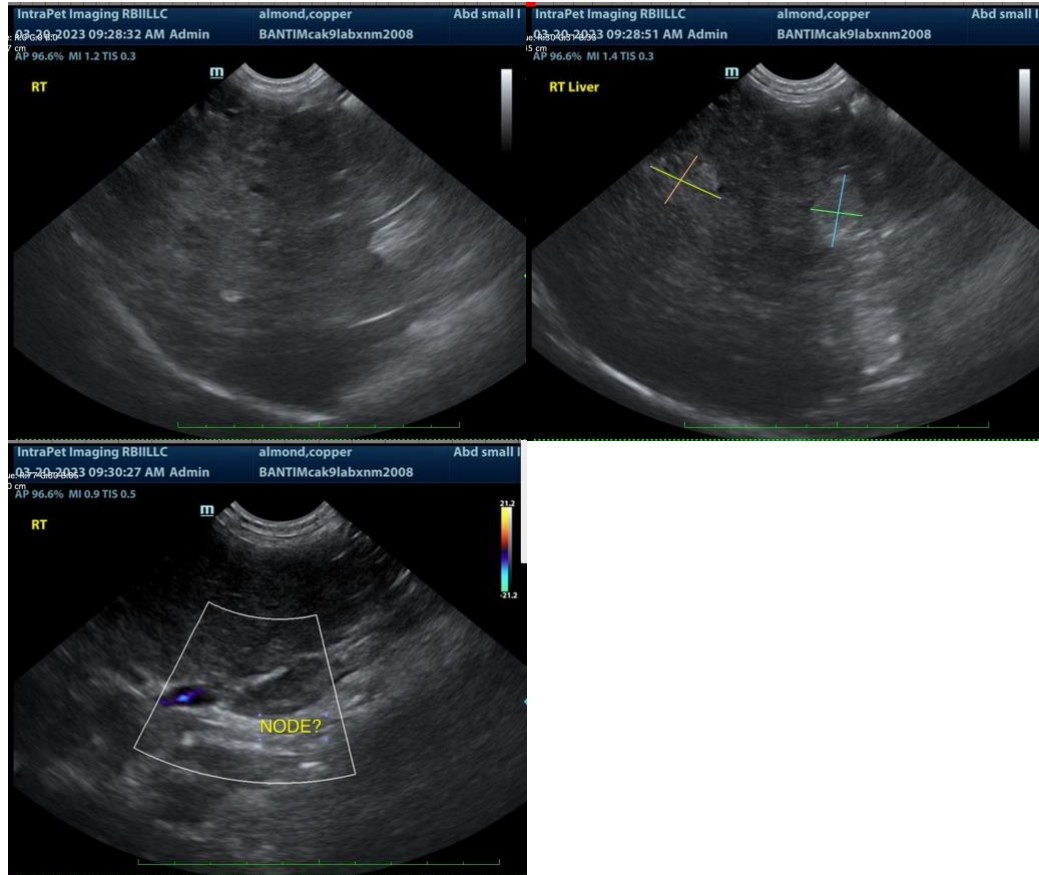
Three view thoracic radiographs are recommended for further assessment of cardio-pulmonary status as well as to further evaluate for any evidence of metastatic disease, if not recently evaluated.

Testing for Leptospirosis is recommended. Bile acids are recommended, if tбили is not increased. An empirical course of antibiotics and hepatic nutraceuticals may be tried empirically, with monitoring of ALT for improvement. If improvement is noted, antibiotics should be continued until liver enzymes either normalize or plateau (recheck every 2-3 weeks); however, if improvement is not noted and/or enzyme increase progresses, antibiotics should not be continued long term and liver tissue sampling is recommended.

Additionally, FNA of the liver should be performed to assess inflammatory cell type, rule in/out round cell neoplasia, etc. (if patient's coagulation status is appropriate). If round cell neoplasia is not diagnosed, a liver biopsy (including copper level assessment) may be required to definitively diagnose the underlying hepatopathy.







The information and recommendations provided are based on the images presented by the referring veterinarian. No evaluation can be communicated regarding pathology that was not visible in the image/video clips provided.

Thank you for this referral. If the clinical or image interpretation does not parallel your findings or if I can be of any further assistance please contact me.

**Beth Johnson, DVM DACVIM**  
Beth.Johnson@SonoPath.com