

**DATE PRESENTING CLINICAL SIGNS**

3/2/22

P diagnosed with diabetes in 2017. P has been regulated since then but recently became unregulated. Recent BG curves have had abnormal results but p is clinically doing fine and is acting normal.

PATIENT

Mr. Bojangles Mason

Current Medications: NPH- 3 units am, 2 units pm.

Lab Results: Pending.

Date of Previous IntraPet Ultrasound: No previous.

Sedation: Telazol IV.

Stat Report: Not requested.

SPECIES

Feline

ULTRASONOGRAPHIC EXAMINATION OF THE ABDOMEN**BREED**

DSH

Urinary System

Urinary bladder is moderately distended. It has a normal uniform wall thickness (<0.2 cm). Contents include primarily anechoic fluid combined with a large quantity of suspended echogenic non-shadowing debris within the fluid. No masses or cystoliths are observed. The trigone and visible pelvic urethra are normal in thickness with a smooth mucosal surface.

SEX

Neutered Male

The right kidney is normal in size (3.73 cm), shape and echogenicity. It has smooth peripheral margination. There is a normal 1:3 cortex to medulla ratio with appropriate corticomedullary distinction. There is no evidence of pyelectasia, mineral or infarcts observed.

AGE

9/23/05

The left kidney is normal in size (3.65 cm), shape and echogenicity. It has smooth peripheral margination. There is a normal 1:3 cortex to medulla ratio with appropriate corticomedullary distinction. There is no evidence of pyelectasia, mineral or infarcts observed. An incidental renal cortical cyst is noted in the left kidney.

WEIGHT

14.78 Pounds

INTERPRETED BYBeth Johnson, DVM
DACVIM**Adrenal Glands**

The right adrenal gland is normal in size (0.40 cm thick), shape and contour. Corticomedullary structure is unremarkable. Visible surrounding vasculature appears normal.

IMAGING PERFORMED BYStephanie Pearce
RDMS, RVT

The left adrenal gland is normal in size (0.39 cm thick), shape and contour. Corticomedullary structure is unremarkable. Visible surrounding vasculature appears normal.

HOSPITAL NAME

Northwind AH

Spleen

The spleen is subjectively normal in size with a normal smooth capsular contour. Parenchyma is appropriately finely textured and homogenous with normal echogenicity relative to surrounding tissue (hyperechoic to liver). No focal nodules or masses are observed. Splenic vasculature appears normal.

REFERRING VET

Dr. Cross

Liver

The liver is subjectively normal in size with normal smooth curvilinear peripheral contour. Parenchyma is appropriately hypoechoic to the spleen in echogenicity and appropriately mildly coarse and homogenous in echotexture. No focal lesions are observed. Visible vasculature and biliary tree appear normal without distension or congestion.

INVOICE

35848

The gallbladder is moderately distended with anechoic bile and gravity dependent echogenic sediment. The wall is smooth without visible thickening. There is no evidence of cystic or common bile duct dilation. There is no evidence of effusion or inflammation.

Gastrointestinal

The stomach wall is normal in thickness (canine < 0.5 cm and feline < 0.4 cm) and layering. The lumen of the stomach is empty with no evidence of obstruction, foreign material or infiltrative disease. Pyloric outflow tract appears patent.

The visible small intestines are normal in wall thickness. Normal layering is maintained except for a diffusely disproportionately thick muscularis layer relative to mucosa. Small intestinal motility appears adequate (1-3 contractions per min). The lumen of the small intestine is empty with no evidence of obstruction, foreign material or infiltrative disease.

The visible colon is normal in wall thickness (< 0.2 cm) and layering. Contents are consistent with normal formed feces and gas.

Pancreas

The pancreatic parenchyma is appropriately isoechoic to surrounding tissue. Visible capsule is smooth and normal in contour. There is no visible pancreatic duct dilation. There is no evidence of active peripancreatic inflammation.

Free Abdomen

There is no evidence of peritoneal effusion. Small, hypoechoic mesenteric lymph nodes are visible.

PRIMARY FINDINGS

- Large amount of suspended and dependent non-shadowing urinary bladder debris/sand
- Thick muscularis – This finding has been reported in cats with infiltrative bowel disease including both benign inflammatory disease as well as infiltrative neoplasia such as lymphoma.
- Likely reactive mesenteric lymphadenopathy

SECONDARY FINDINGS

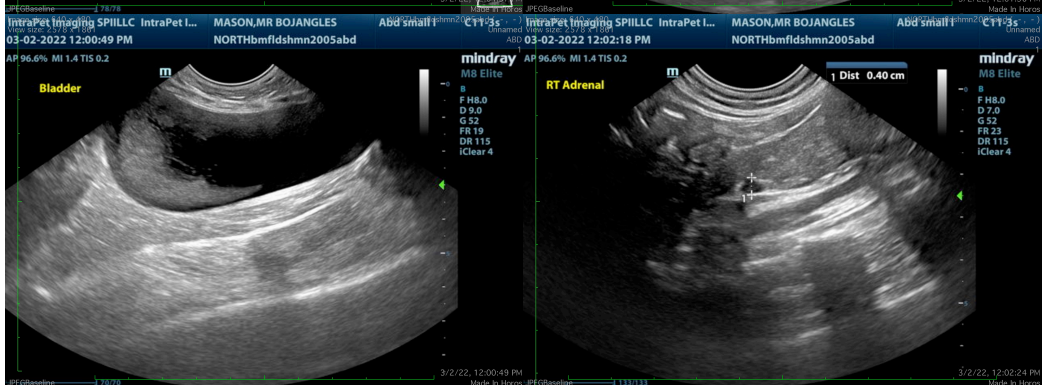
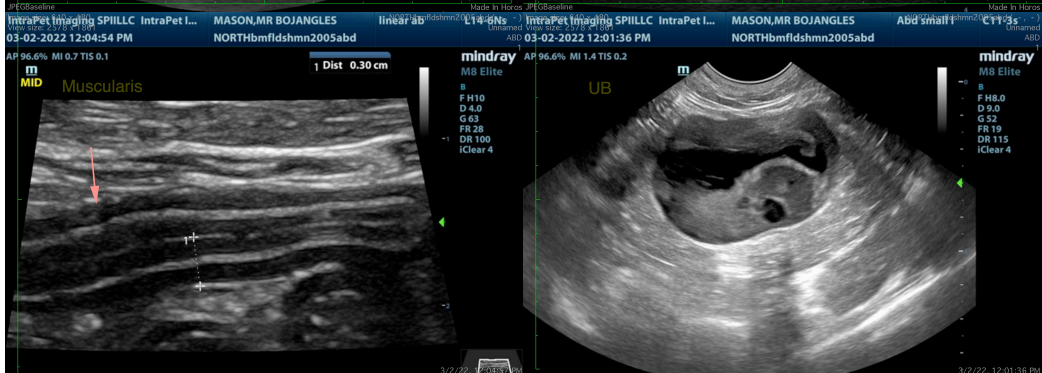
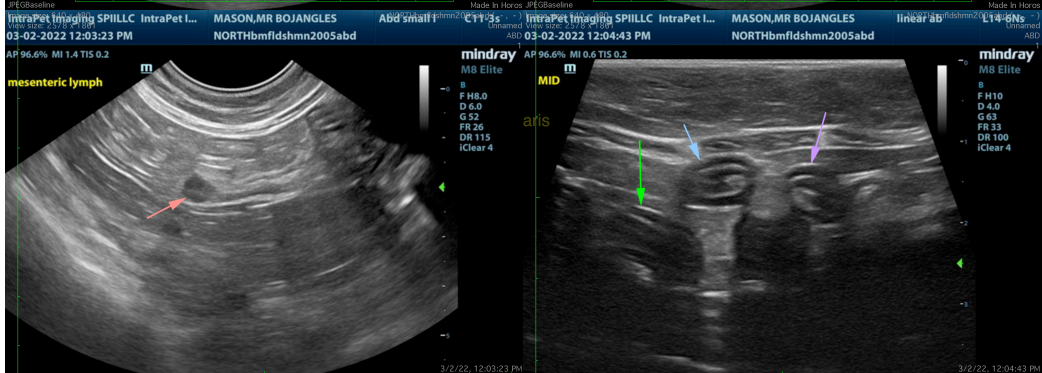
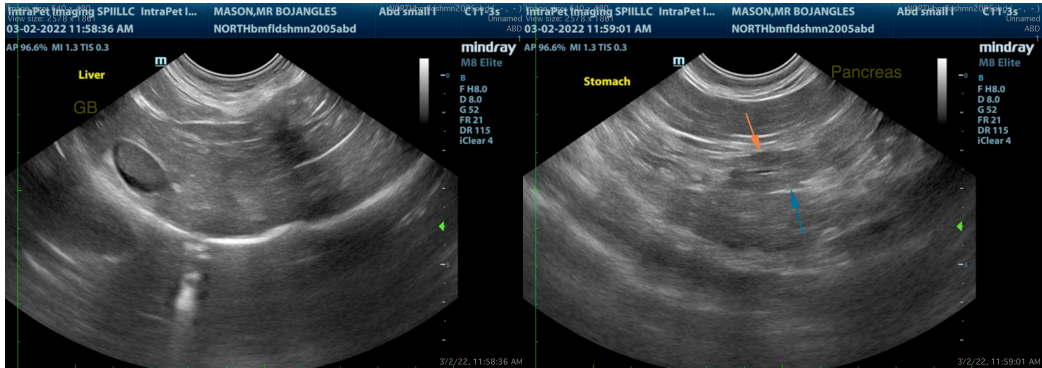
- Cholecystic debris of unknown clinical significance – Significance should be interpreted in combination with clinical signs and/or laboratory changes such as increased liver enzymes and/or total bilirubin.
- Incidental renal cortical cyst in the left kidney

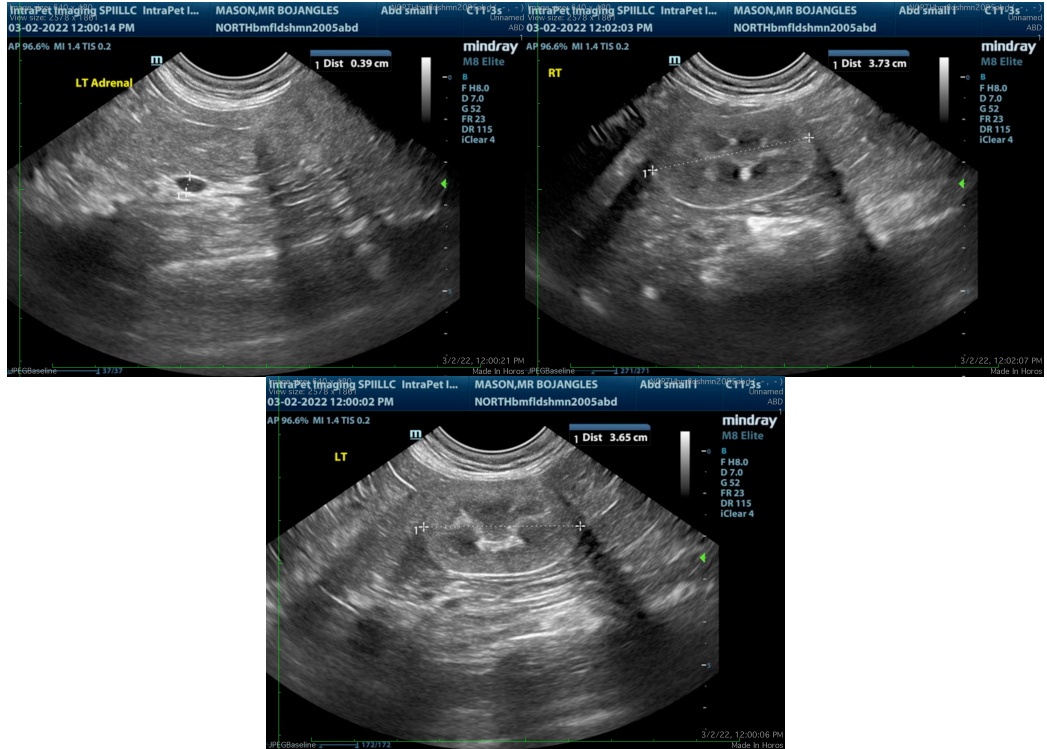
INTERPRETATION OF THE FINDINGS & FURTHER RECOMMENDATIONS

Given the urinary bladder changes, it is likely that the acute change in diabetes regulation is secondary to a urinary tract infection. Therefore, urinalysis (if not recently evaluated) and urine culture, to rule out an occult urinary tract infection, are recommended.

The changes in the gastrointestinal tract and the visibility of the pancreas in these images may be subclinical incidental findings, given the lack of clinical signs in this patient. However, the thick muscularis is suggestive of infiltrative bowel disease. Therefore, gastrointestinal malabsorption panel including TLI, PLI, folate and cobalamin to Texas A&M GI laboratory is recommended for further evaluation of GI and pancreatic function.

If gastrointestinal signs are present, or the decision is made to further investigate the thick muscularis, biopsies of the gastrointestinal tract (being sure to include the ileum, if possible) should be considered.





The information and recommendations provided are based on the images presented by the referring veterinarian/sonographer. No evaluation can be communicated regarding pathology that was not visible in the image/video clips provided.

Thank you for this referral. If the clinical or image interpretation does not parallel your findings or if I can be of any further assistance please contact me.

Beth Johnson, DVM, DACVIM
Beth.Johnson@sonopath.com