



## PATIENT

SweetPea LaFleur

## SPECIES

Canine

## BREED

Poodle

## SEX

FS

## AGE

9 years

## WEIGHT

6.27 kg

## INTERPRETED BY

Beth Johnson, DVM  
DACVIM

## IMAGING PERFORMED BY

Loetitia Saint-Jacques,  
LVT

## HOSPITAL NAME

Peavine Animal  
Hospital

## REFERRING VET

Dr. Baggett

## INVOICE

11510

## DATE

3/18/2026

## PRESENTING CLINICAL SIGNS

- Sweet Pea presented 3/4/26 and had senior lab work performed at that time. Her ALT was 425 U/L, AST 80 U/L, and GGT was 14 U/L. At that time a one pound weight loss was noted. No changes to appetite, urination, behavior, or defecation. Client concerned about potential exposure to chemotherapy from stepfather's cancer treatments.

Abnormal PE/Chem/CBC/UA Results: ALT 425 U/L, AST 80 U/L, GGT 14 U/L, Urine protein 2+, all else WNL.

## ULTRASONOGRAPHIC EXAMINATION OF THE ABDOMEN

### Urinary System

The urinary bladder is adequately distended with anechoic contents. No masses, inflammatory changes, echogenic sediment or cystoliths are observed. The urinary bladder, trigone and visible pelvic urethra are normal in thickness with a smooth mucosal surface.

The right kidney is normal is size (4.74 cm), shape and echogenicity. It has smooth peripheral margination. There is a normal 1:3 cortex to medulla ratio with appropriate corticomedullary distinction. A hyperechoic band parallel to the corticomedullary border is present. Non-obstructive linear multifocal hyperechoic diverticular foci with acoustic shadowing are noted. There is no evidence of pyelectasia or infarcts observed.

The left kidney is normal is size (3.98 cm), shape and echogenicity. It has smooth peripheral margination. There is a normal 1:3 cortex to medulla ratio with appropriate corticomedullary distinction. A hyperechoic band parallel to the corticomedullary border is present. Non-obstructive linear multifocal hyperechoic diverticular foci with acoustic shadowing are noted. There is no evidence of pyelectasia or infarcts observed.

### Adrenal Glands

The right adrenal gland is normal in size (0.5 cm at caudal pole, and the cranial pole is unable to be visualized in these images), shape and overall architecture, echogenicity and echotexture. Visible surrounding vasculature appears normal.

The left adrenal gland is normal in size (0.4 cm at cranial pole and 0.8 cm at caudal pole), shape and overall architecture, echogenicity and echotexture. Visible surrounding vasculature appears normal.

### Spleen

The spleen is subjectively normal in size with a normal smooth capsular contour. Parenchyma is appropriately finely textured and homogenous with normal echogenicity relative to surrounding tissue (hyperechoic to liver). No focal nodules or masses are observed. Splenic vasculature appears normal.

### Liver

The liver is subjectively normal in size with normal smooth curvilinear peripheral contour. Parenchyma is appropriately hypoechoic to the spleen in echogenicity and appropriately mildly coarse and homogenous in echotexture. No focal lesions are observed. Visible vasculature and biliary tree appear normal without distension or congestion.



**PATIENT**

SweetPea LaFleur

The gallbladder is non-distended in size. The wall is smooth without visible thickening. Luminal contents are primarily anechoic. There is no evidence of cystic or common bile duct dilation.

**SPECIES**

Canine

**Gastrointestinal**

The visible stomach wall is normal in thickness and layering. The lumen of the stomach is empty with no evidence of obstruction, foreign material or infiltrative disease. Pyloric outflow tract appears patent.

**BREED**

Poodle

The visible small intestines are normal in wall thickness and layering. Small intestinal motility appears adequate (1-3 contractions per min). The lumen of the small intestine is empty with no evidence of obstruction, foreign material or infiltrative disease.

**SEX**

FS

The visible colon is normal in wall thickness (< 0.2 cm) and layering. Contents are consistent with normal formed feces and gas.

**AGE**

9 years

**Pancreas**

The pancreas that is observed appears appropriately isoechoic to surrounding omental fat. Visible capsule is smooth and normal in contour. Visible pancreatic parenchyma is homogenous and unremarkable. There is no visible pancreatic duct dilation. There is no evidence of active peripancreatic inflammation.

**WEIGHT**

6.27 kg

**Free Abdomen**

There is no visible free peritoneal effusion noted in these images.

**INTERPRETED BY**

Beth Johnson, DVM  
DACVIM

There is no apparent pathologic lymphadenopathy noted in these images.

**ULTRASONOGRAPHIC FINDINGS**

**IMAGING PERFORMED BY**

Loetitia Saint-Jacques,  
LVT

- Bilateral Medullary rim sign with Bilateral non-obstructive dystrophic mineralization. - This finding is of unknown clinical significance and can be a normal variant, often idiopathic. Medullary rim sign can be present with renal disease including lymphoma, hypercalcemic nephropathy, Leptospirosis, tubular disease, other and should be interpreted in combination with other more specific indications of kidney disease such as isosthenuria, proteinuria, azotemia, etc. This is a common incidental finding in patients with diabetes mellitus.
- An obvious cause for the reported increased liver enzymes is not identified in these images. Microscopic disease such as Leptospirosis, bacterial cholangiohepatitis, chronic active hepatitis, copper-associated hepatotoxicity, other hepatotoxicity, other reactive hepatopathy, infiltrative neoplasia (considered unlikely), etc. cannot be definitively ruled out.

**HOSPITAL NAME**

Peavine Animal  
Hospital

**REFERRING VET**

Dr. Baggett

**INTERPRETATION OF THE FINDINGS & FURTHER RECOMMENDATIONS**

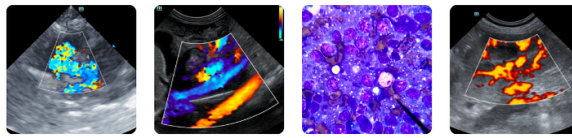
**INVOICE**

11510

Differentials for a primary hepatocellular injury liver enzyme pattern (increased ALT) depend partially on the level of increase. Mild increases (less than 2 times normal) are often a "reactive hepatopathy" or the liver's response to an insult elsewhere in the body including, but not limited to, pancreatitis, gastroenteritis, parasitic disease, dental disease, vacuolar or endocrine hepatopathy from diabetes mellitus or hyperadrenocorticism (steroid-induced), hypoadrenocorticism, certain drugs (e.g. phenobarbital, corticosteroids, azathioprine, etc.), and muscle ALT (more likely if AST and CK concurrently increased).

**DATE**

3/18/2026



**PATIENT**

SweetPea LaFleur

It is a good indicator of active liver damage (cell membrane disruption, cellular necrosis), however, if the value is increased by at least 3-4 times normal. Differentials include infectious disease, including Leptospirosis, inflammatory disease (ie. active hepatitis, copper, other), toxic insult as well as infiltrative neoplasia.

**SPECIES**

Canine

ALT levels vary in cases of vascular anomalies such as microvascular dysplasia and portosystemic shunts (PSS), but are often less significantly increased.

**BREED**

Poodle

- Testing for Leptospirosis could be considered.
- Bile acids could be considered, if tбили is not increased.

**SEX**

FS

- An empirical course of antibiotics and empirical hepatic nutraceuticals may be tried, with monitoring of ALT for improvement. If improvement is noted, antibiotics should be continued until liver enzymes either normalize or plateau (recheck every 2-3 weeks); however, if improvement is not noted and/or enzyme increase progresses, antibiotics should not be continued long term and liver tissue sampling is recommended.

**AGE**

9 years

- FNA of the liver can be performed to assess inflammatory cell type, rule in/out round cell neoplasia, etc. (if patient's coagulation status is appropriate).

**WEIGHT**

6.27 kg

- If round cell neoplasia is not diagnosed, a liver biopsy (including copper level assessment) may be required to definitively diagnose the underlying hepatopathy.

**INTERPRETED BY**

Beth Johnson, DVM  
DACVIM

Given patient's reported weight loss and proteinuria, if not already evaluated, quantification of the proteinuria via a urine protein-creatinine ratio could be considered if proteinuria is persistent in an otherwise quiet sediment.

Additionally, a blood pressure is recommended.

**IMAGING PERFORMED BY**

Loetitia Saint-Jacques,  
LVT

In the meantime, if not already evaluated, a thorough evaluation of daily caloric intake is recommended to assure an adequate daily caloric intake is occurring vs an inadvertent reduction in calories due to change in diet and/or feeding schedule, competitive eating environment, etc.

**HOSPITAL NAME**

Peavine Animal  
Hospital

**REFERRING VET**

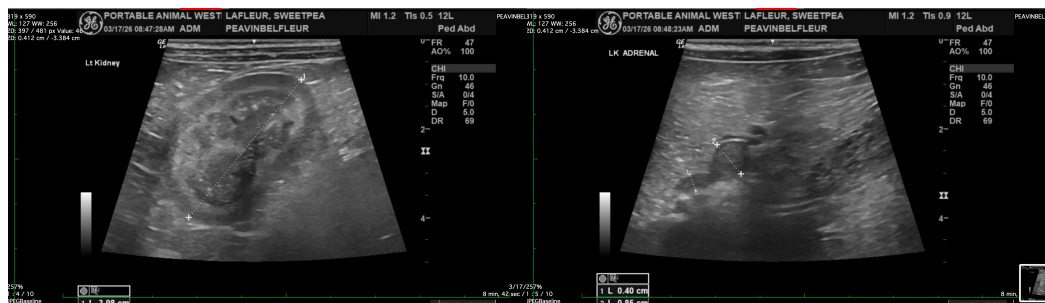Dr. Baggett

**INVOICE**

11510

**DATE**

3/18/2026



Imaging performed by



Peavine Animal Hospital Sonography, Inc.  
pawsonography@gmail.com  
530-786-8340



**Clinical Sonography & Telectology**  
Educational Teleconsultation Services™

# SonoPath

FOSTERING THE ART OF VETERINARY MEDICINE™

SonoPath.com [info@sonopath.com](mailto:info@sonopath.com) 1.800.838.4268

## PATIENT

SweetPea LaFleur

## SPECIES

Canine

## BREED

Poodle

## SEX

FS

## AGE

9 years

## WEIGHT

6.27 kg

## INTERPRETED BY

Beth Johnson, DVM  
DACVIM

## IMAGING PERFORMED BY

Loetitia Saint-Jacques,  
LVT

## HOSPITAL NAME

Peavine Animal  
Hospital

## REFERRING VET

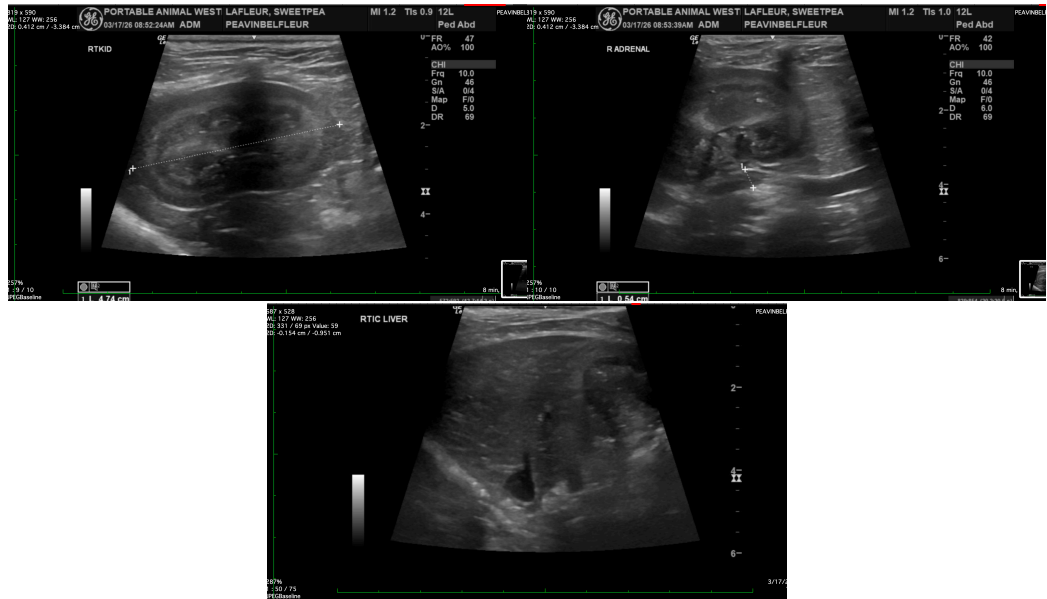
Dr. Baggett

## INVOICE

11510

## DATE

3/18/2026



The information and recommendations provided are based on the images presented by the referring veterinarian/sonographer. No evaluation can be communicated regarding pathology that was not visible in the image/video clips provided.

Thank you for this referral. If the clinical or image interpretation does not parallel your findings or if I can be of any further assistance please contact me.

**Beth Johnson, DVM, DACVIM**  
info@sonopath.com