

PATIENT

Ginger Mangus

SPECIES

Canine

BREED

Border Collie Mix

SEX

FS

AGE

3 years

WEIGHT

22.5 kg

INTERPRETED BY

Beth Johnson, DVM
DACVIM

IMAGING PERFORMED BY

Loetitia Saint-Jacques,
LVT

HOSPITAL NAME

Peavine AH

REFERRING VET

Dr. Baggett

INVOICE

11523

DATE

3/18/2026

PRESENTING CLINICAL SIGNS

- weight loss, no vomiting, still eating, 70 lbs to 49.6 lbs, chronic diarrhea. fecal all negative. hx of elevated liver values.

Abnormal PE/Chem/CBC/UA Results: ALT 161. cholesterol 59. urine protein 1+, blood/hemoglobin 3+, RBC 30-50 LABWORK attached.

ULTRASONOGRAPHIC EXAMINATION OF THE ABDOMEN

Urinary System

The urinary bladder is adequately distended with anechoic contents. No masses, inflammatory changes, echogenic sediment or cystoliths are observed. The urinary bladder, trigone and visible pelvic urethra are normal in thickness with a smooth mucosal surface.

The right kidney is normal is size (6.24 cm), shape and echogenicity. It has smooth peripheral margination. There is a normal 1:3 cortex to medulla ratio with appropriate corticomedullary distinction. A hyperechoic band parallel to the corticomedullary border is present. There is no evidence of pyelectasia, mineral or infarcts observed.

The left kidney is normal is size (5.83 cm), shape and echogenicity. It has smooth peripheral margination. There is a normal 1:3 cortex to medulla ratio with appropriate corticomedullary distinction. A hyperechoic band parallel to the corticomedullary border is present. There is no evidence of pyelectasia, mineral or infarcts observed.

Adrenal Glands

The right adrenal gland is normal in size (0.67 cm at cranial pole and 0.44 cm at caudal pole), shape and overall architecture, echogenicity and echotexture. Visible surrounding vasculature appears normal.

The left adrenal gland is normal in size (0.43 cm at cranial pole and 0.48 cm at caudal pole), shape and overall architecture, echogenicity and echotexture. Visible surrounding vasculature appears normal.

Spleen

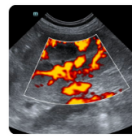
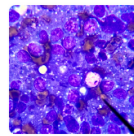
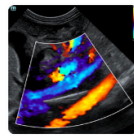
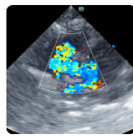
The spleen is subjectively normal in size with a normal smooth capsular contour. Parenchyma is appropriately finely textured and homogenous with normal echogenicity relative to surrounding tissue (hyperechoic to liver). No focal nodules or masses are observed. Splenic vasculature appears normal.

Liver

The liver is subjectively normal in size with normal smooth curvilinear peripheral contour. Parenchyma is appropriately hypoechoic to the spleen in echogenicity and appropriately mildly coarse and homogenous in echotexture. No focal lesions are observed. Visible vasculature and biliary tree appear normal without distension or congestion.

The gallbladder is non-distended in size. The wall is smooth without visible thickening. Luminal contents are primarily anechoic. There is no evidence of cystic or common bile duct dilation.

Gastrointestinal



PATIENT

Ginger Mangus

SPECIES

Canine

BREED

Border Collie Mix

SEX

FS

AGE

3 years

WEIGHT

22.5 kg

INTERPRETED BY

Beth Johnson, DVM
DACVIM

**IMAGING
PERFORMED BY**

Loetitia Saint-Jacques,
LVT

HOSPITAL NAME

Peavine AH

REFERRING VET

Dr. Baggett

INVOICE

11523

DATE

3/18/2026

The visible stomach wall is normal in thickness and layering. The lumen of the stomach is mildly distended with very echogenic reverberation artifact from intraluminal gas. There is no evidence of obstruction, foreign material, or infiltrative disease; however, visualization is partially inhibited by gas. Pyloric outflow tract appears patent.

The visible small intestine demonstrates areas of moderately thick muscularis layer relative to mucosa (disruption of the normal 1:3 muscularis:mucosa ratio). Small intestinal submucosa is slightly irregular, thick and hyperechoic, without evident loss of layering appreciated. The lumen of the small intestine is mildly distended with echogenic non-shadowing luminal contents and gas consistent with normal ingesta. There is no evidence of obstruction or foreign material noted.

The visible colon is normal but diffusely moderately distended with gas and soft stool.

Pancreas

The pancreas that is observed appears appropriately isoechoic to surrounding omental fat. Visible capsule is smooth and normal in contour. Visible pancreatic parenchyma is homogenous and unremarkable. There is no visible pancreatic duct dilation. There is no evidence of active peripancreatic inflammation.

Free Abdomen

There is a small amount of free fluid present in these images.

Mesenteric lymph nodes are prominent in size with swollen capsular contour. Normal elongated shape (length to width ratio) is maintained. There is no loss of parenchymal detail.

ULTRASONOGRAPHIC FINDINGS

- Moderate inflammatory bowel disease (IBD) pattern – Thick muscularis has been reported with infiltrative bowel disease including both benign inflammatory disease as well as infiltrative neoplasia such as lymphoma. No loss of layering or distinct characteristics of malignancy are present. Therefore, differentials cannot be further ranked without tissue sampling.
- Moderately Reactive lymph nodes – infiltrative neoplastic disease cannot be ruled out but is considered less likely.
- Scant/trace free fluid is of unknown origin. Differentials (unless already ruled out) could include increased hydrostatic pressure (cardiac disease and/or vascular or lymph blockage), decreased oncotic pressure (low albumin), vasculitis, paraneoplastic fluid, rupture/leakage of/from an organ (GI, GB, UB, other), blood (hemoabdomen), other.
- Bilateral medullary rim sign - This finding is of unknown clinical significance and can be a normal variant, often idiopathic. Medullary rim sign can be present with renal disease including lymphoma, hypercalcemic nephropathy, Leptospirosis, tubular disease, other and should be interpreted in combination with other more specific indications of kidney disease such as isosthenuria, proteinuria, azotemia, etc. This is a common incidental finding in patients with diabetes mellitus.

INTERPRETATION OF THE FINDINGS & FURTHER RECOMMENDATIONS

If not recently evaluated, a routine fecal/giardia exam is recommended.



PATIENT

Ginger Mangus

SPECIES

Canine

BREED

Border Collie Mix

SEX

FS

AGE

3 years

WEIGHT

22.5 kg

INTERPRETED BY

Beth Johnson, DVM
DACVIM

IMAGING PERFORMED BY

Loetitia Saint-Jacques,
LVT

HOSPITAL NAME

Peavine AH

REFERRING VET

Dr. Baggett

INVOICE

11523

DATE

3/18/2026

A gastrointestinal malabsorption panel (including cobalamin, folate, TLI and PLI) to Texas A&M GI Laboratory is recommended for further evaluation of GI and pancreatic function.

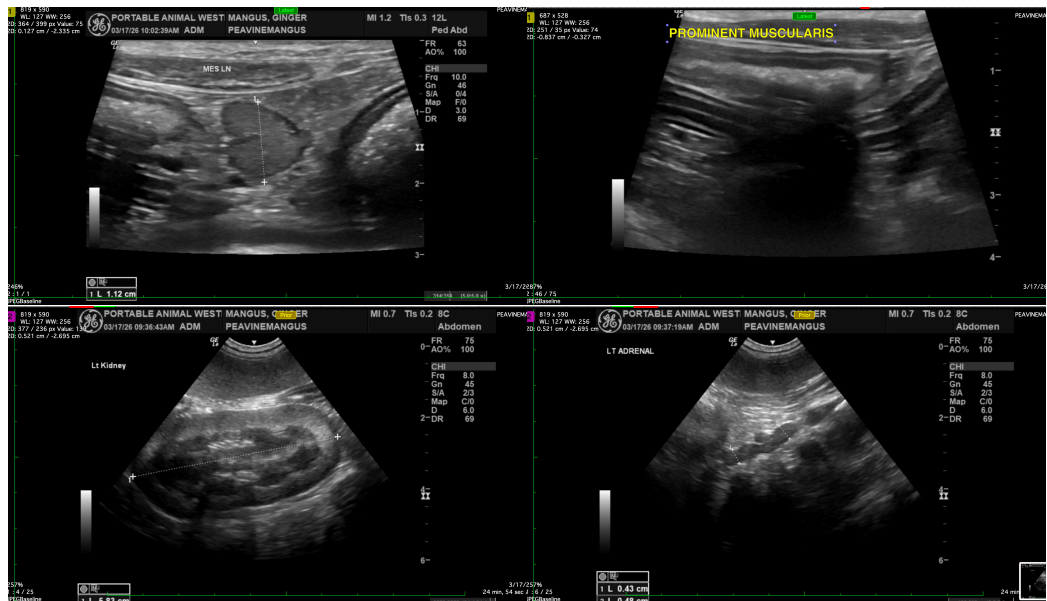
A fecal enteropathogen PCR panel to Texas A&M GI Laboratory could be considered for further evaluation of possible infectious disease. Contact lab for recommendations on how long to discontinue antibiotics (if indicated) prior to obtaining a stool sample for submission.

Pending results of above +/- a baseline cortisol is recommended. If baseline cortisol is less than 2, a full ACTH stimulation test is recommended to rule out hypoadrenocorticism.

While definitive liver pathology is not visible, in a young dog with mildly increased ALT and without another diagnosis, bile acids could also be considered if patient's total bilirubin is not increased.

In the meantime, supportive/symptomatic medical management of clinical signs is recommended, including a probiotic (such as visbiome or proviable), empirical deworming with a 5-day course of Panacur and, if tolerated, a transition in diet, based on trial-and-error response, beginning possibly with a gastrointestinal biome diet vs a hydrolyzed protein diet vs other. Some patients respond to one brand/version of a hydrolyzed protein diet better than another brand, so several brand attempts may be required.

Given the reported severity of patient's weight loss and lack of definitive obvious diagnosis, a full consultation with a veterinary internist or referral to one may be helpful. As ultimately, biopsies of the GI tract may be necessary for a definitive diagnosis and therefore to further guide medical management.



Imaging performed by



pawsonography@gmail.com
530-786-8340



Clinical Sonography & Telectology
Educational Teleconsultation Services™

SonoPath

FOSTERING THE ART OF VETERINARY MEDICINE™

SonoPath.com info@sonopath.com 1.800.838.4268

PATIENT

Ginger Mangus

SPECIES

Canine

BREED

Border Collie Mix

SEX

FS

AGE

3 years

WEIGHT

22.5 kg

INTERPRETED BY

Beth Johnson, DVM
DACVIM

IMAGING PERFORMED BY

Loetitia Saint-Jacques,
LVT

HOSPITAL NAME

Peavine AH

REFERRING VET

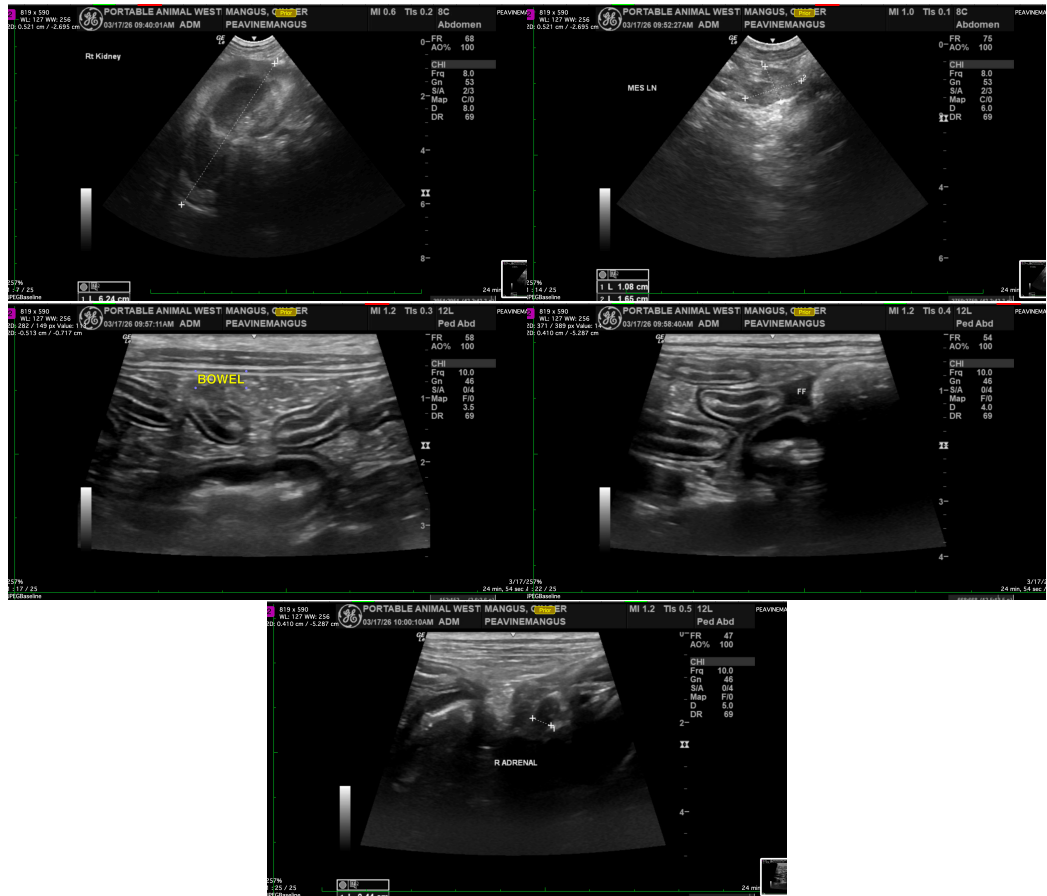Dr. Baggett

INVOICE

11523

DATE

3/18/2026



The information and recommendations provided are based on the images presented by the referring veterinarian/sonographer. No evaluation can be communicated regarding pathology that was not visible in the image/video clips provided.

Thank you for this referral. If the clinical or image interpretation does not parallel your findings or if I can be of any further assistance please contact me.

Beth Johnson, DVM, DACVIM
info@sonopath.com