



**PATIENT**

Frank Meizinger

**SPECIES**

Feline

**BREED**

DSH

**SEX**

Neutered Male

**AGE**

10 Years

**WEIGHT**

3.2 kg

**INTERPRETED BY**

Beth Johnson, DVM  
 DACVIM

**IMAGING PERFORMED BY**

Amanda Stewart

**HOSPITAL NAME**

Waterloo West Animal  
 Hospital

**REFERRING VET**

Dr. Patel

**INVOICE**

73771

**DATE**

3/18/26

**PRESENTING CLINICAL SIGNS**

Frequent emesis, hyporexia, enlarged L kidney, hyperthyroidism, hematuria.

Current Medications: Methimazole 5mg BID

Abnormal PE/Chem/CBC/UA Results: Hematuria, low USG, lymphopenia, decreased ALP, Urea Borderline between normal and elevated (13.0mmol/L) Radiographic Findings None acquired

**ULTRASONOGRAPHIC EXAMINATION OF THE ABDOMEN**

**Urinary System**

The urinary bladder is adequately distended with anechoic contents. No masses, inflammatory changes, echogenic sediment or cystoliths are observed. The urinary bladder, trigone and visible pelvic urethra are normal in thickness with a smooth mucosal surface.

Kidneys are significantly enlarged in size (left 5.16 cm, right 4.45 cm) with increased cortical echogenicity and disruption of normal corticomedullary architecture caused by multifocal heterogenous (primarily hypoechoic) nodules. A hypoechoic subcapsular rim "halo" is present. The pericapsular area is enhanced by hyperechoic fat and mesentery. No mineral is observed.

**Adrenal Glands**

The right adrenal gland is normal in size (0.32 cm), shape and overall architecture, echogenicity and echotexture. Visible surrounding vasculature appears normal.

The left adrenal gland is normal in size (0.36 cm), shape and overall architecture, echogenicity and echotexture. Visible surrounding vasculature appears normal.

**Spleen**

The spleen is subjectively normal in size with a normal smooth capsular contour. Parenchyma is appropriately finely textured and homogenous with normal echogenicity relative to surrounding tissue (hyperechoic to liver). No focal nodules or masses are observed. Splenic vasculature appears normal.

**Liver**

The liver is subjectively normal in size with normal smooth curvilinear peripheral contour. Parenchyma is appropriately hypoechoic to the spleen in echogenicity and appropriately mildly coarse and homogenous in echotexture. No focal lesions are observed. Visible vasculature and biliary tree appear normal without distension or congestion.

The gallbladder is non-distended in size. The wall is smooth without visible thickening. Luminal contents are primarily anechoic. There is no evidence of cystic or common bile duct dilation.

**Gastrointestinal**

The gastric wall is diffusely thick, measuring 0.76 cm thick, characterized by a hypoechoic wall and loss of normal layering. The lumen of the stomach is moderately fluid distended.

The visible small intestine demonstrates areas of moderately thick muscularis layer relative to mucosa (disruption of the normal 1:3 muscularis:mucosa ratio). Small intestinal submucosa is slightly irregular, thick and hyperechoic, without evident loss of layering appreciated. The lumen of the small intestine is empty with no evidence of obstruction or foreign material.



**PATIENT**

Frank Meizinger

The visible colon is normal in wall thickness (< 0.2 cm) and layering. Contents are consistent with normal formed feces and gas.

***Pancreas***

**SPECIES**

Feline

The pancreas that is observed appears appropriately isoechoic to surrounding omental fat. Visible capsule is smooth and normal in contour. Visible pancreatic parenchyma is homogenous and unremarkable. There is no visible pancreatic duct dilation. There is no evidence of active peripancreatic inflammation.

**BREED**

DSH

***Free Abdomen***

**SEX**

Neutered Male

There is no visible free peritoneal effusion noted in these images.

There is no apparent pathologic lymphadenopathy noted in these images.

**ULTRASONOGRAPHIC FINDINGS**

**AGE**

10 Years

- The thick gastric wall is concerning for infiltrative neoplasia such as round cell neoplasia i.e., lymphoma versus other. A benign inflammatory process can't be ruled out but is considered less likely.

**WEIGHT**

3.2 kg

- The bowel changes can be seen with benign inflammatory bowel disease or infiltrative neoplasia such as lymphoma. There are no characteristics of malignancy/loss of layering noted in the small bowel.

**INTERPRETED BY**

Beth Johnson, DVM  
 DACVIM

- The appearance of the kidneys is also concerning for an infiltrative process such as lymphoma, especially given the concurrent pathology. Having said that, a benign process i.e., glomerular or interstitial nephritis, FIP, amyloidosis, other can't be ruled out without tissue sampling.

**INTERPRETATION OF THE FINDINGS & FURTHER RECOMMENDATIONS**

**IMAGING PERFORMED BY**

Amanda Stewart

If not recently evaluated, a urinalysis and, if indicated based on urinalysis results, urine culture is recommended. If protein is present in an otherwise quiet sediment, protein quantification with a urine protein to creatinine ratio is recommended.

**HOSPITAL NAME**

Waterloo West Animal Hospital

If not recently evaluated, follow up T4 is recommended.

A gastrointestinal malabsorption panel (including cobalamin, folate, TLI and PLI) to Texas A&M GI Laboratory is recommended for further evaluation of GI and pancreatic function.

**REFERRING VET**

Dr. Patel

Ultimately tissue sampling is recommended. Fine needle aspirates of the kidneys (especially the left kidney) as well as the gastric wall could be considered if patient's coagulation status is appropriate.

**INVOICE**

73771

Other than supportive/symptomatic medical management of clinical signs, further treatment recommendations are largely dependent on results of the above.

**DATE**

3/18/26



**PATIENT**

Frank Meizinger

**SPECIES**

Feline

**BREED**

DSH

**SEX**

Neutered Male

**AGE**

10 Years

**WEIGHT**

3.2 kg

**INTERPRETED BY**

Beth Johnson, DVM  
 DACVIM

**IMAGING PERFORMED BY**

Amanda Stewart

**HOSPITAL NAME**

Waterloo West Animal  
 Hospital

**REFERRING VET**

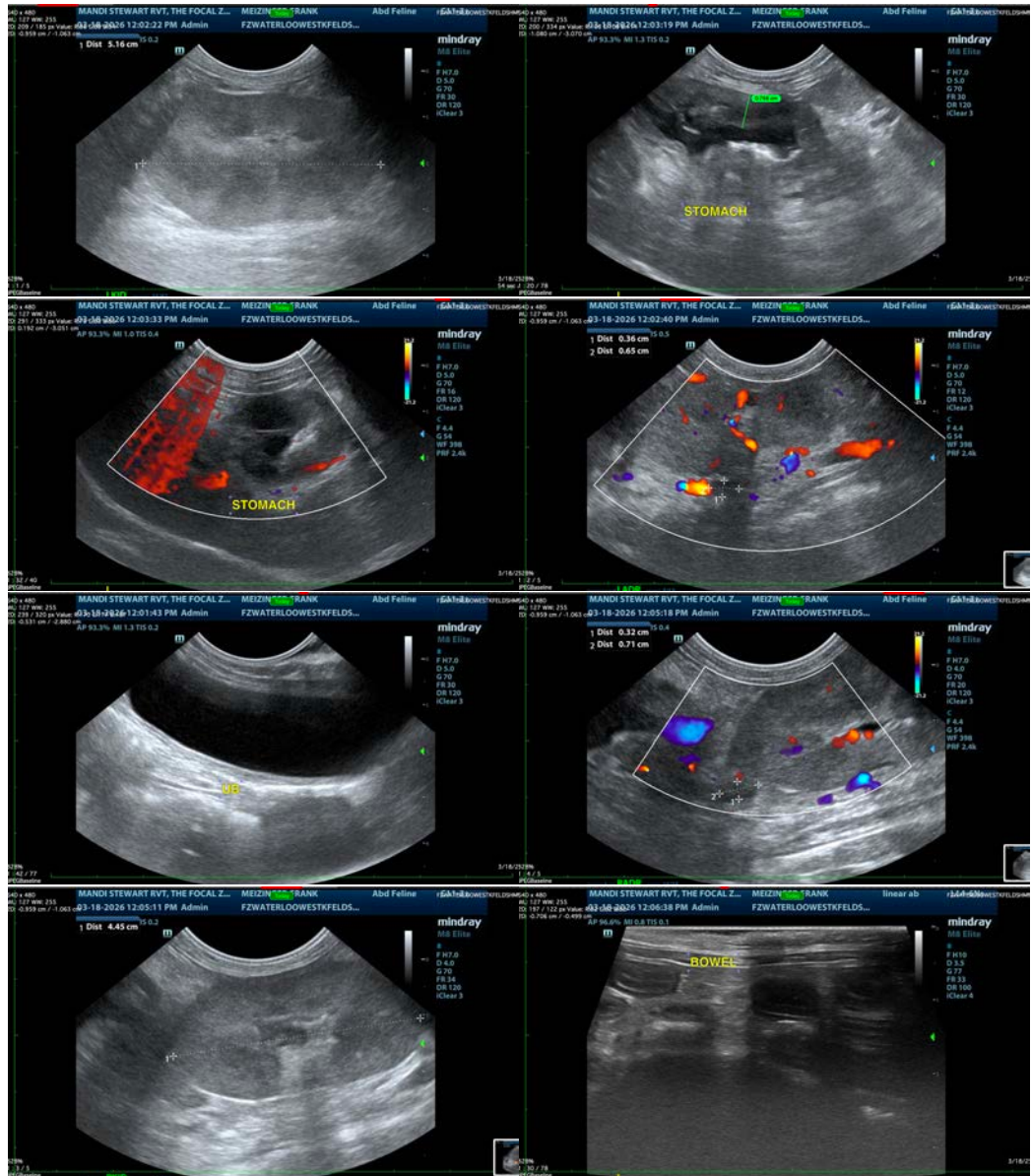
Dr. Patel

**INVOICE**

73771

**DATE**

3/18/26



The information and recommendations provided are based on the images presented by the referring veterinarian/sonographer. No evaluation can be communicated regarding pathology that was not visible in the image/video clips provided.

Thank you for this referral. If the clinical or image interpretation does not parallel your findings or if I can be of any further assistance please contact me.

**Beth Johnson, DVM, DACVIM**  
 info@sonopath.com