



## PATIENT

Eevee Franke

## SPECIES

Canine

## BREED

Chihuahua x

## SEX

Spayed Female

## AGE

6 Years

## WEIGHT

19 lbs

## INTERPRETED BY

Beth Johnson, DVM  
DACVIM

## IMAGING PERFORMED BY

Jessica Milligan, DVM

## HOSPITAL NAME

Dockside Veterinary  
Imaging

## REFERRING VET

David Fogelberg, DVM

## INVOICE

73762

## DATE

3/18/26

## PRESENTING CLINICAL SIGNS

CBC/mini chemistry done for pre-op lab work towards dental cleaning. ALT elevated at 265. Pre- and Post Prandial Bile Acid Assay was recommended. Both Pre- and Post results were elevated at 14.5umol/L(pre) and 32.4umol/L(post). Patient not symptomatic.

## ULTRASONOGRAPHIC EXAMINATION OF THE ABDOMEN

### Urinary System

Urinary bladder is only mildly distended. Visible contents are anechoic. Urinary bladder wall is unable to be fully assessed for pathology without further distension. No visible masses or definitive cystoliths are observed. The trigone and visible pelvic urethra are normal thickness with a smooth mucosal surface. In the face of urinary signs and/or suspected urinary bladder pathology, reassessment after complete filling is recommended.

The right kidney is normal in size (4.12 cm), shape and echogenicity. It has smooth peripheral margination. There is a normal 1:3 cortex to medulla ratio with appropriate corticomedullary distinction. There is no evidence of pyelectasia, mineral or infarcts observed.

The left kidney is normal in size (4.05 cm), shape and echogenicity. It has smooth peripheral margination. There is a normal 1:3 cortex to medulla ratio with appropriate corticomedullary distinction. There is no evidence of pyelectasia, mineral or infarcts observed.

### Adrenal Glands

The right adrenal gland is normal in size (0.60 cm at cranial pole and 0.40 cm at caudal pole), shape and overall architecture, echogenicity and echotexture. Visible surrounding vasculature appears normal.

The left adrenal gland is normal in size (0.30 cm at cranial pole and 0.30 cm at caudal pole), shape and overall architecture, echogenicity and echotexture. Visible surrounding vasculature appears normal.

### Spleen

The spleen is subjectively normal in size with a normal smooth capsular contour. Parenchyma is appropriately finely textured and homogenous with normal echogenicity relative to surrounding tissue (hyperechoic to liver). No focal nodules or masses are observed. Splenic vasculature appears normal.

### Liver

The liver is subjectively normal in size with normal smooth curvilinear peripheral contour. Parenchyma is appropriately hypoechoic to the spleen in echogenicity and appropriately mildly coarse and homogenous in echotexture. No focal lesions are observed. Visible vasculature and biliary tree appear normal without distension or congestion.

Gallbladder is moderately distended with anechoic bile as well as suspended and gravity dependent echogenic debris. The wall is smooth without visible thickening. There is no evidence of cystic or CBD dilation. There is no evidence of effusion or inflammation.

### Gastrointestinal

The visible stomach wall is normal in thickness and layering. The lumen of the stomach is mildly distended with a small to moderate amount of echogenic non-shadowing luminal contents and gas



## PATIENT

Eevee Franke

## SPECIES

Canine

## BREED

Chihuahua x

## SEX

Spayed Female

## AGE

6 Years

## WEIGHT

19 lbs

## INTERPRETED BY

Beth Johnson, DVM  
DACVIM

## IMAGING PERFORMED BY

Jessica Milligan, DVM

## HOSPITAL NAME

Dockside Veterinary  
Imaging

## REFERRING VET

David Fogelberg, DVM

## INVOICE

73762

## DATE

3/18/26

consistent with normal ingesta. There is no evidence of obstruction, foreign material or infiltrative disease. Pyloric outflow tract appears patent.

The visible small intestines are normal in wall thickness and layering. Small intestinal motility appears adequate (1-3 contractions per min). The lumen of the small intestine is empty with no evidence of obstruction, foreign material or infiltrative disease.

The visible colon is normal in wall thickness (< 0.2 cm) and layering. Contents are consistent with normal formed feces and gas.

### **Pancreas**

The pancreas that is observed appears appropriately isoechoic to surrounding omental fat. Visible capsule is smooth and normal in contour. Visible pancreatic parenchyma is homogenous and unremarkable. There is no visible pancreatic duct dilation. There is no evidence of active peripancreatic inflammation.

### **Free Abdomen**

There is no visible free peritoneal effusion noted in these images.

There is no apparent pathologic lymphadenopathy noted in these images.

### **ULTRASONOGRAPHIC FINDINGS**

- Mild gallbladder debris - Cholecystic debris is of unknown clinical significance. It can be seen with biliary stasis from fasting or illness. Cholecystic debris is not necessarily related to hepatobiliary disease. Echogenic bile is most commonly an incidental finding in dogs and should be interpreted in combination with clinical signs such as nausea, inappetence, cranial abdominal discomfort and/or laboratory changes such as increased ALP and/or increased Tbili.
- Otherwise, an obvious cause for the reported increased liver enzymes is not identified in these images. Microscopic disease such as Leptospirosis, bacterial cholangiohepatitis, chronic active hepatitis, copper-associated hepatotoxicity, other hepatotoxicity, other reactive hepatopathy, infiltrative neoplasia (considered unlikely), etc. cannot be definitively ruled out.

### **INTERPRETATION OF THE FINDINGS & FURTHER RECOMMENDATIONS**

Differentials for a primary hepatocellular injury liver enzyme pattern (increased ALT) depend partially on the level of increase. Mild increases (less than 2 times normal) are often a "reactive hepatopathy" or the liver's response to an insult elsewhere in the body including, but not limited to, pancreatitis, gastroenteritis, parasitic disease, dental disease, vacuolar or endocrine hepatopathy from diabetes mellitus or hyperadrenocorticism (steroid-induced), hypoadrenocorticism, certain drugs (e.g. phenobarbital, corticosteroids, azathioprine, etc.), and muscle ALT (more likely if AST and CK concurrently increased).

It is a good indicator of active liver damage (cell membrane disruption, cellular necrosis), however, if the value is increased by at least 3-4 times normal. Differentials include infectious disease, including Leptospirosis, inflammatory disease (ie. active hepatitis, copper, other), toxic insult as well as infiltrative neoplasia.

ALT levels vary in cases of vascular anomalies such as microvascular dysplasia and portosystemic shunts (PSS), but are often less significantly increased.



**PATIENT**

Eevee Franke

**SPECIES**

Canine

**BREED**

Chihuahua x

**SEX**

Spayed Female

**AGE**

6 Years

**WEIGHT**

19 lbs

**INTERPRETED BY**

Beth Johnson, DVM  
DACVIM

**IMAGING PERFORMED BY**

Jessica Milligan, DVM

**HOSPITAL NAME**

Dockside Veterinary  
Imaging

**REFERRING VET**

David Fogelberg, DVM

**INVOICE**

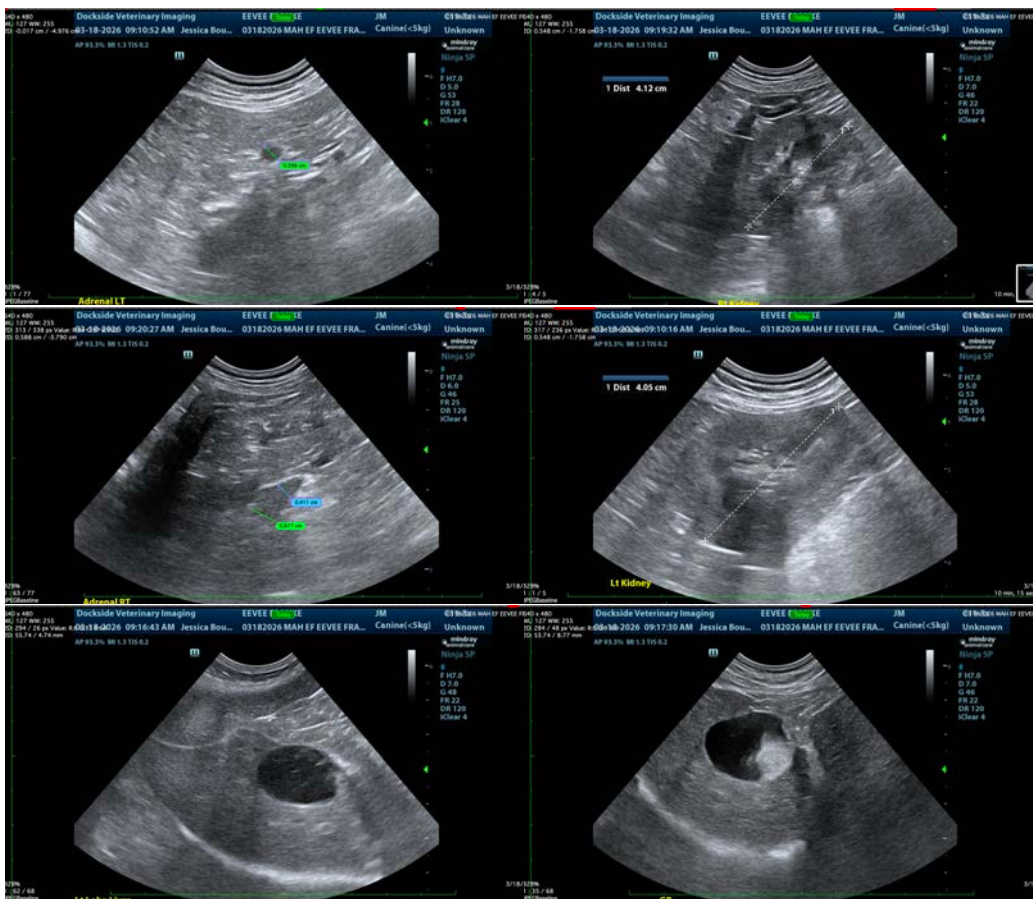
73762

**DATE**

3/18/26

- Testing for Leptospirosis could be considered.
- As were reportedly already evaluated, bile acids are recommended if tbili is not increased.
- An empirical course of antibiotics and empirical hepatic nutraceuticals may be tried, with monitoring of ALT for improvement. If improvement is noted, antibiotics should be continued until liver enzymes either normalize or plateau (recheck every 2-3 weeks); however, if improvement is not noted and/or enzyme increase progresses, antibiotics should not be continued long term and liver tissue sampling is recommended.
- FNA of the liver can be performed to assess inflammatory cell type, rule in/out round cell neoplasia, etc. (if patient's coagulation status is appropriate).
- If round cell neoplasia is not diagnosed, a liver biopsy (including copper level assessment) may be required to definitively diagnose the underlying hepatopathy.

Very mildly increased bile acid results can occur from etiologies other than primary hepatobiliary disease. Therefore, further investigation of other causes including gastrointestinal disease versus other could also be considered.





## PATIENT

Eevee Franke

## SPECIES

Canine

## BREED

Chihuahua x

## SEX

Spayed Female

## AGE

6 Years

## WEIGHT

19 lbs

## INTERPRETED BY

Beth Johnson, DVM  
DACVIM

## IMAGING PERFORMED BY

Jessica Milligan, DVM

## HOSPITAL NAME

Dockside Veterinary  
Imaging

## REFERRING VET

David Fogelberg, DVM

## INVOICE

73762

## DATE

3/18/26

The information and recommendations provided are based on the images presented by the referring veterinarian/sonographer. No evaluation can be communicated regarding pathology that was not visible in the image/video clips provided.

Thank you for this referral. If the clinical or image interpretation does not parallel your findings or if I can be of any further assistance please contact me.

**Beth Johnson, DVM, DACVIM**  
info@sonopath.com