

**DATE PRESENTING CLINICAL SIGNS**

3/16/23

Seems off for about 1 month. Coughing mostly at night. Decreased interest in food of late. No V/D. Rads reveal gas-filled intestines and stomach. Abdomen seems pendulous. Hx of MVD--last eval by cardio in Nov--stage B2. Do not appreciate pulm edema on rads. O reports freq "rumbling" of pet's stomach

PATIENT

Pippa Spegel

Current Medications: Pimo, Enalapril, tramadol for cough (12.5 mg PO BID) and Pepcid 10 mg PO BID
Lab Results: CBC--vPlt (normal for breed?). Chem--BUN, Chol, Trig, Lipase

SPECIES

Canine

Date of Previous IntraPet Ultrasound: No previous.
Sedation: Not required to complete full diagnostic ultrasound.
Stat Report: Not requested.
Imaging Performed By: Rachel Brillhart, RDMS.

BREED

Cavalier

ULTRASONOGRAPHIC EXAMINATION OF THE ABDOMEN**SEX**

Spayed Female

Urinary System

The urinary bladder is moderately distended with anechoic contents. No masses, inflammatory changes, echogenic sediment or cystoliths are observed. The urinary bladder, trigone and visible pelvic urethra are normal in thickness with a smooth mucosal surface.

AGE

7/26/10

Kidneys are bilaterally uniformly enlarged/swollen with an overall hyperechoic echogenicity and slight loss of corticomedullary definition. Normal smooth peripheral margination and shape are maintained. The renal pelvis are dilated with anechoic fluid and hyperechoic thickened pelvic fat. No overt evidence of neoplasia or mineral is observed. The perinephric area is enhanced by hyperechoic fat and mesentery. The left kidney measures 4.55 cm. The right kidney measures 4.59 cm.

WEIGHT

15 Pounds

Adrenal Glands

The right adrenal gland is normal in size (2.21 cm long x 0.65 cm at the cranial pole and 0.64 cm at the caudal pole), shape and contour. Corticomedullary structure is unremarkable. Visible surrounding vasculature appears normal.

INTERPRETED BYBeth Johnson, DVM
DACVIM

The left adrenal gland is normal in size (2.06 cm long x 0.61 cm at the cranial pole and 0.78 cm at the caudal pole), shape and contour. Corticomedullary structure is unremarkable. Visible surrounding vasculature appears normal.

HOSPITAL NAME

Alexander AH

Spleen

Spleen is generally normal in size and shape with a smooth capsular contour. Parenchyma is diffusely nodular in appearance characterized by small discrete hypoechoic nodules. Splenic vasculature appears normal.

REFERRING VET

Dr. Alexander

Liver

The liver is subjectively normal in size with normal smooth curvilinear peripheral contour. Parenchyma is appropriately hypoechoic to the spleen in echogenicity and appropriately mildly coarse and homogenous in echotexture. No focal lesions are observed. Visible vasculature and biliary tree appear normal without distension or congestion.

INVOICE

45998

The gallbladder is non-distended in size. The wall is smooth without visible thickening. Luminal contents are primarily anechoic. There is no evidence of cystic or common bile duct dilation.

Gastrointestinal

Fundic mucosal hypertrophy with hyperechoic mucosa and some mucosal remodeling is noted. There is no loss of mural detail. Layering is normal. There is mild luminal fluid accumulation. No evidence of masses/nodules or foreign material present.

The visible small intestines are normal in wall thickness and layering (canine duodenum < 0.5 cm and feline duodenum < 0.4 cm; other < 0.3 cm). Small intestinal motility appears adequate (1-3 contractions per min). The lumen of the small intestine is empty with no evidence of obstruction, foreign material or infiltrative disease.

The visible colon is normal in wall thickness (< 0.2 cm) and layering. Contents are consistent with normal formed feces and gas.

Pancreas

The observed pancreas appears appropriately isoechoic to surrounding omental fat. The capsule is mildly irregular in shape. Parenchyma is mildly heterogenous and coarse. There is no visible pancreatic duct dilation. There is no evidence of active peripancreatic inflammation.

Free Abdomen

There is no evidence of free peritoneal effusion noted in these images.

There is no apparent lymphadenopathy noted in these images.

There is no evidence of heart base or pericardial pathology noted in these images at this time. If cardiac function evaluation is desired a full echocardiogram is recommended.

PRIMARY FINDINGS

- **Pyelonephritis** – These changes are most consistent with chronic pyelonephritis. Chronic scarring and fibrosis and/or chronic nephrolith passage can also result in these pelvic dilation changes. Early infiltrative disease cannot be ruled out but is considered less likely.
- **Splenic micronodular hyperplasia pattern** – This nodular change is often associated with benign aging nodular hyperplasia. Infiltrative neoplasia, however, including both early hemangiosarcoma as well as round cell neoplasia cannot be ruled out.
- **Gastritis** – Consistent with irritation secondary to dietary indiscretion or intolerance, infection (bacterial, viral, other), parasitic or protozoal disease, toxin, other metabolic disease such as pancreatitis, other. Microulceration cannot be ruled out.

SECONDARY FINDINGS

- **Pancreatic age-related remodeling** – Mild irregularities are consistent with benign age-related change. Low-grade smoldering chronic pancreatitis cannot be ruled out and should be suspected in the face of appropriate clinical signs.

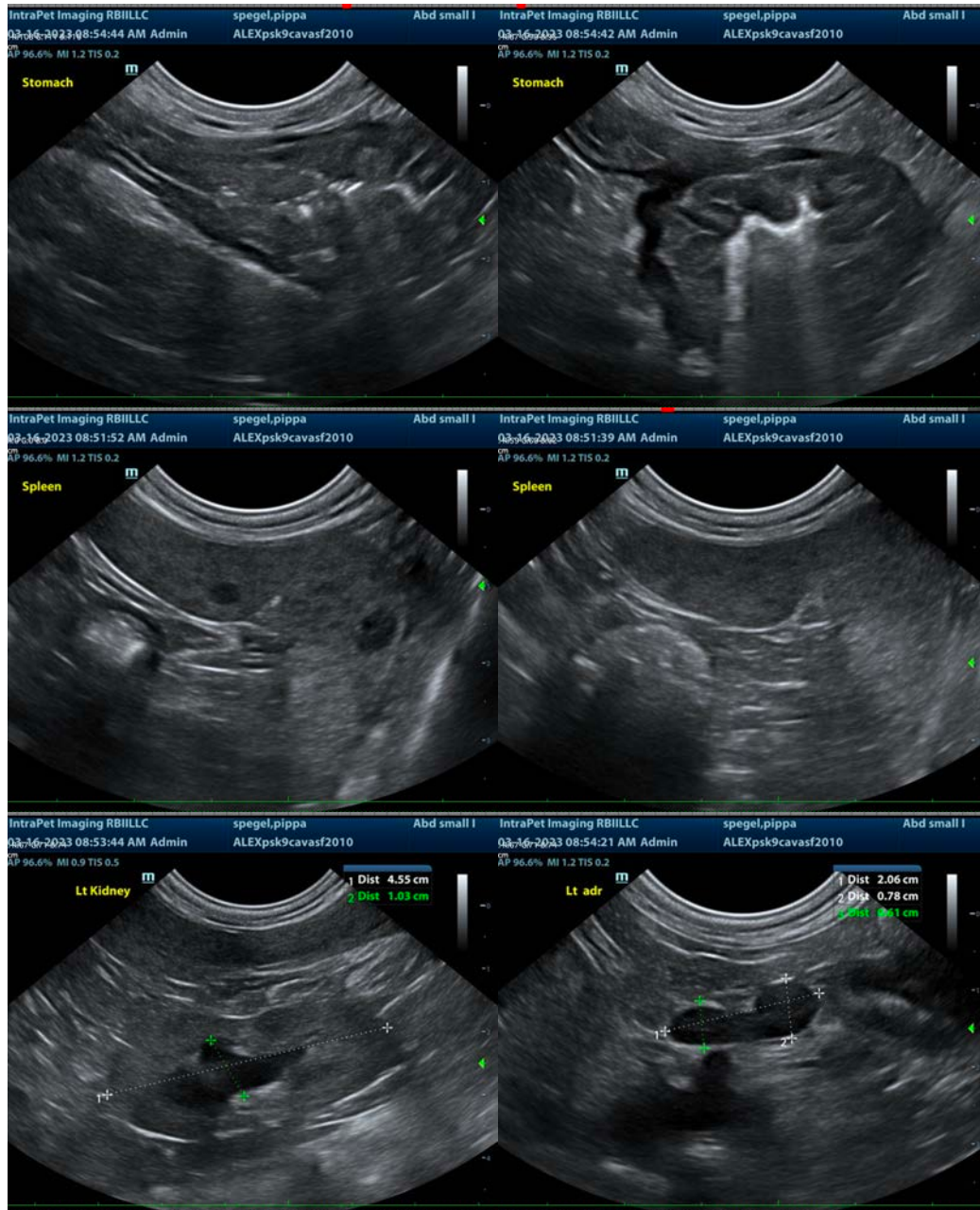
INTERPRETATION OF THE FINDINGS & FURTHER RECOMMENDATIONS

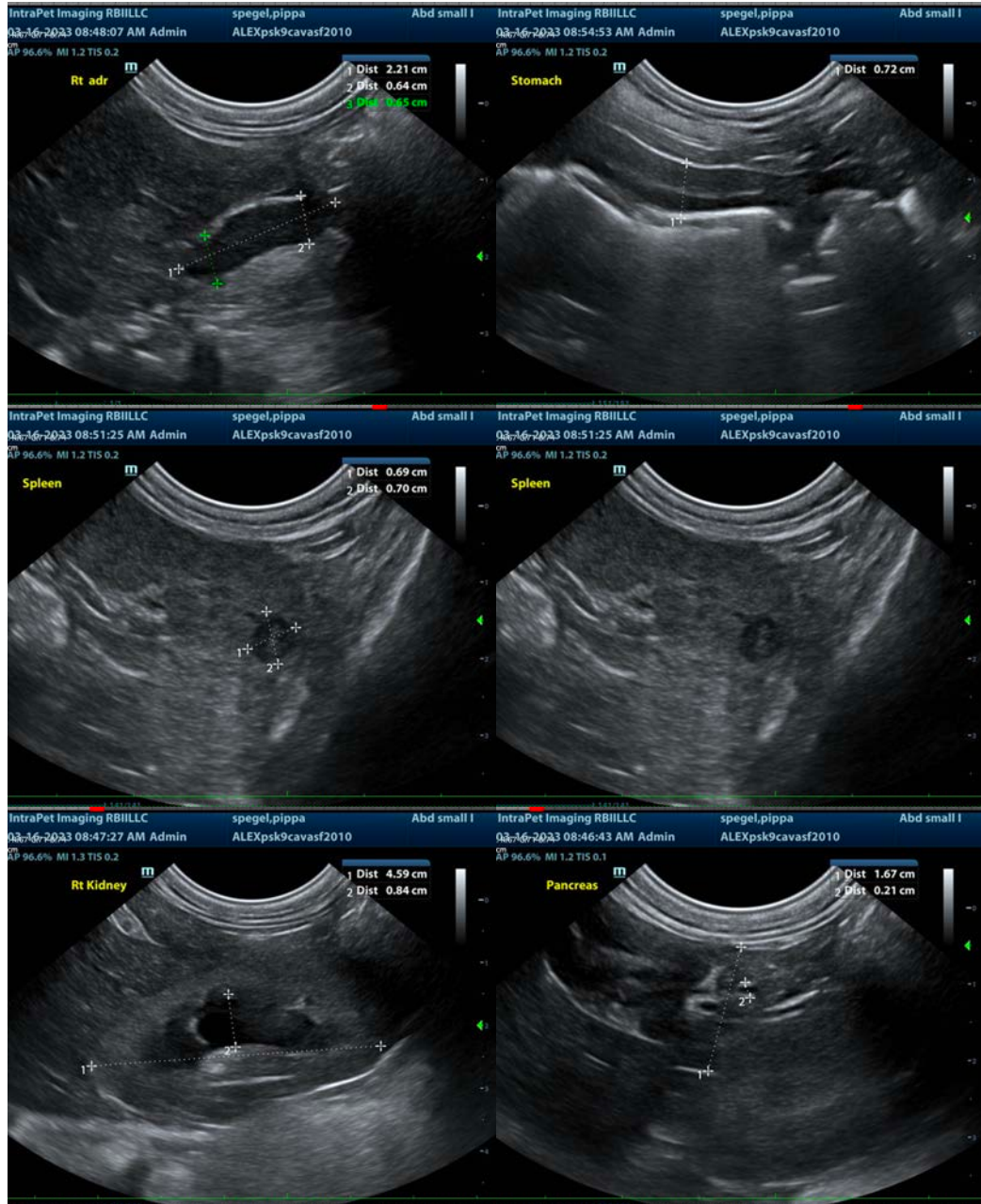
If not recently evaluated, a urinalysis and, if indicated based on urinalysis results, urine culture are recommended. If protein is present in an otherwise quiet sediment, protein quantification with a urine protein to creatinine ration is recommended.

A gastrointestinal malabsorption panel (including cobalamin, folate, TLI and PLI) to Texas A&M GI Laboratory is recommended for further evaluation of GI and pancreatic function.

A fine needle aspirate of the spleen is recommended if patient's coagulation status is appropriate.

In the meantime, supportive/symptomatic medical management of acute gastritis/gastroenteritis is recommended in the form of antiemetics, gastroprotectants including sucralfate, empirical deworming with a 5-day course of Panacur, and potentially if tolerated, a short-term course of a bland easy to digest or low-fat diet. A course of empirical helicobacter therapy could also be considered.





The information and recommendations provided are based on the images presented by the referring veterinarian/sonographer. No evaluation can be communicated regarding pathology that was not visible in the image/video clips provided.

Thank you for this referral. If the clinical or image interpretation does not parallel your findings or if I can be of any further assistance please contact me.

Beth Johnson, DVM, DACVIM
Beth.Johnson@sonopath.com