

**DATE PRESENTING CLINICAL SIGNS**

3/16/23 Patient presented on 3/9 with mass on neck. FNA=MCT. Bloodwork shows elevated liver enzymes. No clinical signs of liver disease.

**PATIENT**

Buttercup Irvine Current Medications: None listed.  
Lab Results: 3/9- ALT 473, ALP 3744. FNA of 8mm mass = MCT.  
Date of Previous IntraPet Ultrasound: No previous.  
Sedation: IV sedation.

**SPECIES**

Canine Stat Report: Not requested.  
Imaging Performed By: Rachel Brillhart, RDMS.

**BREED**

Chihuahua

**SEX**

Spayed Female

**AGE**

1/14/14

**WEIGHT**

17 Pounds

**INTERPRETED BY**

Beth Johnson, DVM  
DACVIM

**HOSPITAL NAME**

Alexander AH

**REFERRING VET**

Dr. Alexander

**INVOICE**

45999

**ULTRASONOGRAPHIC EXAMINATION OF THE ABDOMEN****Urinary System**

The urinary bladder is moderately distended with anechoic contents. No masses, inflammatory changes, echogenic sediment or cystoliths are observed. The urinary bladder, trigone and visible pelvic urethra are normal in thickness with a smooth mucosal surface.

The right kidney is normal in size (4.54 cm), shape and echogenicity. It has smooth peripheral margination. There is a normal 1:3 cortex to medulla ratio with appropriate corticomedullary distinction. There is no evidence of pyelectasia, mineral or infarcts observed.

The left kidney is normal in size (4.39 cm), shape and echogenicity. It has smooth peripheral margination. There is a normal 1:3 cortex to medulla ratio with appropriate corticomedullary distinction. There is no evidence of pyelectasia, mineral or infarcts observed.

**Adrenal Glands**

The right adrenal gland is normal in size (1.8 cm long x 0.78 cm at the cranial pole and 0.52 cm at the caudal pole), shape and contour. Corticomedullary structure is unremarkable. Visible surrounding vasculature appears normal.

The left adrenal gland is normal in size (1.77 cm long x 0.52 cm at the cranial pole and 0.58 cm at the caudal pole), shape and contour. Corticomedullary structure is unremarkable. Visible surrounding vasculature appears normal.

**Spleen**

The spleen is subjectively normal in size with a normal smooth capsular contour. Parenchyma is appropriately finely textured and homogenous with normal echogenicity relative to surrounding tissue (hyperechoic to liver). No focal nodules or masses are observed. Splenic vasculature appears normal.

**Liver**

Liver is subjectively enlarged with mildly irregular margins. Parenchyma is heterogenous characterized by multiple poorly defined hypoechoic nodules within otherwise hyperechoic liver parenchyma. Specifically, and more discretely, there is an approximately 1.0 cm hypo- to anechoic cystic appearing nodule in the caudal left liver, and a large 2.0 cm x 4.0 cm homogeneous but hypoechoic nodule in the caudal right liver. Visible vasculature and biliary tree appear normal without distension or congestion.

Gallbladder is moderately distended with anechoic bile as well as mild suspended and gravity dependent echogenic debris. The wall is smooth without visible thickening. There is no evidence of cystic or CBD dilation. There is no evidence of effusion or inflammation.

### ***Gastrointestinal***

The visible stomach wall is normal in thickness and layering. The lumen of the stomach is mildly distended with very echogenic reverberation artifact from intraluminal gas. There is no evidence of obstruction, foreign material or infiltrative disease; however, complete visualization of far wall is partially inhibited by gas. Pyloric outflow tract appears patent.

The visible small intestines are normal in wall thickness and layering (canine duodenum < 0.5 cm and feline duodenum < 0.4 cm; other < 0.3 cm). Small intestinal motility appears adequate (1-3 contractions per min). The lumen of the small intestine is empty with no evidence of obstruction, foreign material or infiltrative disease.

The visible colon is normal in wall thickness (< 0.2 cm) and layering. Contents are consistent with normal formed feces and gas.

### ***Pancreas***

The pancreatic parenchyma is appropriately isoechoic to surrounding tissue. Visible capsule is smooth and normal in contour. There is no visible pancreatic duct dilation. There is no evidence of active peripancreatic inflammation.

### ***Free Abdomen***

There is no evidence of free peritoneal effusion noted in these images.

There is no apparent lymphadenopathy noted in these images.

There is no evidence of heart base or pericardial pathology noted in these images at this time. If cardiac function evaluation is desired a full echocardiogram is recommended.

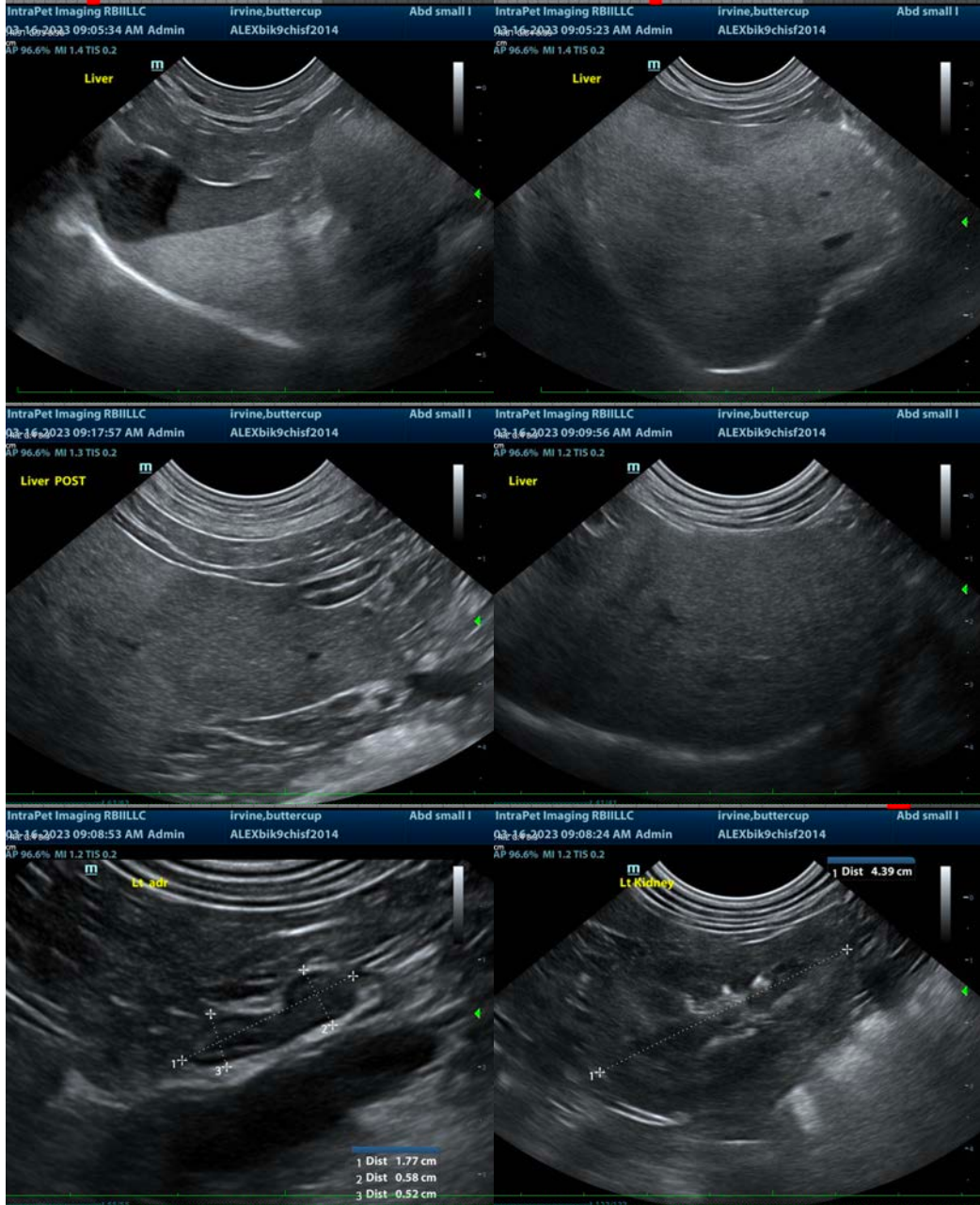
## **ULTRASONOGRAPHIC FINDINGS**

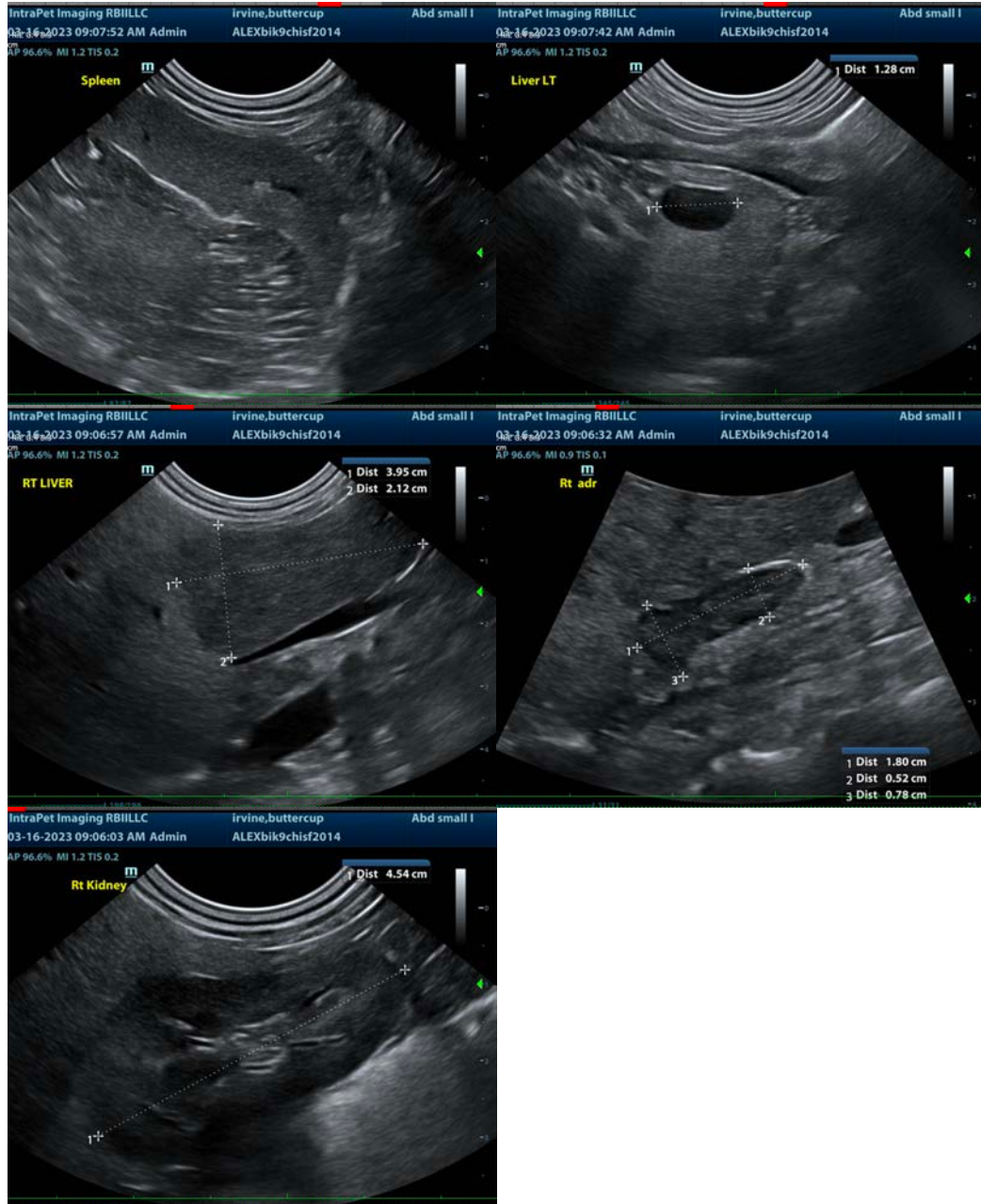
- **Heterogenous Liver with a larger, more discrete hypoechoic area** – These changes are most consistent with benign processes such as nodular hyperplasia, steroid (vacuolar) hepatopathy, extramedullary hematopoiesis or possibly chronic inflammatory disease and less commonly infiltrative round cell or metastatic neoplasia. The larger, more discrete hypoechoic area may represent the same process as is affecting the liver diffusely with the above differentials. However, infiltrative neoplasia, especially mast cell tumor, given this patient's history, can't be definitively ruled out.
- **Mild gallbladder debris** - Cholecystic debris is of unknown clinical significance. It can be seen with biliary stasis from fasting or illness. Cholecystic debris is not necessarily related to hepatobiliary disease. Echogenic bile is most commonly an incidental finding in dogs and should be interpreted in combination with clinical signs such as nausea, inappetence, cranial abdominal discomfort and/or laboratory changes such as increased ALP and/or increased Tbili.

## **INTERPRETATION OF THE FINDINGS & FURTHER RECOMMENDATIONS**

Three view thoracic radiographs are recommended for further assessment of cardio-pulmonary status as well as to further evaluate for any evidence of metastatic disease, if not recently evaluated.

As was reportedly already obtained, a fine needle aspirate of the liver, especially the caudal right liver, is recommended.





The information and recommendations provided are based on the images presented by the referring veterinarian/sonographer. No evaluation can be communicated regarding pathology that was not visible in the image/video clips provided.

Thank you for this referral. If the clinical or image interpretation does not parallel your findings or if I can be of any further assistance please contact me.

**Beth Johnson, DVM, DACVIM**  
Beth.Johnson@sonopath.com