

**DATE PRESENTING CLINICAL SIGNS**

3/16/23 3-16-23 – Alexander Animal Hospital – Dr. Alexander.
AJ Brinkerhoff

PATIENT Canine Maltese 8.5lbs MN 8/22/2012.

AJ Brinkerhoff Two-pound weight loss in 4 months with sporadic vomiting and diarrhea.

SPECIES

Canine

BREED

Maltese

SEX

Neutered Male

AGE

8/22/12

WEIGHT

8.5 Pounds

INTERPRETED BY

Beth Johnson, DVM
DACVIM

HOSPITAL NAME

Alexander AH

REFERRING VET

Dr. Alexander

INVOICE

45997

Current Medications: 2/16/23- Cerenia-24mg-1/2 SID PRN
Lab Results: 2/16/23- BW= >K(5.8), Fecal= NEG *O declined resting Cortisol at this time*
Radiographs: 2/16/23 WNLs.
Date of Previous IntraPet Ultrasound: No previous.
Sedation: Not required to complete full diagnostic ultrasound.
Stat Report: Not requested.
Imaging Performed By: Rachel Brillhart, RDMS.

ULTRASONOGRAPHIC EXAMINATION OF THE ABDOMEN**Urinary System**

Urinary bladder is only mildly distended (empty). Visible contents are anechoic. Urinary bladder wall is unable to be fully assessed for pathology without further distension. No visible masses or cystoliths are observed. The trigone and visible pelvic urethra are normal thickness with a smooth mucosal surface. If there are urinary signs and/or concern for urinary bladder pathology, reassessment after complete filling is recommended.

Prostate is normal in size, echotexture and echogenicity for a neutered male.

Kidneys are overall normal in size and shape with smooth peripheral margination. A normal 1:3 cortex to medulla ratio is maintained. The medulla and cortices are uniform in texture with some mild increased cortical echogenicity and mild loss of corticomedullary distinction, expected in this age patient. There is no evidence of pyelectasia, mineral or infarcts observed. The left kidney measures 3.5 cm. The right kidney measures 3.08 cm.

Adrenal Glands

The right adrenal gland is normal in size (1.47 cm long x 0.72 cm at the cranial pole and 0.66 cm at the caudal pole), shape and contour. Corticomedullary structure is unremarkable. Visible surrounding vasculature appears normal.

The left adrenal gland is normal in size (1.68 cm long x 0.63 cm at the cranial pole and 0.62 cm at the caudal pole), shape and contour. Corticomedullary structure is unremarkable. Visible surrounding vasculature appears normal.

Spleen

The spleen is subjectively normal in size with a normal smooth capsular contour. Parenchyma is appropriately finely textured and homogenous with normal echogenicity relative to surrounding tissue (hyperechoic to liver). No focal nodules or masses are observed. Splenic vasculature appears normal.

Liver

The liver is subjectively normal in size with normal smooth curvilinear peripheral contour. Parenchyma is appropriately hypoechoic to the spleen in echogenicity and appropriately mildly coarse and homogenous in echotexture. No focal lesions are observed. Visible vasculature and biliary tree appear normal without distension or congestion.

The gallbladder is non-distended in size. The wall is smooth without visible thickening. Luminal contents are primarily anechoic. There is no evidence of cystic or common bile duct dilation.

Gastrointestinal

The stomach wall is diffusely mildly thick, ranging between 0.70-0.94 cm with a more focal thick hypoechoic loss of layering that appears to involve the greater curvature primarily. The lumen of the stomach is mildly distended with very echogenic reverberation artifact from intraluminal gas. There is no evidence of obstruction or foreign material; however, complete visualization of far wall is partially inhibited by gas. Pyloric outflow tract appears patent.

The visible small intestines are normal in wall thickness and layering. Hyperechoic mucosal fogging or speckling is noted. Small intestinal motility appears adequate (1-3 contractions per min). The lumen is empty with no evidence of obstruction or foreign material.

The visible colon is normal in wall thickness (< 0.2 cm) and layering. Contents are consistent with normal formed feces and gas.

Pancreas

The observed pancreas appears appropriately isoechoic to surrounding omental fat. The capsule is mildly irregular in shape. Parenchyma is mildly heterogenous and coarse. There is no visible pancreatic duct dilation. There is no evidence of active peripancreatic inflammation.

Free Abdomen

There is no evidence of free peritoneal effusion noted in these images.

Prominent, hypoechoic cranial abdominal/gastric lymph nodes.

PRIMARY FINDINGS

- **Diffusely mildly thick gastric wall with a more focal concern for a gastric mass** – Top differential being infiltrative neoplasia such as round cell neoplasia (i.e., lymphoma) versus other. A benign inflammatory process is possible but considered less likely.
- **Lymphadenopathy surrounding the thick gastric wall** – This could represent a reactive lymphadenopathy. However, metastatic or infiltrative neoplastic disease is also possible and cannot be ruled out without tissue sampling.
- **Mucosal speckling** – Mucosal speckling is often present with inflammatory bowel disease (IBD). It is not specific for type or severity of disease. Mild speckling change can occur as a normal patient variant in the post-prandial state.

SECONDARY FINDINGS

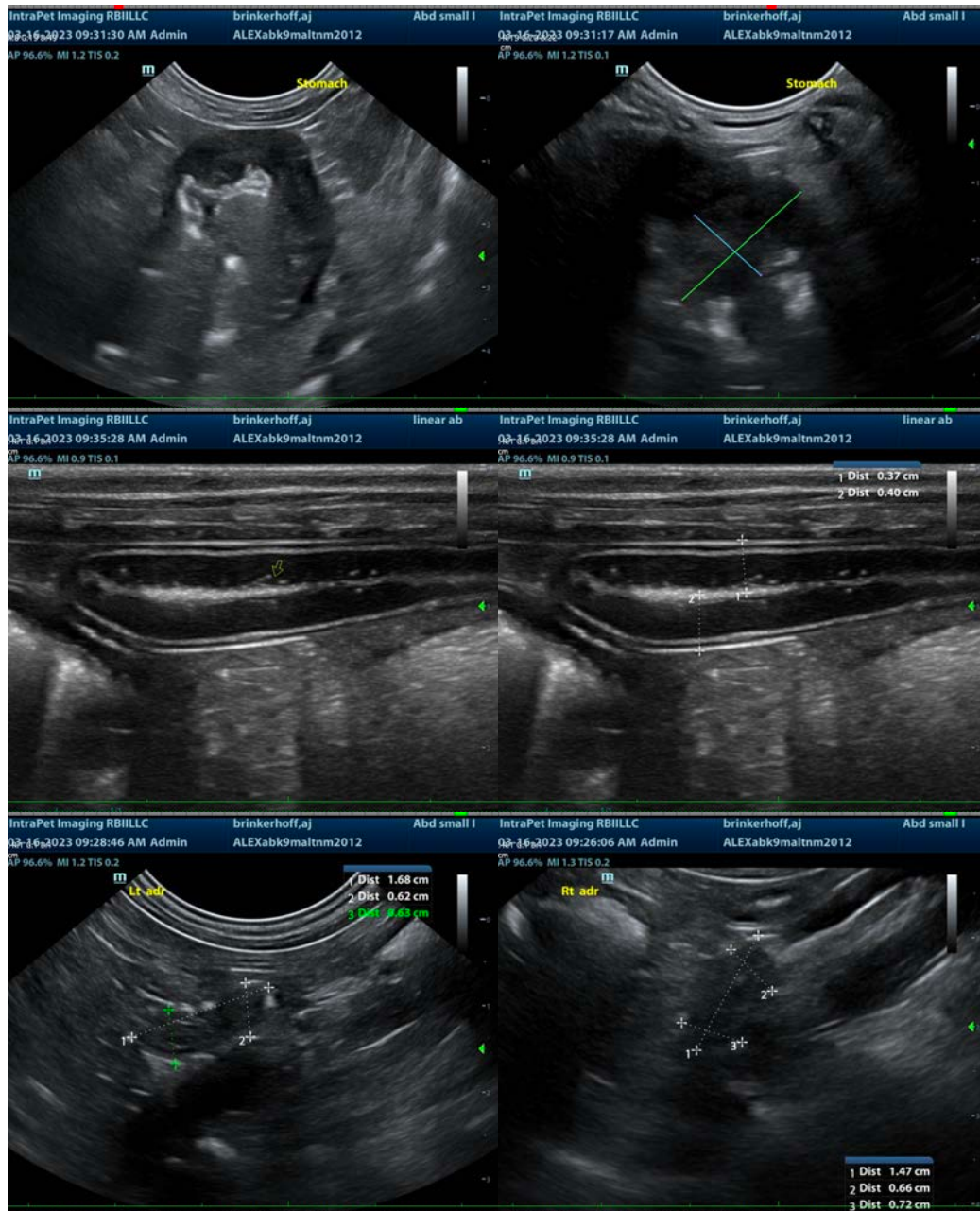
- Age related kidney changes
- **Pancreatic age-related remodeling** – Mild irregularities are consistent with benign age-related change. Low-grade smoldering chronic pancreatitis cannot be ruled out and should be suspected in the face of appropriate clinical signs.

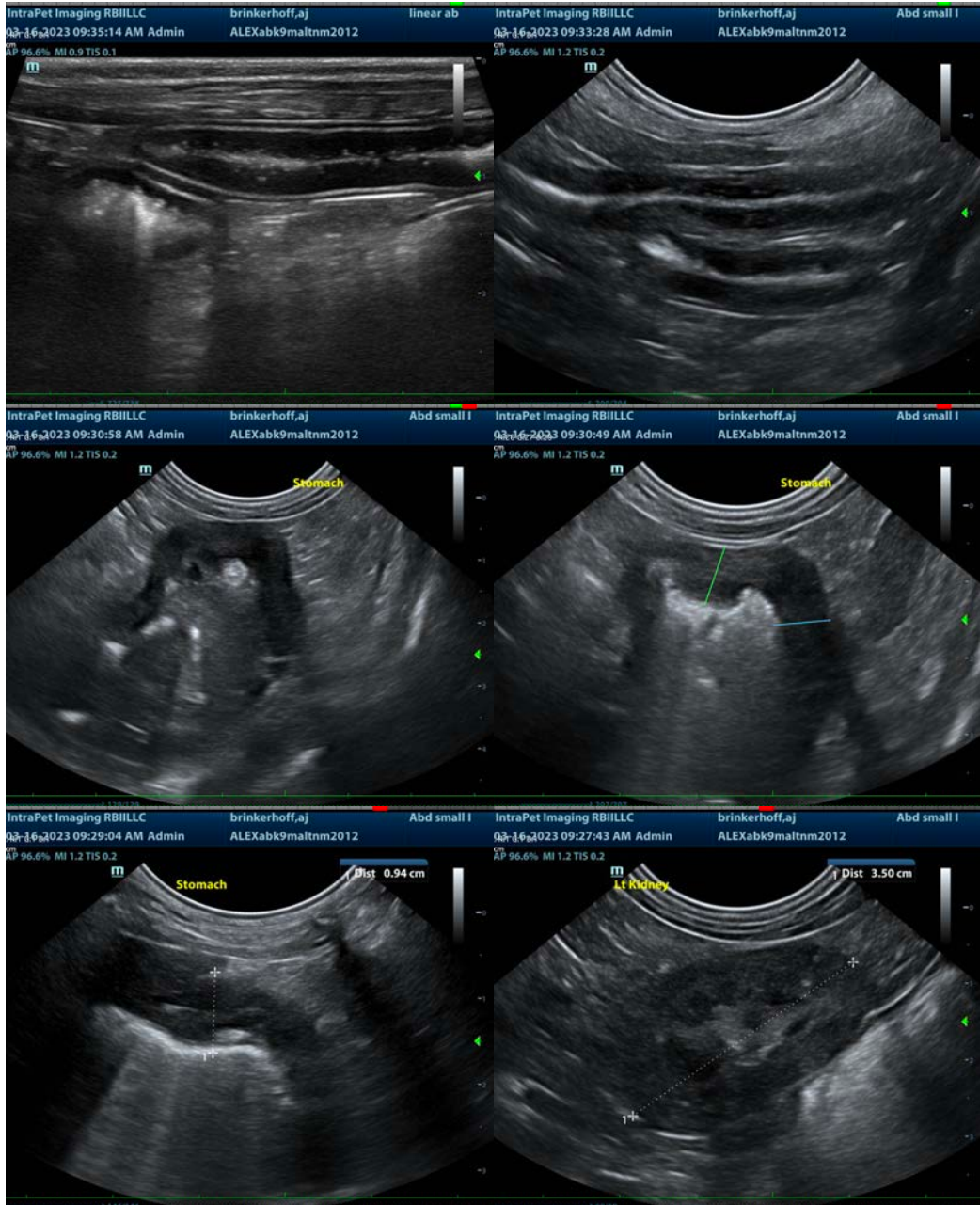
INTERPRETATION OF THE FINDINGS & FURTHER RECOMMENDATIONS

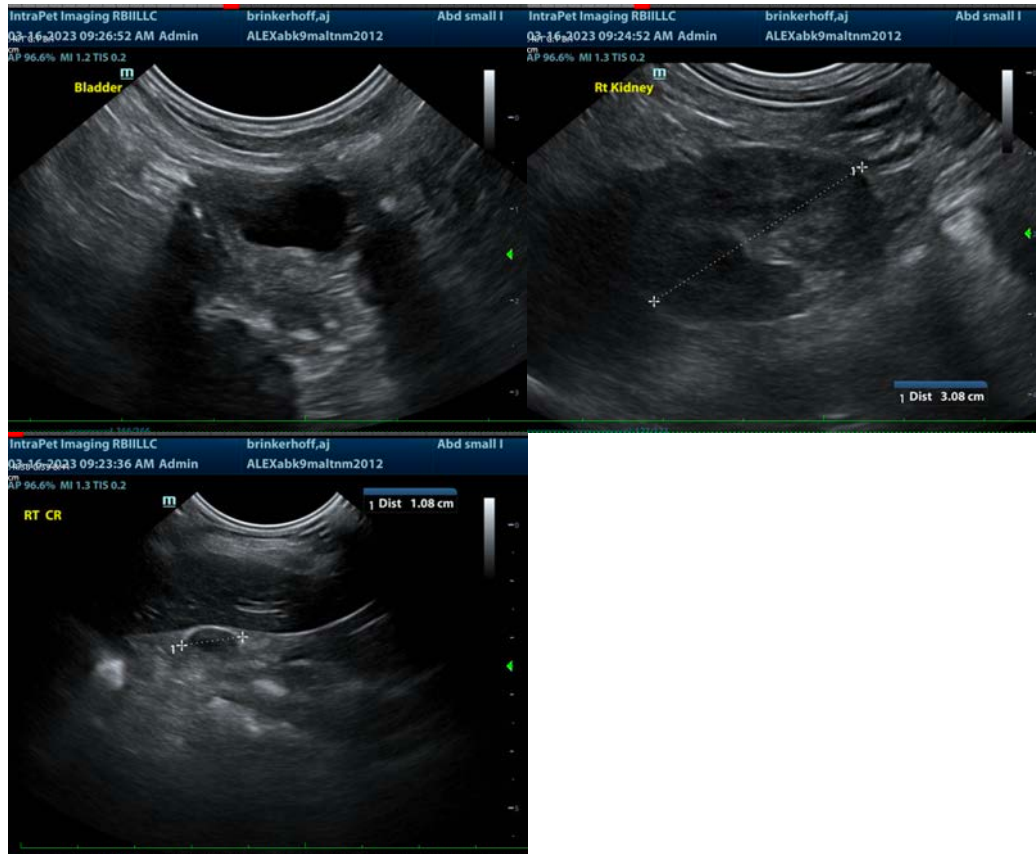
If possible, a fine needle aspirate of the thick gastric wall could be considered if patient's coagulation status is appropriate. Alternatively, upper GI gastroscopy/endoscopy could be considered for further visual

evaluation as well as biopsies of the stomach and proximal small bowel. Prior to anesthesia, however, if that option is elected, a gastrointestinal malabsorption panel (including cobalamin, folate, TLI and PLI) to Texas A&M GI Laboratory is recommended for further evaluation of GI and pancreatic function.

A baseline cortisol is recommended. If baseline cortisol is less than 2, a full ACTH stimulation test is recommended to rule out hypoadrenocorticism.







The information and recommendations provided are based on the images presented by the referring veterinarian/sonographer. No evaluation can be communicated regarding pathology that was not visible in the image/video clips provided.

Thank you for this referral. If the clinical or image interpretation does not parallel your findings or if I can be of any further assistance please contact me.

Beth Johnson, DVM, DACVIM
Beth.Johnson@sonopath.com