



PATIENT

Mr. Smith Beall

SPECIES

Canine

BREED

Poodle

SEX

Neutered Male

AGE

10 Years

WEIGHT

36 Pounds

INTERPRETED BY

Beth Johnson, DVM
DACVIM

IMAGING PERFORMED BY

Jenna Walsh, CVT

HOSPITAL NAME

West Hills AH

REFERRING VET

Dr. Fogarty

INVOICE

45899

DATE

3/15/23

PRESENTING CLINICAL SIGNS

Continuing escalation of ALKP over the last 6 months. Mild heart disease, no other concerns. Current Medications famotidine q12h Radiographic Findings WNL per previous DVM. We have not performed radiographs at our clinic Primary Question/Differential to Be Answered in This Exam etiology for elevated ALKP

Abnormal PE/Chem/CBC/UA Results: ALKP- 9/2022: 325, 11/2022: 253; 3/2023: 646

ULTRASONOGRAPHIC EXAMINATION OF THE ABDOMEN

Urinary System

The urinary bladder is moderately distended with anechoic contents. No masses, inflammatory changes, echogenic sediment or cystoliths are observed. The urinary bladder, trigone and visible pelvic urethra are normal in thickness with a smooth mucosal surface.

Prostate is normal in size, echotexture and echogenicity for a neutered male.

The right kidney is normal in size (5.97 cm), shape and echogenicity. It has smooth peripheral margination. There is a normal 1:3 cortex to medulla ratio with appropriate corticomedullary distinction. There is no evidence of pyelectasia, mineral or infarcts observed.

The left kidney is normal in size (5.7 cm), shape and echogenicity. It has smooth peripheral margination. There is a normal 1:3 cortex to medulla ratio with appropriate corticomedullary distinction. There is no evidence of pyelectasia, mineral or infarcts observed.

Adrenal Glands

The right adrenal gland is normal in size (2.41 cm long x 0.44 cm at the cranial pole and 0.68 cm at the caudal pole), shape and contour. Corticomedullary structure is unremarkable. Visible surrounding vasculature appears normal.

The left adrenal gland is normal in size (1.8 cm long x 0.67 cm at the cranial pole and 0.69 cm at the caudal pole), shape and contour. Corticomedullary structure is unremarkable. Visible surrounding vasculature appears normal.

Spleen

The spleen is subjectively normal in size with a normal smooth capsular contour. Parenchyma is appropriately finely textured and homogenous with normal echogenicity relative to surrounding tissue (hyperechoic to liver). No focal nodules or masses are observed. Splenic vasculature appears normal.

Liver

Liver is subjectively enlarged (swollen contour) without disruption of architecture. It has a normal homogenous echotexture. Parenchyma is diffusely hyperechoic characterized by less prominent than normal portal vein walls and increased echogenicity relative to the spleen and falciform fat. No focal lesions are observed. Visible vasculature and biliary tree appear normal without distension or congestion.

Gallbladder is moderately distended with anechoic bile as well as mild suspended and gravity dependent echogenic debris. The wall is smooth without visible thickening. There is no evidence of cystic or CBD dilation. There is no evidence of effusion or inflammation.



PATIENT

Mr. Smith Beall

SPECIES

Canine

BREED

Poodle

SEX

Neutered Male

AGE

10 Years

WEIGHT

36 Pounds

INTERPRETED BY

Beth Johnson, DVM
DACVIM

IMAGING PERFORMED BY

Jenna Walsh, CVT

HOSPITAL NAME

West Hills AH

REFERRING VET

Dr. Fogarty

INVOICE

45899

DATE

3/15/23

Gastrointestinal

The stomach wall is normal in thickness (canine < 0.5 cm and feline < 0.4 cm) and layering. The lumen of the stomach is empty with no evidence of obstruction, foreign material or infiltrative disease. Pyloric outflow tract appears patent.

The visible small intestines are normal in wall thickness and layering (canine duodenum < 0.5 cm and feline duodenum < 0.4 cm; other < 0.3 cm). Small intestinal motility appears adequate (1-3 contractions per min). The lumen of the small intestine is empty with no evidence of obstruction, foreign material or infiltrative disease.

The visible colon is normal in wall thickness (< 0.2 cm) and layering. Contents are consistent with normal formed feces and gas.

Pancreas

The pancreatic parenchyma is appropriately isoechoic to surrounding tissue. Visible capsule is smooth and normal in contour. There is no visible pancreatic duct dilation. There is no evidence of active peripancreatic inflammation.

Free Abdomen

There is no evidence of free peritoneal effusion noted in these images.

A prominent, hypoechoic sublumbar lymph node is measured at 1.0 cm long x 0.50 cm thick.

ULTRASONOGRAPHIC FINDINGS

- **Hyperechoic hepatomegaly** - This appearance is non-specific and most consistent with a benign steroid (endocrine) or vacuolar hepatopathy or reactive or idiopathic hepatopathy. Inflammatory and/or infiltrative disease (such as round cell neoplasia) are also possible, but considered less likely.
- **Mild gallbladder debris** - Cholecystic debris is of unknown clinical significance. It can be seen with biliary stasis from fasting or illness. Cholecystic debris is not necessarily related to hepatobiliary disease. Echogenic bile is most commonly an incidental finding in dogs and should be interpreted in combination with clinical signs such as nausea, inappetence, cranial abdominal discomfort and/or laboratory changes such as increased ALP and/or increased Tbili.
- **Sublumbar lymphadenopathy** - Both reactive lymphadenopathy as well as infiltrative neoplasia are differentials and cannot be differentiated without tissue sampling.

INTERPRETATION OF THE FINDINGS & FURTHER RECOMMENDATIONS

Differentials for an elevation in ALP are vast and non-specific. Differentials include, but are not limited to, benign nodular hyperplasia which occurs in 70% of older dogs and often does not result in an abnormal ultrasound, reactive or idiopathic/vacuolar hepatopathy, cholestasis and/or hyperadrenocorticism as well as many chronic non-hepatobiliary diseases such as chronic infections/inflammation from dental disease, IBD, neoplasia, hyperlipidemia, hypothyroidism, chronic pancreatitis, chronic stress, etc.

There is no ultrasonographic evidence of cholestasis. Adrenocortical testing such as a low dose dexamethasone suppression test could be considered if clinical signs of hyperadrenocorticism are present. Ursodiol could be considered if gallbladder sludge is noted. A fine needle aspirate of the liver could be considered if patient's coagulation status is appropriate. Otherwise, recommendations include



PATIENT

Mr. Smith Beall

addressing any other concurrent disease and monitoring. If values are progressive, recheck imaging is recommended.

SPECIES

Canine

If not already evaluated, a thorough rectal and perianal exam is recommended to rule out primary pathology, given the sublumbar lymphadenopathy.

BREED

Poodle

There is no visible intraabdominal reason to explain discomfort in this patient. If patient's temperament during ultrasound is believed to be pain versus nerves, anxiety, etc., recommendations are further assessment of possible orthopedic and/or neurologic spinal/cervical causes for discomfort.

SEX

Neutered Male

AGE

10 Years

WEIGHT

36 Pounds

INTERPRETED BY

Beth Johnson, DVM
DACVIM

IMAGING PERFORMED BY

Jenna Walsh, CVT

HOSPITAL NAME

West Hills AH

REFERRING VET

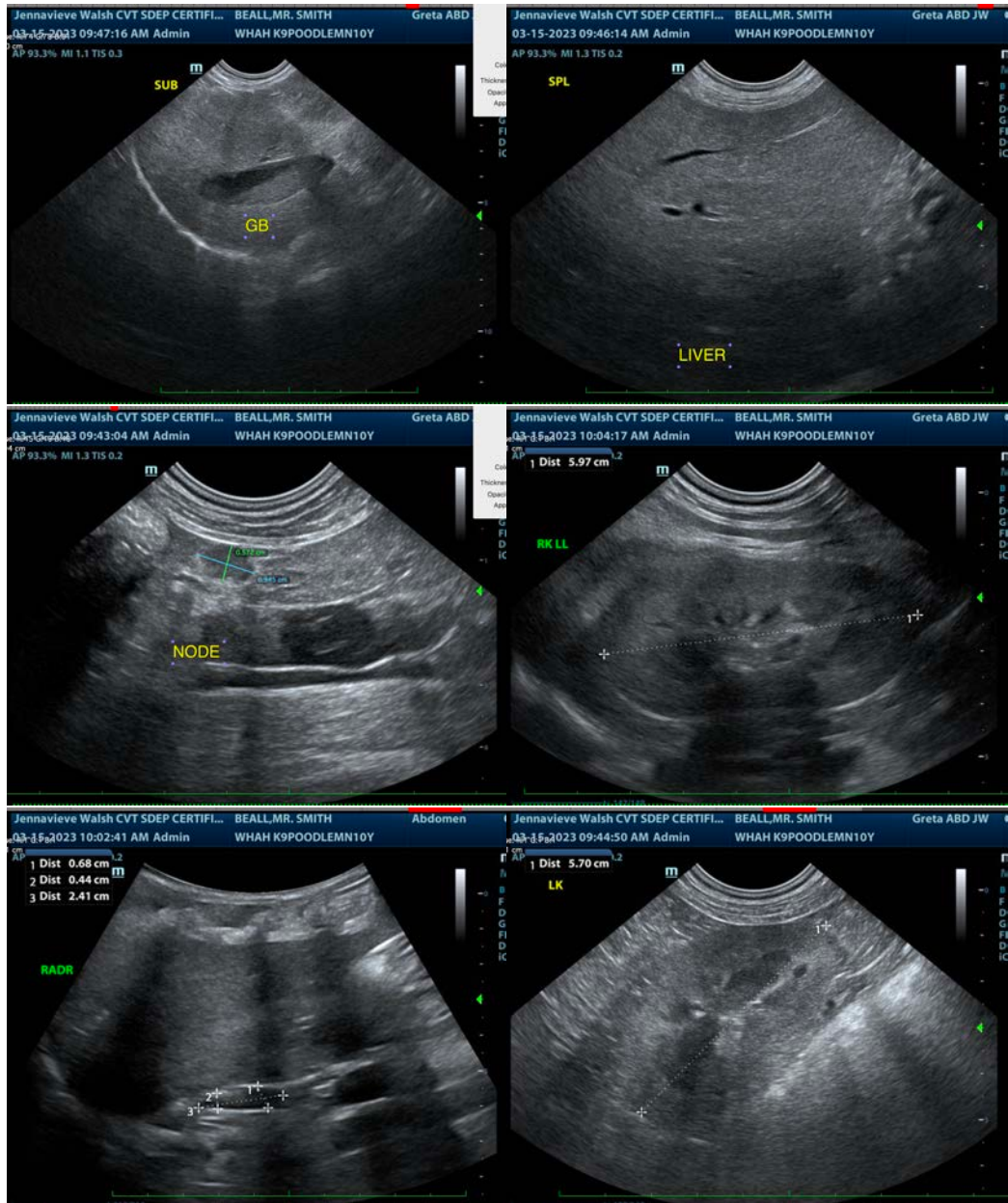
Dr. Fogarty

INVOICE

45899

DATE

3/15/23





PATIENT

Mr. Smith Beall

SPECIES

Canine

BREED

Poodle

SEX

Neutered Male

AGE

10 Years

WEIGHT

36 Pounds

INTERPRETED BY

Beth Johnson, DVM
DACVIM

IMAGING PERFORMED BY

Jenna Walsh, CVT

HOSPITAL NAME

West Hills AH

REFERRING VET

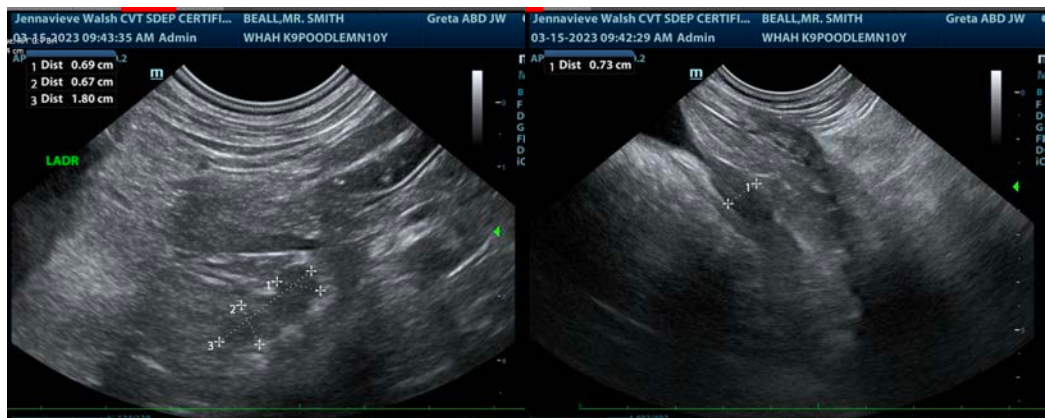
Dr. Fogarty

INVOICE

45899

DATE

3/15/23



The information and recommendations provided are based on the images presented by the referring veterinarian/sonographer. No evaluation can be communicated regarding pathology that was not visible in the image/video clips provided.

Thank you for this referral. If the clinical or image interpretation does not parallel your findings or if I can be of any further assistance please contact me.

Beth Johnson, DVM, DACVIM
Beth.Johnson@sonopath.com