



PATIENT

Molly Rosa

SPECIES

Feline

BREED

DSH

SEX

Spayed Female

AGE

9 Years 6 Months

WEIGHT

Not Provided

INTERPRETED BY

Beth Johnson, DVM
 DACVIM

IMAGING PERFORMED BY

Kerri Becker

HOSPITAL NAME

Farview Animal Clinic

REFERRING VET

Dr. Mosaad

INVOICE

73615

DATE

3/12/26

PRESENTING CLINICAL SIGNS

Vomiting, possible kidney dz, wt loss.

Abnormal PE/Chem/CBC/UA Results: WBC-17.2 rbc-10.8 neut-80 lym-14 neut-13760

ULTRASONOGRAPHIC EXAMINATION OF THE ABDOMEN

Urinary System

The urinary bladder is adequately distended with anechoic contents. No masses, inflammatory changes, echogenic sediment or cystoliths are observed. The urinary bladder, trigone and visible pelvic urethra are normal in thickness with a smooth mucosal surface.

Kidneys are overall normal in size and shape with smooth peripheral margination. A normal 1:3 cortex to medulla ratio is maintained. The medulla and cortices are uniform in texture with some mild increased cortical echogenicity and mild loss of corticomedullary distinction, expected in this age patient. There is no evidence of pyelectasia, mineral or infarcts observed. Left kidney measured 3.38 cm. Right kidney measured 3.46 cm.

Adrenal Glands

The right adrenal gland is normal in size (0.33 cm), shape and overall architecture, echogenicity and echotexture. Visible surrounding vasculature appears normal.

The left adrenal gland is normal in size (0.25 cm), shape and overall architecture, echogenicity and echotexture. Visible surrounding vasculature appears normal.

Spleen

The spleen is subjectively normal in size with a normal smooth capsular contour. Parenchyma is appropriately finely textured and homogenous with normal echogenicity relative to surrounding tissue (hyperechoic to liver). No focal nodules or masses are observed. Splenic vasculature appears normal.

Liver

The liver is subjectively normal in size with normal smooth curvilinear peripheral contour. Parenchyma is appropriately hypoechoic to the spleen in echogenicity and appropriately mildly coarse and homogenous in echotexture. No focal lesions are observed. Visible vasculature and biliary tree appear normal without distension or congestion.

The gallbladder is non-distended in size. The wall is smooth without visible thickening. Luminal contents are primarily anechoic. There is no evidence of cystic or common bile duct dilation.

Gastrointestinal

The visible stomach wall is normal in thickness and layering. The lumen of the stomach is empty with no evidence of obstruction, foreign material or infiltrative disease. Pyloric outflow tract appears patent.

The visible small intestines are normal in wall thickness and layering. Small intestinal motility appears adequate (1-3 contractions per min). The lumen of the small intestine is empty with no evidence of obstruction, foreign material or infiltrative disease.

The visible colon is normal in wall thickness (< 0.2 cm) and layering. Contents are consistent with normal formed feces and gas.



PATIENT

Molly Rosa

SPECIES

Feline

BREED

DSH

SEX

Spayed Female

AGE

9 Years 6 Months

WEIGHT

Not Provided

INTERPRETED BY

Beth Johnson, DVM
DACVIM

IMAGING PERFORMED BY

Kerri Becker

HOSPITAL NAME

Farview Animal Clinic

REFERRING VET

Dr. Mosaad

INVOICE

73615

DATE

3/12/26

Pancreas

The pancreas that is observed appears appropriately isoechoic to surrounding omental fat. Visible capsule is smooth and normal in contour. Visible pancreatic parenchyma is homogenous and unremarkable. There is no visible pancreatic duct dilation. There is no evidence of active peripancreatic inflammation.

Free Abdomen

There is no visible free peritoneal effusion noted in these images.

There is no apparent pathologic lymphadenopathy noted in these images.

ULTRASONOGRAPHIC FINDINGS

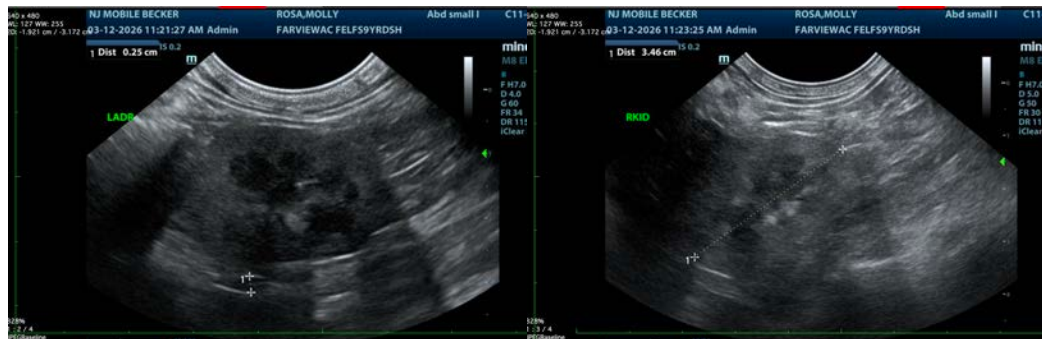
- Mild to moderate age related kidney changes.

INTERPRETATION OF THE FINDINGS & FURTHER RECOMMENDATIONS

Patient's history noted concern for possible kidney disease, which cannot be ruled out based on ultrasound. If not recently evaluated, a full general metabolic health screen is recommended to also include (in addition to the provided CBC results) a chemistry panel, electrolytes, T4 +/- free T4, a urinalysis and, if indicated based on urinalysis results, urine culture is recommended. If protein is present in an otherwise quiet sediment, protein quantification with a urine protein to creatinine ratio is recommended.

A gastrointestinal malabsorption panel (including cobalamin, folate, TLI and PLI) to Texas A&M GI Laboratory is recommended for further evaluation of GI and pancreatic function.

Pending results of above, further evaluation for possible pain (dental, orthopedic, other), upper respiratory disease or oropharyngeal disease, cardiac disease and/or neurologic disease vs other as possible causes for decreased appetite and/or unintentional weight loss is also recommended.





PATIENT

Molly Rosa

SPECIES

Feline

BREED

DSH

SEX

Spayed Female

AGE

9 Years 6 Months

WEIGHT

Not Provided

INTERPRETED BY

Beth Johnson, DVM
DACVIM

IMAGING PERFORMED BY

Kerri Becker

HOSPITAL NAME

Farview Animal Clinic

REFERRING VET

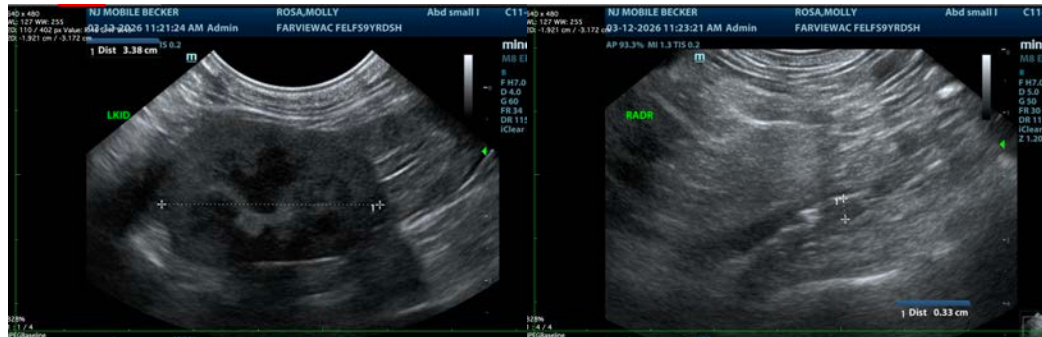
Dr. Mosaad

INVOICE

73615

DATE

3/12/26



The information and recommendations provided are based on the images presented by the referring veterinarian/sonographer. No evaluation can be communicated regarding pathology that was not visible in the image/video clips provided.

Thank you for this referral. If the clinical or image interpretation does not parallel your findings or if I can be of any further assistance please contact me.

Beth Johnson, DVM, DACVIM
info@sonopath.com