

PATIENT

Suwaay Hummel

SPECIES

Canine

BREED

Lab x

SEX

Spayed Female

AGE

13 Years

WEIGHT

54 lbs

INTERPRETED BY

Beth Johnson, DVM
 DACVIM

IMAGING PERFORMED BY

Rebecca Hamilton

HOSPITAL NAME

Willakenzie Animal
 Clinic

REFERRING VET

Dr. Brandt

INVOICE

73579

DATE

3/11/26

PRESENTING CLINICAL SIGNS

Screening labs on 1/23/26: SDMA 15, ALT 153, ALP 223, Chol 470. On 2/24/26: SDMA 17, aST 59, ALP 275, Bilirubin 0.1, Chol 423. Advised to start Denamarin on 1/27, Bravecto.

ULTRASONOGRAPHIC EXAMINATION OF THE ABDOMEN

Urinary System

The urinary bladder is adequately distended with anechoic contents. No masses, inflammatory changes, echogenic sediment or cystoliths are observed. The urinary bladder, trigone and visible pelvic urethra are normal in thickness with a smooth mucosal surface.

The right kidney is normal is size (6.27 cm), shape and echogenicity. It has smooth peripheral margination. There is a normal 1:3 cortex to medulla ratio with appropriate corticomedullary distinction. There is no evidence of pyelectasia, mineral or infarcts observed.

The left kidney is normal is size (6.14 cm), shape and echogenicity. It has smooth peripheral margination. There is a normal 1:3 cortex to medulla ratio with appropriate corticomedullary distinction. There is no evidence of pyelectasia, mineral or infarcts observed.

Adrenal Glands

The right adrenal gland is normal in size (1.0 cm at cranial pole and 0.54 cm at caudal pole), shape and overall architecture, echogenicity and echotexture. Visible surrounding vasculature appears normal.

The left adrenal gland is normal in size (0.62 cm at cranial pole and 0.75 cm at caudal pole), shape and overall architecture, echogenicity and echotexture. Visible surrounding vasculature appears normal.

Spleen

The spleen is subjectively normal in size with a normal smooth capsular contour. Parenchyma is appropriately finely textured and homogenous with normal echogenicity relative to surrounding tissue (hyperechoic to liver). No focal nodules or masses are observed. Splenic vasculature appears normal.

Liver

The liver is subjectively normal in size with normal smooth curvilinear peripheral contour. Parenchyma is appropriately hypoechoic to the spleen in echogenicity and appropriately mildly coarse and homogenous in echotexture. No focal lesions are observed. Visible vasculature and biliary tree appear normal without distension or congestion.

Gallbladder is moderately distended with anechoic bile as well as suspended and gravity dependent echogenic debris. Some mineral/sand debris with shadowing +/- small cholecystoliths with no visible evidence of obstruction is noted. The wall is smooth without visible thickening. There is no evidence of cystic or CBD dilation. There is no evidence of effusion or inflammation.

Gastrointestinal

The visible stomach wall is normal in thickness and layering. The lumen of the stomach is empty with no evidence of obstruction, foreign material or infiltrative disease. Pyloric outflow tract appears patent.



PATIENT	The visible small intestines are normal in wall thickness and layering. Small intestinal motility appears adequate (1-3 contractions per min). The lumen of the small intestine is empty with no evidence of obstruction, foreign material or infiltrative disease.
Suwaay Hummel	
SPECIES	The visible colon is normal in wall thickness (< 0.2 cm) and layering. Contents are consistent with normal formed feces and gas.
Canine	
BREED	<i>Pancreas</i>
Lab x	The pancreas that is observed appears appropriately isoechoic to surrounding omental fat. Visible capsule is smooth and normal in contour. Visible pancreatic parenchyma is homogenous and unremarkable. There is no visible pancreatic duct dilation. There is no evidence of active peripancreatic inflammation.
SEX	<i>Free Abdomen</i>
Spayed Female	There is no visible free peritoneal effusion noted in these images.
AGE	There is no apparent pathologic lymphadenopathy noted in these images.
13 Years	
WEIGHT	ULTRASONOGRAPHIC FINDINGS
54 lbs	<ul style="list-style-type: none"> Moderate gallbladder debris - Cholecystic debris is of unknown clinical significance. It can be seen with biliary stasis from fasting or illness. Cholecystic debris is not necessarily related to hepatobiliary disease. Echogenic bile is most commonly an incidental finding in dogs and should be interpreted in combination with clinical signs such as nausea, inappetence, cranial abdominal discomfort and/or laboratory changes such as increased ALP and/or increased Tbili. Non-visibly obstructive but shadowing mineral debris is visible.
INTERPRETED BY	<u>INTERPRETATION OF THE FINDINGS & FURTHER RECOMMENDATIONS</u>
Beth Johnson, DVM DACVIM	Differentials for a primary cholestatic liver enzyme pattern (increased ALP) are vast and non-specific. Differentials include, but are not limited to, benign nodular hyperplasia which occurs in 70% of older dogs and often does not result in an abnormal ultrasound, reactive or idiopathic/vacuolar hepatopathy, cholestasis and/or hyperadrenocorticism as well as many chronic non-hepatobiliary diseases such as chronic infections/inflammation from dental disease, IBD, neoplasia, hyperlipidemia, hypothyroidism, chronic pancreatitis, chronic stress, etc.
IMAGING PERFORMED BY	- Adrenocortical testing such as a low dose dexamethasone suppression test could be considered if clinical signs of hyperadrenocorticism are present.
Rebecca Hamilton	- Given the gallbladder changes/debris described above, empirical hepatic nutraceuticals including Ursodiol could be considered while monitoring ALP for improvement.
HOSPITAL NAME	- A fine needle aspirate of the liver could be considered if patient's coagulation status is appropriate.
Willakenzie Animal Clinic	- Otherwise, recommendations include addressing any other concurrent disease and monitoring. If values are progressive, recheck imaging is recommended.
REFERRING VET	
Dr. Brandt	
INVOICE	
73579	
DATE	
3/11/26	



PATIENT

Suwaay Hummel

SPECIES

Canine

BREED

Lab x

SEX

Spayed Female

AGE

13 Years

WEIGHT

54 lbs

INTERPRETED BY

Beth Johnson, DVM
 DACVIM

IMAGING PERFORMED BY

Rebecca Hamilton

HOSPITAL NAME

Willakenzie Animal
 Clinic

REFERRING VET

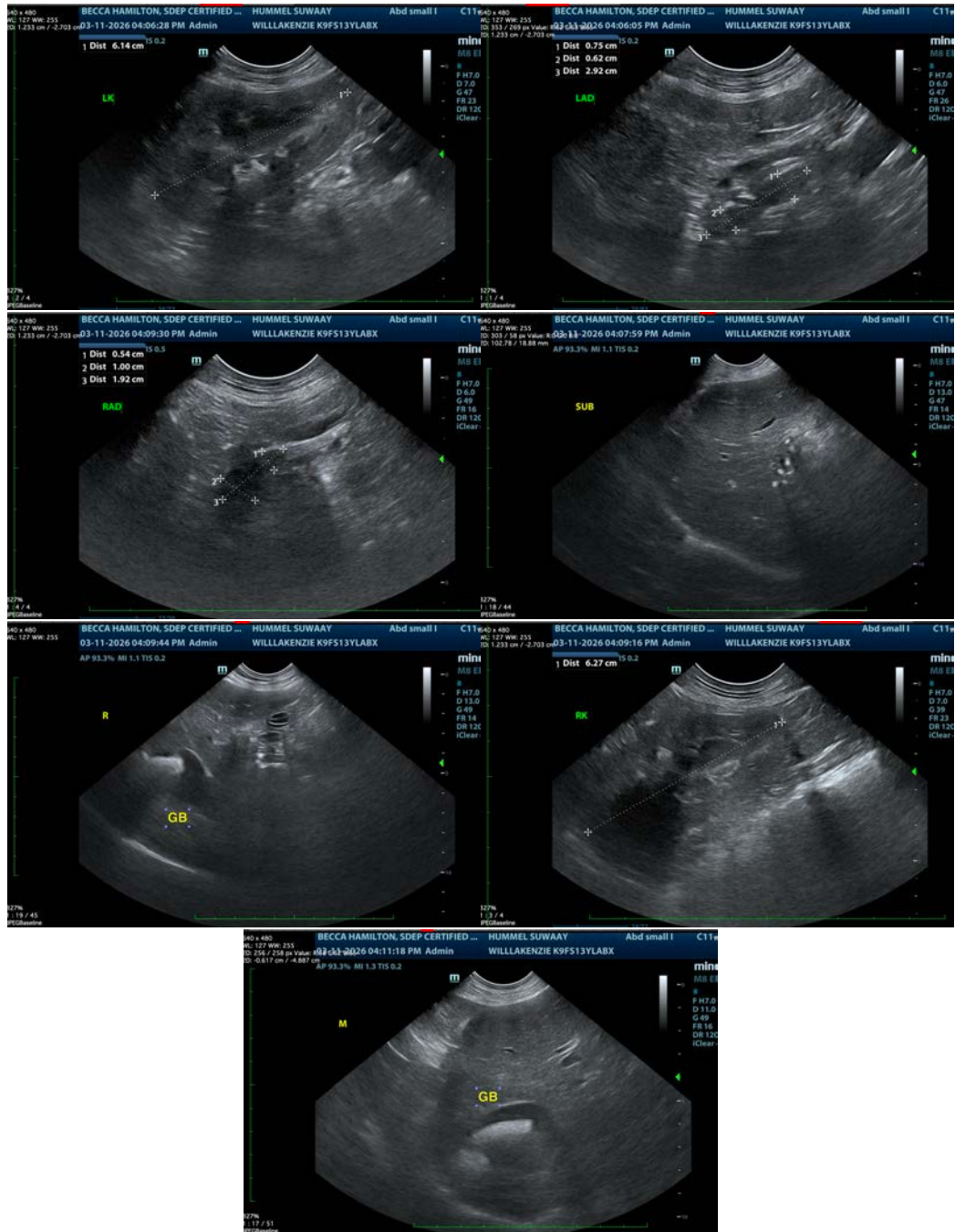
Dr. Brandt

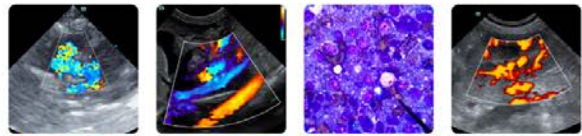
INVOICE

73579

DATE

3/11/26





PATIENT

Suwaay Hummel

SPECIES

Canine

BREED

Lab x

SEX

Spayed Female

AGE

13 Years

WEIGHT

54 lbs

INTERPRETED BY

Beth Johnson, DVM
DACVIM

IMAGING PERFORMED BY

Rebecca Hamilton

HOSPITAL NAME

Willakenzie Animal
Clinic

REFERRING VET

Dr. Brandt

INVOICE

73579

DATE

3/11/26

The information and recommendations provided are based on the images presented by the referring veterinarian/sonographer. No evaluation can be communicated regarding pathology that was not visible in the image/video clips provided.

Thank you for this referral. If the clinical or image interpretation does not parallel your findings or if I can be of any further assistance please contact me.

Beth Johnson, DVM, DACVIM
info@sonopath.com