



PATIENT

Lucy Purchase

SPECIES

Canine

BREED

Mixed

SEX

Spayed Female

AGE

16 years

WEIGHT

19 lbs

INTERPRETED BY

Beth Johnson, DVM
DACVIM

IMAGING PERFORMED BY

Dr. Julia Bakker

HOSPITAL NAME

Orange Blossom
Veterinary Imaging

REFERRING VET

Dr. Arthur Newman

INVOICE

11458

DATE

3/11/2026

PRESENTING CLINICAL SIGNS

- Pre-op labwork for growth removal shows liver enzyme elevations

Abnormal PE/Chem/CBC/UA Results: Glob 4.6 ALT 299 ALP 2104 GGT 186.

ULTRASONOGRAPHIC EXAMINATION OF THE ABDOMEN

Urinary System

The urinary bladder is adequately distended with anechoic contents. No masses, inflammatory changes, echogenic sediment or cystoliths are observed. The urinary bladder, trigone and visible pelvic urethra are normal in thickness with a smooth mucosal surface.

Kidneys are overall normal in size and shape with smooth peripheral margination. A normal 1:3 cortex to medulla ratio is maintained. The medulla and cortices are uniform in texture with some mild increased cortical echogenicity and mild loss of corticomedullary distinction, expected in this age patient. There is no evidence of pyelectasia, mineral or infarcts observed. Left kidney measures 4.83 cm, and the right kidney measures 4.63 cm.

Adrenal Glands

The right adrenal gland is normal in size (0.98 cm at cranial pole and 0.51 cm at caudal pole), shape and overall architecture, echogenicity and echotexture. Visible surrounding vasculature appears normal.

The left adrenal gland is normal in size (0.51 cm at cranial pole and 0.61 cm at caudal pole), shape and overall architecture, echogenicity and echotexture. Visible surrounding vasculature appears normal.

Spleen

Spleen is subjectively normal in size with a normal smooth capsular contour. Parenchyma is appropriately finely textured and homogenous with normal echogenicity relative to surrounding tissue (hyperechoic to liver). Multifocal well-demarcated hyperechoic homogenous nodules are noted. Splenic vasculature appears normal.

Liver

The liver contains at least two distinct masses, a 4.7 cm x 5.8 cm mixed, primarily hypoechoic, partially cystic mass is present in the left caudal liver. A second 3.5 cm x 4.0 cm homogenous, hypoechoic mass is present in the mid caudal liver.

Gallbladder is moderately distended with anechoic bile as well as suspended and gravity dependent echogenic debris. The wall is smooth without visible thickening. There is no evidence of cystic or CBD dilation. There is no evidence of effusion or inflammation.

Gastrointestinal

The visible stomach wall is normal in thickness and layering. The lumen of the stomach is mildly distended with echogenic non-shadowing luminal contents and gas consistent with normal ingesta. There is no evidence of obstruction or foreign material noted. Pyloric outflow tract appears patent.



PATIENT

Lucy Purchase

SPECIES

Canine

BREED

Mixed

SEX

Spayed Female

AGE

16 years

WEIGHT

19 lbs

INTERPRETED BY

Beth Johnson, DVM
DACVIM

IMAGING PERFORMED BY

Dr. Julia Bakker

HOSPITAL NAME

Orange Blossom
Veterinary Imaging

REFERRING VET

Dr. Arthur Newman

INVOICE

11458

DATE

3/11/2026

The visible small intestines are normal in wall thickness and layering. Small intestinal motility appears adequate (1-3 contractions per min). The lumen of the small intestine is mildly distended with echogenic non-shadowing luminal contents and gas consistent with normal ingesta. There is no evidence of obstruction or foreign material noted.

The visible colon is normal in wall thickness (< 0.2 cm) and layering. Contents are consistent with normal formed feces and gas.

Pancreas

The pancreas that is observed appears appropriately isoechoic to surrounding omental fat. Visible capsule is smooth and normal in contour. Visible pancreatic parenchyma is homogenous and unremarkable. There is no visible pancreatic duct dilation. There is no evidence of active peripancreatic inflammation.

Free Abdomen

There is no visible free peritoneal effusion noted in these images.

There is no apparent pathologic lymphadenopathy noted in these images.

PRIMARY FINDINGS

- The liver masses may represent the same etiology or different etiologies with differentials including both benign processes such as nodular hyperplasia, extramedullary hematopoiesis, hepatoma/adenoma, other. As well as infiltrative neoplasia such as hepatocellular carcinoma(s), round cell neoplasia such as lymphoma versus other, and can't be differentiated without tissue sampling.
- Moderate gallbladder debris- Cholecystic debris is of unknown clinical significance. It can be seen with biliary stasis from fasting or illness. Cholecystic debris is not necessarily related to hepatobiliary disease. Echogenic bile is most commonly an incidental finding in dogs and should be interpreted in combination with clinical signs such as nausea, inappetence, cranial abdominal discomfort and/or laboratory changes such as increased ALP and/or increased Tbili.

SECONDARY FINDINGS

- Hyperechoic splenic nodules - most consistent with benign myelolipomas. Other differentials such as fibrosis or calcification caused by old hematomas or infarcts, chronic inflammation, granulomatous disease or metastatic disease cannot be ruled out, but are considered less likely.
- Age related kidney changes.

INTERPRETATION OF THE FINDINGS & FURTHER RECOMMENDATIONS

Three view thoracic radiographs are recommended for further assessment of cardio-pulmonary status as well as to further evaluate for any evidence of metastatic disease, if not recently evaluated.

Fine needle aspirates of both liver masses are recommended if patient's coagulation status is appropriate.



PATIENT

Lucy Purchase

SPECIES

Canine

BREED

Mixed

SEX

Spayed Female

AGE

16 years

WEIGHT

19 lbs

INTERPRETED BY

Beth Johnson, DVM
DACVIM

IMAGING PERFORMED BY

Dr. Julia Bakker

HOSPITAL NAME

Orange Blossom
Veterinary Imaging

REFERRING VET

Dr. Arthur Newman

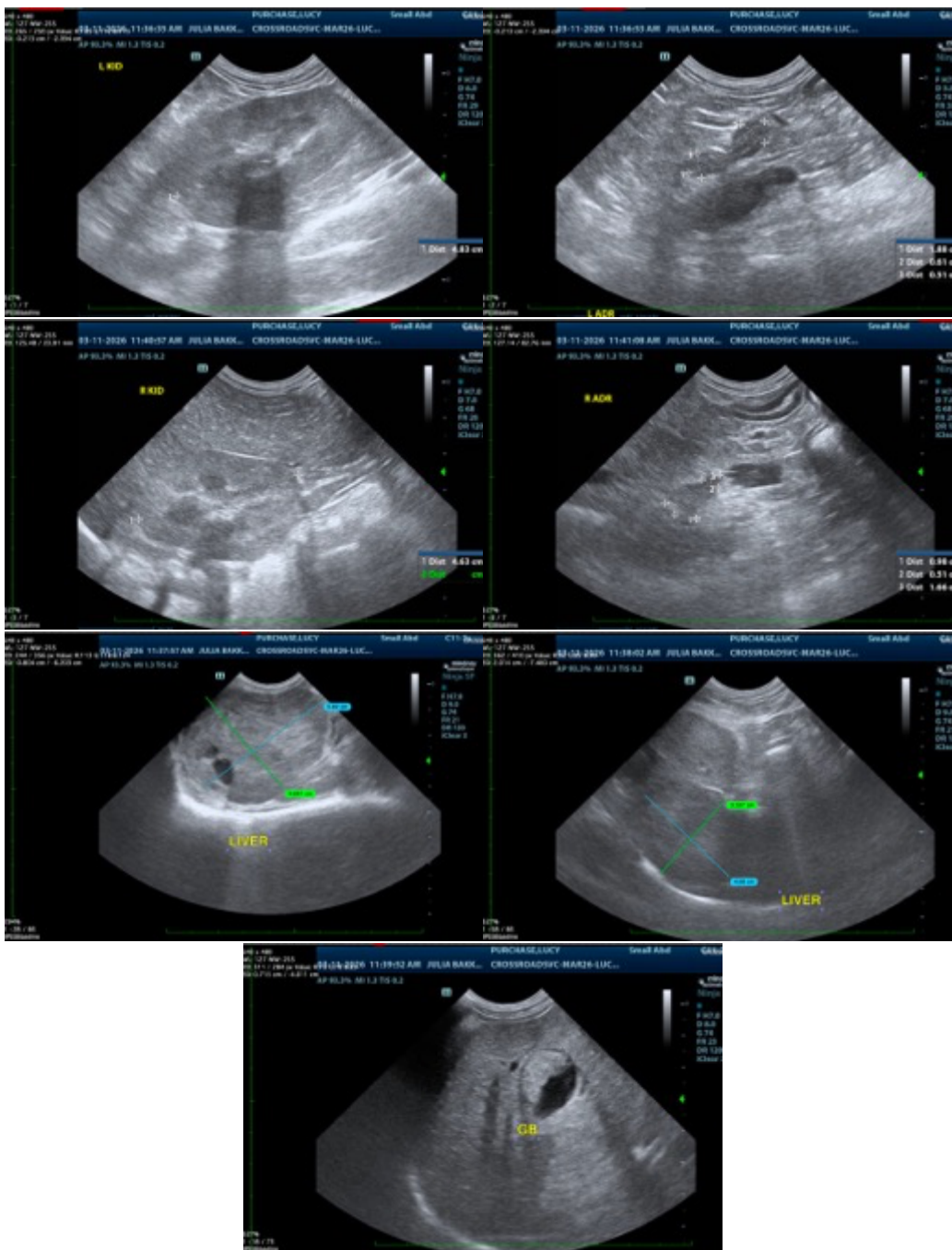
INVOICE

11458

DATE

3/11/2026

Other than supportive/symptomatic medical management of clinical signs, further treatment recommendations are largely dependent on results of the above.



The information and recommendations provided are based on the images presented by the referring veterinarian/sonographer. No evaluation can be communicated regarding pathology that was not visible in the image/video clips provided.



PATIENT

Lucy Purchase

SPECIES

Canine

BREED

Mixed

SEX

Spayed Female

AGE

16 years

WEIGHT

19 lbs

INTERPRETED BY

Beth Johnson, DVM
DACVIM

IMAGING PERFORMED BY

Dr. Julia Bakker

HOSPITAL NAME

Orange Blossom
Veterinary Imaging

REFERRING VET

Dr. Arthur Newman

INVOICE

11458

DATE

3/11/2026

Thank you for this referral. If the clinical or image interpretation does not parallel your findings or if I can be of any further assistance please contact me.

Beth Johnson, DVM, DACVIM
info@sonopath.com