



PATIENT

Lola Ovalle

SPECIES

Canine

BREED

Boston Terrier

SEX

Spayed Female

AGE

11 Years

WEIGHT

22 lbs

INTERPRETED BY

Beth Johnson, DVM
DACVIM

IMAGING PERFORMED BY

Kerri Becker

HOSPITAL NAME

Morris Hills Veterinary
Clinic

REFERRING VET

Dr. Hirshenson

INVOICE

73526

DATE

3/10/26

PRESENTING CLINICAL SIGNS

Vomiting blood in the morning-lethargic-anorexic. Was DX w/ cushing.

ULTRASONOGRAPHIC EXAMINATION OF THE ABDOMEN

Urinary System

The urinary bladder is adequately distended with anechoic contents. No masses, inflammatory changes, echogenic sediment or cystoliths are observed. The urinary bladder, trigone and visible pelvic urethra are normal in thickness with a smooth mucosal surface.

The right kidney is normal is size (5.27 cm), shape and echogenicity. It has smooth peripheral margination. There is a normal 1:3 cortex to medulla ratio with appropriate corticomedullary distinction. There is no evidence of pyelectasia, mineral or infarcts observed.

The left kidney is normal is size (5.13 cm), shape and echogenicity. It has smooth peripheral margination. There is a normal 1:3 cortex to medulla ratio with appropriate corticomedullary distinction. There is no evidence of pyelectasia, mineral or infarcts observed.

Adrenal Glands

Adrenal glands are plump/swollen in size. Normal shape and contour are maintained without evidence of capsular invasion. Corticomedullary structure is unremarkable. Visible surrounding vasculature appears normal. Left measured 0.91 cm at the cranial pole and 1.1 cm at the caudal pole. Right measured 1.1 cm at the cranial pole and 0.81 cm at the caudal pole.

Spleen

The spleen is subjectively normal in size with a normal smooth capsular contour. Parenchyma is appropriately finely textured and homogenous with normal echogenicity relative to surrounding tissue (hyperechoic to liver). No focal nodules or masses are observed. Splenic vasculature appears normal.

Liver

The liver is subjectively normal in size with normal smooth curvilinear peripheral contour. Parenchyma is appropriately hypoechoic to the spleen in echogenicity and appropriately mildly coarse and homogenous in echotexture. No focal lesions are observed. Visible vasculature and biliary tree appear normal without distension or congestion.

Gallbladder is moderately distended with anechoic bile as well as suspended and gravity dependent echogenic debris. The wall is smooth without visible thickening. There is no evidence of cystic or CBD dilation. There is no evidence of effusion or inflammation.

Gastrointestinal

Fundic mucosal hypertrophy with hyperechoic mucosa and some mucosal remodeling is noted. There is no loss of mural detail. Layering is normal. There is mild luminal fluid accumulation. No evidence of masses/nodules or foreign material present.



PATIENT

Lola Ovalle

The visible small intestines are normal in wall thickness and layering. Small intestinal motility appears adequate (1-3 contractions per min). The lumen of the small intestine is empty with no evidence of obstruction, foreign material or infiltrative disease.

SPECIES

Canine

The visible colon is normal in wall thickness (< 0.2 cm) and layering. Contents are consistent with normal formed feces and gas.

Pancreas

BREED

Boston Terrier

The observed pancreas is prominent (enlarged) in size, hypoechoic to surrounding tissue and irregular in shape with a swollen undulating contour. Enhanced hyperechoic ill-defined surrounding fat is noted.

Free Abdomen

SEX

Spayed Female

There is no visible free peritoneal effusion noted in these images.

There is no apparent pathologic lymphadenopathy noted in these images.

AGE

11 Years

ULTRASONOGRAPHIC FINDINGS

WEIGHT

22 lbs

- Moderate acute pancreatitis is suspected.
- Concurrent gastritis – Consistent with irritation secondary to dietary indiscretion or intolerance, infection (bacterial, viral, other), parasitic or protozoal disease, toxin, other metabolic disease such as pancreatitis, other. Microulceration cannot be ruled out.
- Mild gallbladder debris - Cholecystic debris is of unknown clinical significance. It can be seen with biliary stasis from fasting or illness. Cholecystic debris is not necessarily related to hepatobiliary disease. Echogenic bile is most commonly an incidental finding in dogs and should be interpreted in combination with clinical signs such as nausea, inappetence, cranial abdominal discomfort and/or laboratory changes such as increased ALP and/or increased Tbili.
- Bilateral adrenomegaly – In a patient diagnosed with hyperadrenocorticism, this finding is most consistent with adrenal hyperplasia secondary to pituitary dependent hyperadrenocorticism. This finding can also be seen with stress and/or normal patient variant. Interpret in combination with clinical signs of hyperadrenocorticism and/or other adrenal disease.

INTERPRETED BY

Beth Johnson, DVM
DACVIM

IMAGING PERFORMED BY

Kerri Becker

HOSPITAL NAME

Morris Hills Veterinary
Clinic

REFERRING VET

Dr. Hirshenson

INTERPRETATION OF THE FINDINGS & FURTHER RECOMMENDATIONS

If not recently evaluated, a general metabolic health screen (CBC, chemistry panel with electrolytes and urinalysis) is recommended.

A routine fecal/giardia exam is recommended if not recently evaluated.

INVOICE

73526

A gastrointestinal malabsorption panel (including cobalamin, folate, TLI and PLI) to Texas A&M GI Laboratory is recommended for further evaluation of GI and pancreatic function.

DATE

3/10/26

Evaluation of cortisol levels is recommended, especially if patient is being medically managed for reported previous diagnosis of Cushing's disease.



PATIENT

Lola Ovalle

SPECIES

Canine

BREED

Boston Terrier

SEX

Spayed Female

AGE

11 Years

WEIGHT

22 lbs

INTERPRETED BY

Beth Johnson, DVM
 DACVIM

IMAGING PERFORMED BY

Kerri Becker

HOSPITAL NAME

Morris Hills Veterinary
 Clinic

REFERRING VET

Dr. Hirshenson

INVOICE

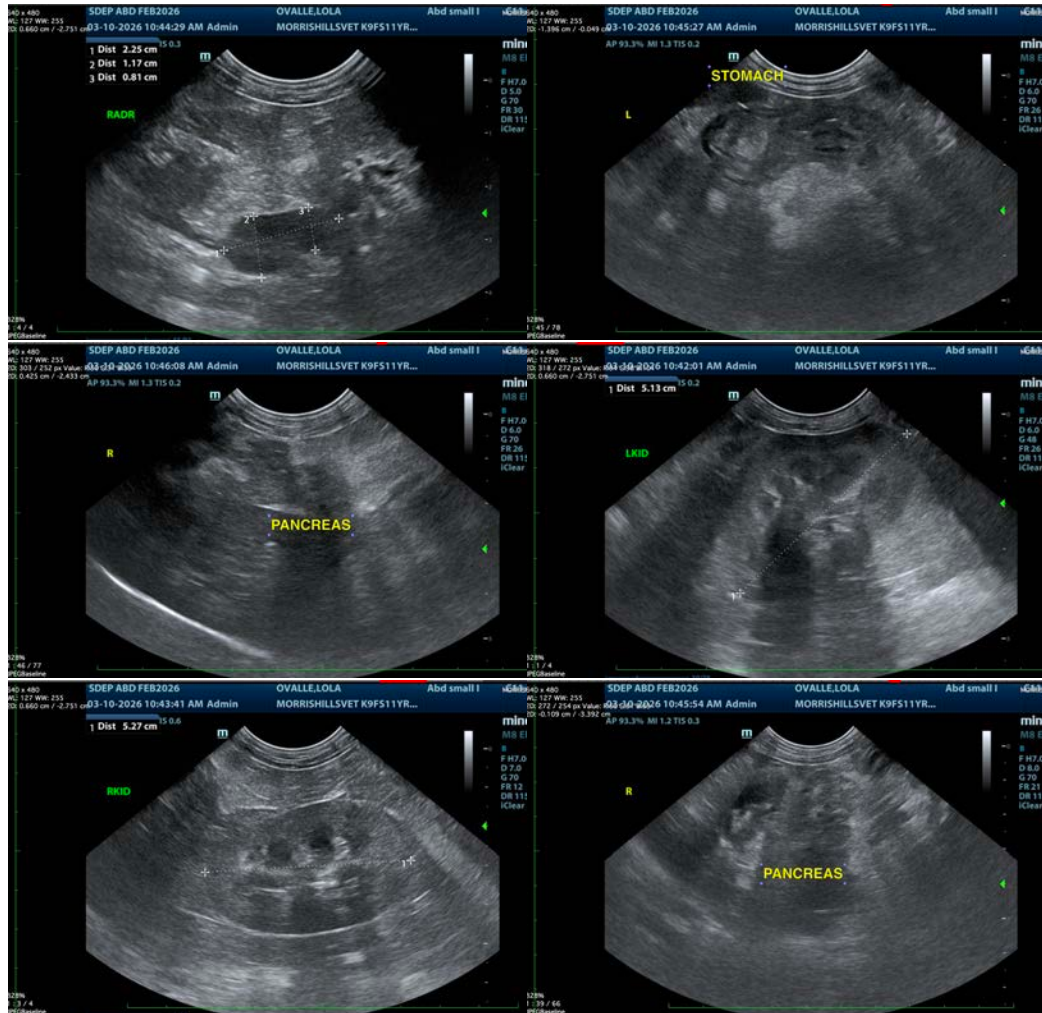73526

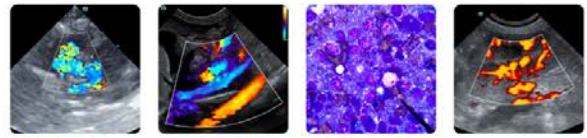
DATE

3/10/26

In the meantime, medical management of pancreatitis with anti-emetics, gastroprotectants, appetite stimulants or nutritional support as needed, pain management, broad spectrum antibiotics, and fluid therapy is recommended. Monitoring of the pancreas with power doppler is recommended to identify possible necrosis as well as other potential sequelae such as abscesses, etc.

If patient is being medically managed for Cushing's disease, dependent on the medication, discontinuation of treatment may be indicated temporarily and/or until clinical signs of hyperadrenocorticism return.





PATIENT

Lola Ovalle

SPECIES

Canine

BREED

Boston Terrier

SEX

Spayed Female

AGE

11 Years

WEIGHT

22 lbs

INTERPRETED BY

Beth Johnson, DVM
DACVIM

IMAGING PERFORMED BY

Kerri Becker

HOSPITAL NAME

Morris Hills Veterinary
Clinic

REFERRING VET

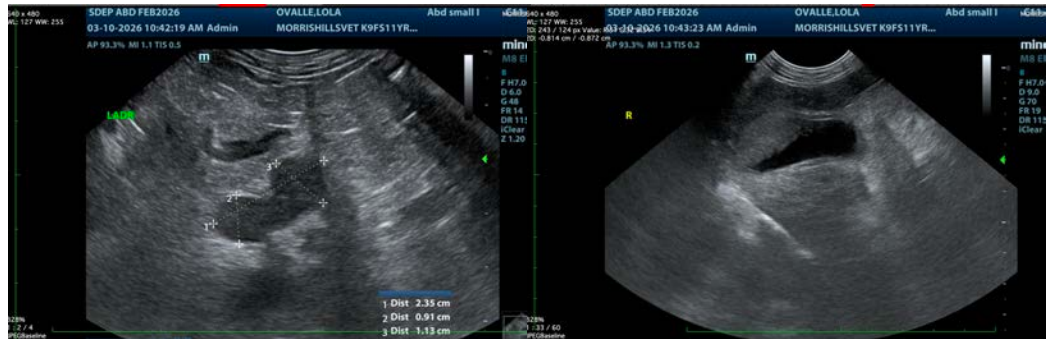
Dr. Hirshenson

INVOICE

73526

DATE

3/10/26



The information and recommendations provided are based on the images presented by the referring veterinarian/sonographer. No evaluation can be communicated regarding pathology that was not visible in the image/video clips provided.

Thank you for this referral. If the clinical or image interpretation does not parallel your findings or if I can be of any further assistance please contact me.

Beth Johnson, DVM, DACVIM
info@sonopath.com