



PATIENT

Arnold Suter

SPECIES

Canine

BREED

Bichon Frise x

SEX

Neutered Male

AGE

11 Years

WEIGHT

15 lbs

INTERPRETED BY

Beth Johnson, DVM
DACVIM

IMAGING PERFORMED BY

Dr. Reyes

HOSPITAL NAME

Graceful Paws Pet
Clinic

REFERRING VET

Dr. Reyes

INVOICE

73511

DATE

3/10/26

PRESENTING CLINICAL SIGNS

History of off/on GI issues like vomiting and borborygmi. No diarrhea. Owner is currently cooking for pet. TLI was previously elevated at 47.9, pet never has diarrhea. Folate was previously low at 3.1, Vit B 12 was normal at 619. Pet was 15.4 lbs July 2025, 15.0 currently

Abnormal PE/Chem/CBC/UA Results: CBC Mono: 0.897 Chem BUN: 36 ALT: 3,382, 189 (06/24/2025) AST: 114 ALP: 614 GGT: 23 CK: 229 T4: nsf 4dx: neg Cortisol pending based on clinical signs

ULTRASONOGRAPHIC EXAMINATION OF THE ABDOMEN

Urinary System

The urinary bladder is adequately distended with anechoic contents. No masses, inflammatory changes, echogenic sediment or cystoliths are observed. The urinary bladder, trigone and visible pelvic urethra are normal in thickness with a smooth mucosal surface.

The prostate is unable to be well visualized in these images.

The right kidney is normal is size (4.5 cm), shape and echogenicity. It has smooth peripheral margination. There is a normal 1:3 cortex to medulla ratio with appropriate corticomedullary distinction. There is no evidence of pyelectasia, mineral or infarcts observed.

The left kidney is normal is size (4.5 cm), shape and echogenicity. It has smooth peripheral margination. There is a normal 1:3 cortex to medulla ratio with appropriate corticomedullary distinction. There is no evidence of pyelectasia, mineral or infarcts observed.

Adrenal Glands

The adrenal glands are unable to be well visualized in these images.

Spleen

The spleen is subjectively normal in size with a normal smooth capsular contour. Parenchyma is appropriately finely textured and homogenous with normal echogenicity relative to surrounding tissue (hyperechoic to liver). No focal nodules or masses are observed. Splenic vasculature appears normal.

Liver

Liver is subjectively enlarged with mildly irregular margins. Parenchyma is moderately heterogenous characterized by multiple poorly defined hypoechoic nodules within otherwise hyperechoic liver parenchyma. Visible vasculature and biliary tree appear normal without distension or congestion.

The gallbladder is non-distended in size. The wall is smooth without visible thickening. Luminal contents are primarily anechoic. There is no evidence of cystic or common bile duct dilation.

Gastrointestinal

The visible stomach wall is normal in thickness and layering. The lumen is moderately over distended with primarily fluid as well as some echogenic non-shadowing luminal contents and gas consistent with normal chyme. There is no evidence of obstruction, foreign material, or infiltrative disease. Pyloric outflow tract appears patent.



PATIENT

Arnold Suter

SPECIES

Canine

BREED

Bichon Frise x

SEX

Neutered Male

AGE

11 Years

WEIGHT

15 lbs

INTERPRETED BY

Beth Johnson, DVM
DACVIM

IMAGING PERFORMED BY

Dr. Reyes

HOSPITAL NAME

Graceful Paws Pet
Clinic

REFERRING VET

Dr. Reyes

INVOICE

73511

DATE

3/10/26

The visible small intestines are normal in wall thickness and layering. Small intestinal motility appears adequate (1-3 contractions per min). The lumen of the small intestine is empty, except for some mild fluid distention/suspect ileus in the proximal small bowel/duodenum, with no evidence of obstruction, foreign material or infiltrative disease.

The visible colon is normal in wall thickness (< 0.2 cm) and layering. Contents are consistent with normal formed feces and gas.

Pancreas

The pancreas that is observed appears appropriately isoechoic to surrounding omental fat. Visible capsule is smooth and normal in contour. Visible pancreatic parenchyma is homogenous and unremarkable. There is no visible pancreatic duct dilation. There is no evidence of active peripancreatic inflammation.

Free Abdomen

There is no visible free peritoneal effusion noted in these images.

There is no apparent pathologic lymphadenopathy noted in these images.

ULTRASONOGRAPHIC FINDINGS

- The appearance of the fluid dilated stomach and proximal small bowel is most consistent with underlying gastroenteritis secondary to primary infectious, inflammatory, parasitic, dietary, gastrointestinal disease or other underlying metabolic disease, with no definitive or visible evidence of a mechanical obstruction noted in these images at this time.
- An obvious cause for the moderate liver changes is not identified in these images. Microscopic disease such as Leptospirosis, bacterial cholangiohepatitis, chronic active hepatitis, copper-associated hepatotoxicity, other hepatotoxicity, other reactive hepatopathy, infiltrative neoplasia, etc. cannot be definitively ruled out.

INTERPRETATION OF THE FINDINGS & FURTHER RECOMMENDATIONS

Given patient's reported gastrointestinal history, as is reportedly already pending, a baseline cortisol is recommended. If baseline cortisol is less than 2, a full ACTH stimulation test is recommended to rule out hypoadrenocorticism.

A routine fecal/giardia exam is also recommended.

Differentials for a primary hepatocellular injury liver enzyme pattern (increased ALT) depend partially on the level of increase. Mild increases (less than 2 times normal) are often a "reactive hepatopathy" or the liver's response to an insult elsewhere in the body including, but not limited to, pancreatitis, gastroenteritis, parasitic disease, dental disease, vacuolar or endocrine hepatopathy from diabetes mellitus or hyperadrenocorticism (steroid-induced), hypoadrenocorticism, certain drugs (e.g. phenobarbital, corticosteroids, azathioprine, etc.), and muscle ALT (more likely if AST and CK concurrently increased).

It is a good indicator of active liver damage (cell membrane disruption, cellular necrosis), however, if the value is increased by at least 3-4 times normal. Differentials include infectious disease, including Leptospirosis, inflammatory disease (ie. active hepatitis, copper, other), toxic insult as well as infiltrative neoplasia.



PATIENT

Arnold Suter

SPECIES

Canine

BREED

Bichon Frise x

SEX

Neutered Male

AGE

11 Years

WEIGHT

15 lbs

INTERPRETED BY

Beth Johnson, DVM
DACVIM

IMAGING PERFORMED BY

Dr. Reyes

HOSPITAL NAME

Graceful Paws Pet
Clinic

REFERRING VET

Dr. Reyes

INVOICE

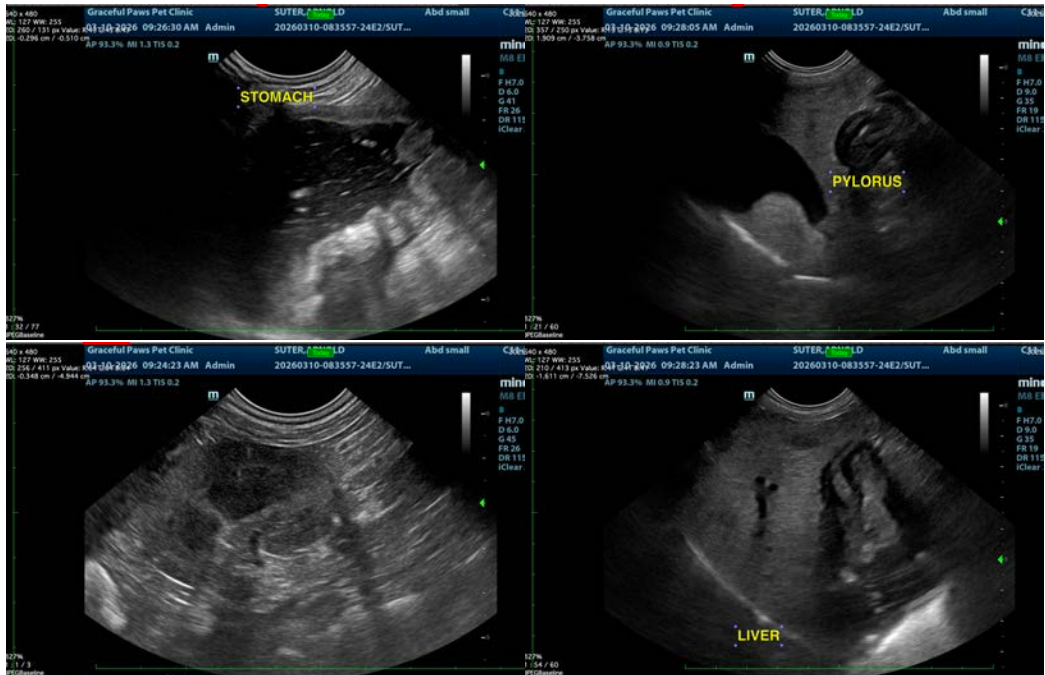
73511

DATE

3/10/26

ALT levels vary in cases of vascular anomalies such as microvascular dysplasia and portosystemic shunts (PSS), but are often less significantly increased.

- Testing for Leptospirosis could be considered.
- Bile acids could be considered, if tbili is not increased.
- An empirical course of antibiotics and empirical hepatic nutraceuticals may be tried, with monitoring of ALT for improvement. If improvement is noted, antibiotics should be continued until liver enzymes either normalize or plateau (recheck every 2-3 weeks); however, if improvement is not noted and/or enzyme increase progresses, antibiotics should not be continued long term and liver tissue sampling is recommended.
- FNA of the liver can be performed to assess inflammatory cell type, rule in/out round cell neoplasia, etc. (if patient's coagulation status is appropriate).
- If round cell neoplasia is not diagnosed, a liver biopsy (including copper level assessment) may be required to definitively diagnose the underlying hepatopathy.





PATIENT

Arnold Suter

SPECIES

Canine

BREED

Bichon Frise x

SEX

Neutered Male

AGE

11 Years

WEIGHT

15 lbs

INTERPRETED BY

Beth Johnson, DVM
DACVIM

IMAGING PERFORMED BY

Dr. Reyes

HOSPITAL NAME

Graceful Paws Pet
Clinic

REFERRING VET

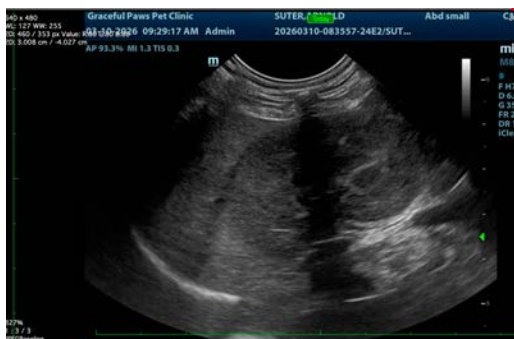Dr. Reyes

INVOICE

73511

DATE

3/10/26



The information and recommendations provided are based on the images presented by the referring veterinarian/sonographer. No evaluation can be communicated regarding pathology that was not visible in the image/video clips provided.

Thank you for this referral. If the clinical or image interpretation does not parallel your findings or if I can be of any further assistance please contact me.

Beth Johnson, DVM, DACVIM
info@sonopath.com