



**PATIENT**

Lisa Moe

**SPECIES**

Feline

**BREED**

DSH

**SEX**

Spayed Female

**AGE**

3 Years

**WEIGHT**

11.6 Pounds

**INTERPRETED BY**

Beth Johnson, DVM  
DACVIM

**IMAGING PERFORMED BY**

Nicole Gotfredson

**HOSPITAL NAME**

Buffalo VC

**REFERRING VET**

Dr. Gary Gotfredson

**INVOICE**

14260

**DATE**

3/10/22

**PRESENTING CLINICAL SIGNS**

History: Vomits frequently, chronic over the past 2+ years since owner has owned the cat. Cat is BAR. Abnormal PE/Chem/CBC/UA Results: normal BW Radiographs reveal shows thickened bowels but otherwise NSF

**ULTRASONOGRAPHIC EXAMINATION OF THE ABDOMEN**

**Urinary System**

Urinary bladder is moderately distended with anechoic contents. No masses, inflammatory changes, echogenic sediment or cystoliths are observed. The urinary bladder, trigone and visible pelvic urethra are normal in thickness with a smooth mucosal surface

Kidneys are bilaterally normal in size, irregular and diffusely echogenic with decreased corticomedullary distinction and poor visualization of internal architecture. There is no pyelectasia noted and no mineral is observed. The left kidney measures 3.9 cm. The right kidney measures 3.6 cm.

**Adrenal Glands**

Left adrenal gland is normal in size (0.45 cm thick), shape and contour. Corticomedullary structure is unremarkable. Visible surrounding vasculature appears normal.

Right adrenal gland is normal in size (0.35 cm thick), shape and contour. Corticomedullary structure is unremarkable. Visible surrounding vasculature appears normal.

**Spleen**

Spleen is subjectively enlarged in size with rounded margins but intact capsule. Parenchyma is homogenously coarse/mottled in echotexture and normal to hypoechoic in echogenicity. No focal nodules or masses are observed. Splenic vasculature appears normal.

**Liver**

Liver is subjectively normal in size with normal smooth curvilinear peripheral contour. Parenchyma is appropriately hypoechoic to the spleen in echogenicity and appropriately mildly coarse and homogenous in echotexture. No focal lesions are observed. Visible vasculature and biliary tree appear normal without distension or congestion.

Gallbladder is non-distended in size. The wall is smooth without visible thickening. Luminal contents are primarily anechoic. There is no evidence of cystic or common bile duct dilation.

**Gastrointestinal**

The stomach wall is normal in thickness (canine < 0.5 cm and feline < 0.4 cm) and layering. The lumen of the stomach is mildly distended with echogenic non-shadowing luminal contents and gas consistent with normal ingesta. There is no evidence of obstruction, foreign material or infiltrative disease.

The visible small intestines are normal in wall thickness and layering (canine duodenum < 0.5 cm and feline duodenum < 0.4 cm; other < 0.3 cm). Small intestinal motility appears adequate (1-3 contractions per min). The lumen of the small intestine is mildly distended with echogenic non-shadowing luminal contents and gas consistent with normal ingesta. There is no evidence of obstruction, foreign material or infiltrative disease.



## PATIENT

The visible colon is normal in wall thickness (< 0.2 cm) and layering. Contents are consistent with normal formed feces and gas.

Lisa Moe

## Pancreas

## SPECIES

Pancreatic parenchyma is appropriately isoechoic to surrounding tissue. Visible capsule is smooth and normal in contour. There is no visible pancreatic duct dilation. There is no evidence of active peripancreatic inflammation.

Feline

## BREED

## Free Abdomen

DSH

There is no appreciable lymphadenopathy or free fluid noted in these images.

## ULTRASONOGRAPHIC FINDINGS

## SEX

## Primary Findings

Spayed Female

- Coarse splenomegaly can be associated with congestion caused by sedation (if sedated) but can also be associated with diffuse infiltrative disease. Both benign conditions such as extramedullary hematopoiesis, lymphoid hyperplasia, amyloidosis (leave amyloidosis out if canine) as well as infiltrative neoplastic diseases such as round cell neoplasia should be considered.

## AGE

3 Years

## WEIGHT

## Secondary Findings

11.6 Pounds

- Chronic kidney disease. This appearance of the kidneys is consistent with chronic kidney disease such as chronic glomerular or interstitial nephritis, chronic pyelonephritis, etc.

## INTERPRETED BY

## INTERPRETATION OF THE FINDINGS & FURTHER RECOMMENDATIONS

Beth Johnson, DVM  
DACVIM

The bowel visible in these images does not appear thick, however, the presence of luminal contents is noted diffusely, which may have contributed to the report of thickened bowel radiographically. Both gastrointestinal disease as well as pancreatic disease can be present and cause gastrointestinal signs with a relatively unremarkable ultrasound. Therefore, recommendations include a gastrointestinal malabsorption panel, to include PLI, TLI, folate and cobalamin (to Texas A & M GI Laboratory) for further assessment of the GI tract and pancreas, A fine needle aspirate of the spleen could be considered if patient coagulation status is appropriate, especially if this patient was not sedated for the ultrasound.

## IMAGING PERFORMED BY

Nicole Gotfredson

## HOSPITAL NAME

In the meantime, transition to a novel or hydrolyzed protein diet could be tried empirically. If clinical signs do not resolve and/or progress, recheck fasted imaging may be beneficial.

Buffalo VC

## REFERRING VET

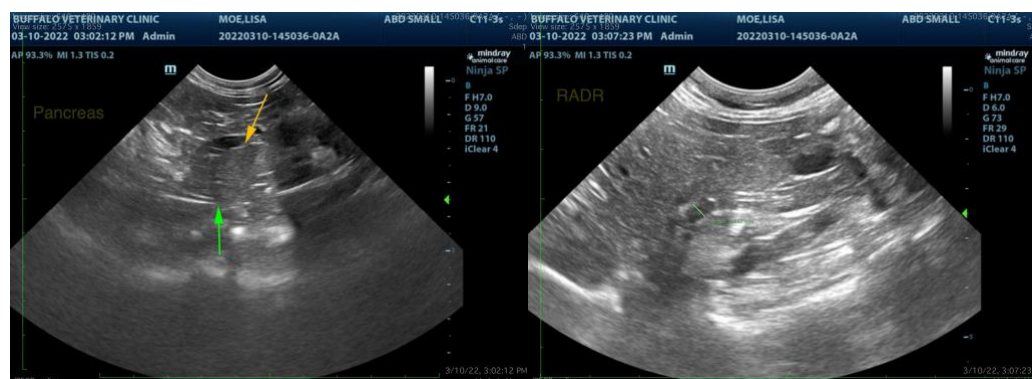
Dr. Gary Gotfredson

## INVOICE

14260

## DATE

3/10/22





**PATIENT**

Lisa Moe

**SPECIES**

Feline

**BREED**

DSH

**SEX**

Spayed Female

**AGE**

3 Years

**WEIGHT**

11.6 Pounds

**INTERPRETED BY**

Beth Johnson, DVM  
DACVIM

**IMAGING PERFORMED BY**

Nicole Gotfredson

**HOSPITAL NAME**

Buffalo VC

**REFERRING VET**

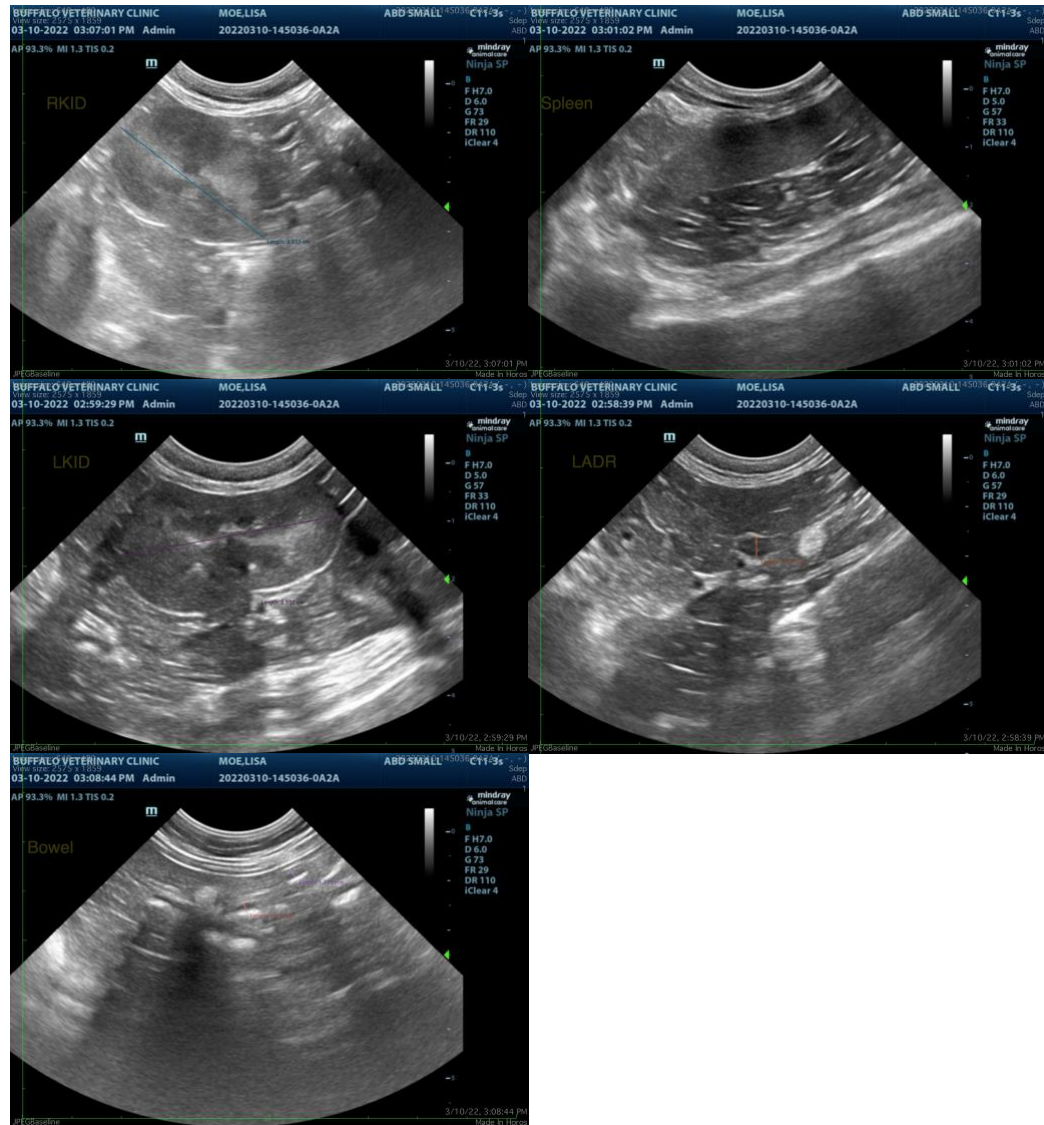
Dr. Gary Gotfredson

**INVOICE**

14260

**DATE**

3/10/22



The information and recommendations provided are based on the images presented by the referring veterinarian. No evaluation can be communicated regarding pathology that was not visible in the image/video clips provided.

Thank you for this referral. If the clinical or image interpretation does not parallel your findings or if I can be of any further assistance please contact me.

**Beth Johnson, DVM DACVIM**

Beth.Johnson@SonoPath.com