



**PATIENT**

Lily Fields

**SPECIES**

Canine

**BREED**

Poodle/Sheep dog mic

**SEX**

Spayed Female

**AGE**

7 Years

**WEIGHT**

70 Pounds

**INTERPRETED BY**

Beth Johnson, DVM  
DACVIM

**IMAGING PERFORMED BY**

Rebecca Hamilton

**HOSPITAL NAME**

AH of Sussex County

**REFERRING VET**

Dr. Lovell

**INVOICE**

36782

**DATE**

2/9/26

**PRESENTING CLINICAL SIGNS**

- Chronic diarrhea, vomiting, abdominal pain, normal exam
- Meds: Omeprazole, Apoquel, Metronidazole, Gabapentin
- Abnormal PE/Chem/CBC/UA Results: WNL, Urine WNL USG 1.010

**ULTRASONOGRAPHIC EXAMINATION OF THE ABDOMEN**

**Urinary System**

Urinary bladder is adequately distended with anechoic contents. No masses, inflammatory changes, echogenic sediment or cystoliths are observed. The urinary bladder, trigone and visible pelvic urethra are normal in thickness with a smooth mucosal surface.

Left kidney is normal in size (6.2 cm), shape and echogenicity. It has smooth peripheral margination. There is a normal 1:3 cortex to medulla ratio with appropriate corticomedullary distinction. There is no evidence of pyelectasia, mineral or infarcts observed.

Right kidney is normal in size (7.5 cm), shape and echogenicity. It has smooth peripheral margination. There is a normal 1:3 cortex to medulla ratio with appropriate corticomedullary distinction. There is no evidence of pyelectasia, mineral or infarcts observed.

**Adrenal Glands**

Left adrenal gland is normal in size (0.37 cm at cranial pole and 0.38 cm at caudal pole), shape and overall architecture, echogenicity and echotexture. Visible surrounding vasculature appears normal.

Right adrenal gland is normal in size (0.58 cm at cranial pole and 0.34 cm at caudal pole), shape and overall architecture, echogenicity and echotexture. Visible surrounding vasculature appears normal.

**Spleen**

Spleen is subjectively normal in size (2.1 cm thick at the hilus) with a normal smooth capsular contour. Parenchyma is appropriately finely textured and homogenous with normal echogenicity relative to surrounding tissue (hyperechoic to liver). No focal nodules or masses are observed. Splenic vasculature appears normal.

**Liver**

Liver is subjectively normal in size with normal smooth curvilinear peripheral contour. Parenchyma is appropriately hypoechoic to the spleen in echogenicity and appropriately mildly coarse and homogenous in echotexture. No focal lesions are observed. Visible vasculature and biliary tree appear normal without distension or congestion.

Gallbladder is non-distended in size. The wall is smooth without visible thickening. Luminal contents are primarily anechoic. There is no evidence of cystic or common bile duct dilation.

**Gastrointestinal**



**PATIENT**

Lily Fields

**SPECIES**

Canine

**BREED**

Poodle/Sheep dog mic

**SEX**

Spayed Female

**AGE**

7 Years

**WEIGHT**

70 Pounds

**INTERPRETED BY**

Beth Johnson, DVM  
DACVIM

**IMAGING PERFORMED BY**

Rebecca Hamilton

**HOSPITAL NAME**

AH of Sussex County

**REFERRING VET**

Dr. Lovell

**INVOICE**

36782

**DATE**

2/9/26

The visible stomach wall is normal in thickness and layering. The stomach is moderately distended with echogenic non-shadowing luminal contents and gas consistent with normal ingesta. There is no evidence of obstruction, foreign material or infiltrative disease. If patient was appropriately fasted, delayed gastric emptying could be considered. Non-shadowing foreign material is considered less likely but cannot be definitively ruled out. If clinical signs are consistent (vomiting, etc.), recommendations include supportive medical care, 24 hours fasting and re-image.

The visible small intestines are normal in wall thickness and layering. Small intestinal motility appears adequate (1-3 contractions per min). The lumen of the small intestine is mildly distended with echogenic non-shadowing luminal contents and gas consistent with normal ingesta/chyme. There is no evidence of obstruction, foreign material or infiltrative disease.

The visible colon is normal in wall thickness (< 0.2 cm) and layering. The lumen is moderately diffusely distended with soft stool.

***Pancreas***

The pancreas that is observed appears appropriately isoechoic to surrounding omental fat. Visible capsule is smooth and normal in contour. Visible pancreatic parenchyma is homogenous and unremarkable. There is no visible pancreatic duct dilation. There is no evidence of active peripancreatic inflammation.

***Free Abdomen***

There is no visible free peritoneal effusion noted in these images.

There is no apparent pathologic lymphadenopathy noted in these images.

**ULTRASONOGRAPHIC FINDINGS**

- Other than soft stool, as is consistent with patient's history, there is not a definitive ultrasonographically visible explanation for patient's reported ongoing gastrointestinal signs.

**INTERPRETATION OF THE FINDINGS & FURTHER RECOMMENDATIONS**

A routine fecal/Giardia exam is recommended if not recently evaluated.

A gastrointestinal malabsorption panel (including cobalamin, folate, TLI and PLI) to Texas A&M GI Laboratory is recommended for further evaluation of GI and pancreatic function.

A fecal enteropathogen PCR panel to Texas A&M GI Laboratory could be considered for further evaluation of possible infectious disease. Contact lab for recommendations on how long to discontinue antibiotics (if indicated) prior to obtaining a stool sample for submission.

A baseline cortisol is recommended. If baseline cortisol is less than 2, a full ACTH stimulation test is recommended to rule out hypoadrenocorticism.

In the meantime:

Supportive/symptomatic medical management of clinical signs is recommended, including anti-emetics, gastroprotectants (+/- sucralfate, especially with any history of hematemesis), an appetite stimulant and fluid therapy if indicated, etc.



**PATIENT**

Additionally, empirical deworming with a 5-day course of Panacur is recommended.

Lily Fields

A full course of empirical Helicobacter triple therapy could be considered.

**SPECIES**

A probiotic, such as a visbiome or proviable, may be helpful.

Canine

Finally, if tolerated, a transition in diet could be considered, based on trial-and-error response with some options to consider including a gastrointestinal biome diet vs a hydrolyzed protein diet (sometimes several trials with different brands are necessary) vs an easy to digest, bland or low-fat diet vs other.

**BREED**

Poodle/Sheep dog mic

**SEX**

Spayed Female

**AGE**

7 Years

**WEIGHT**

70 Pounds

**INTERPRETED BY**

Beth Johnson, DVM  
DACVIM

**IMAGING PERFORMED BY**

Rebecca Hamilton

**HOSPITAL NAME**

AH of Sussex County

**REFERRING VET**

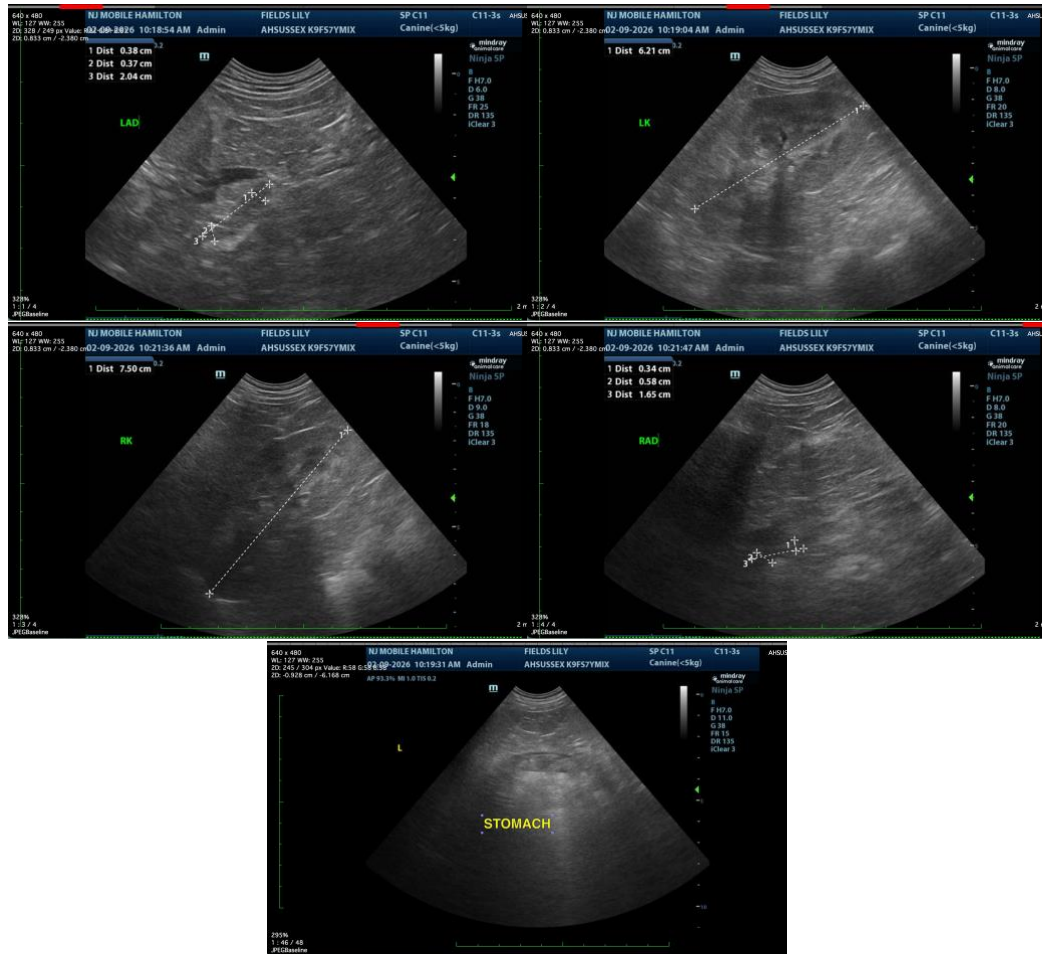
Dr. Lovell

**INVOICE**

36782

**DATE**

2/9/26



The information and recommendations provided are based on the images presented by the referring veterinarian/sonographer. No evaluation can be communicated regarding pathology that was not visible in the image/video clips provided.

Thank you for this referral. If the clinical or image interpretation does not parallel your findings or if I can be of any further assistance please contact me.

**Beth Johnson, DVM DACVIM**



**PATIENT**

info@sonopath.com

Lily Fields

**SPECIES**

Canine

**BREED**

Poodle/Sheep dog mic

**SEX**

Spayed Female

**AGE**

7 Years

**WEIGHT**

70 Pounds

**INTERPRETED BY**

Beth Johnson, DVM  
DACVIM

**IMAGING  
PERFORMED BY**

Rebecca Hamilton

**HOSPITAL NAME**

AH of Sussex County

**REFERRING VET**

Dr. Lovell

**INVOICE**

36782

**DATE**

2/9/26