



PATIENT

Leidy Isler

SPECIES

Canine

BREED

Maltipoo

SEX

Spayed Female

AGE

13 Years

WEIGHT

12.2 Pounds

INTERPRETED BY

Beth Johnson, DVM
 DACVIM

IMAGING PERFORMED BY

Meghan Morse, LVT,
 CVT

HOSPITAL NAME

Animal General on
 Hudson

REFERRING VET

Dr. DiGiuseppi

INVOICE

36784

DATE

2/9/26

PRESENTING CLINICAL SIGNS

- Increased PSL
- Cutaneous growth, tense abdomen, nuclear sclerosis, vertebral pain, severe dental dz
- Current med: Clinda, Pred, Traz PRN
- Abnormal PE/Chem/CBC/UA Results: Hyperglob, Increased amylase, increased PrecPSL

ULTRASONOGRAPHIC EXAMINATION OF THE ABDOMEN

Urinary System

Urinary bladder is adequately distended with anechoic contents. No masses, inflammatory changes, echogenic sediment or cystoliths are observed. The urinary bladder, trigone and visible pelvic urethra are normal in thickness with a smooth mucosal surface.

Left kidney is normal in size (3.99 cm), shape and echogenicity. It has smooth peripheral margination. There is a normal 1:3 cortex to medulla ratio with appropriate corticomedullary distinction. There is no evidence of pyelectasia, mineral or infarcts observed.

Right kidney is normal in size (4.09 cm), shape and echogenicity. It has smooth peripheral margination. There is a normal 1:3 cortex to medulla ratio with appropriate corticomedullary distinction. There is no evidence of pyelectasia, mineral or infarcts observed.

Adrenal Glands

Left adrenal gland is normal in size (0.47 cm at cranial pole and 0.43 cm at caudal pole), shape and overall architecture, echogenicity and echotexture. Visible surrounding vasculature appears normal.

Right adrenal gland is normal in size (0.74 cm at cranial pole and 0.55 cm at caudal pole), shape and overall architecture, echogenicity and echotexture. Visible surrounding vasculature appears normal.

Spleen

Spleen is subjectively normal in size with a normal smooth capsular contour. Parenchyma is appropriately finely textured and homogenous with normal echogenicity relative to surrounding tissue (hyperechoic to liver). No focal nodules or masses are observed. Splenic vasculature appears normal.

Liver

Liver is subjectively enlarged with mildly irregular margins. Parenchyma is mildly heterogenous characterized by multiple poorly defined hypoechoic nodules within otherwise hyperechoic liver parenchyma. Visible vasculature and biliary tree appear normal without distension or congestion.

Gallbladder is non-distended in size. The wall is smooth without visible thickening. Luminal contents are primarily anechoic. There is no evidence of cystic or common bile duct dilation.

Gastrointestinal



PATIENT

Leidy Isler

SPECIES

Canine

BREED

Maltipoo

SEX

Spayed Female

AGE

13 Years

WEIGHT

12.2 Pounds

INTERPRETED BY

Beth Johnson, DVM
 DACVIM

IMAGING PERFORMED BY

Meghan Morse, LVT,
 CVT

HOSPITAL NAME

Animal General on
 Hudson

REFERRING VET

Dr. DiGiuseppi

INVOICE

36784

DATE

2/9/26

The visible stomach wall is normal in thickness and layering. The lumen of the stomach is mildly distended with a small to moderate amount of echogenic non-shadowing luminal contents and gas consistent with normal ingesta. There is no evidence of obstruction, foreign material or infiltrative disease. Pyloric outflow tract appears patent.

The visible small intestines are normal in wall thickness and layering. Small intestinal motility appears adequate (1-3 contractions per min). The lumen of the small intestine is mildly distended with echogenic non-shadowing luminal contents and gas consistent with normal ingesta/chyme. There is no evidence of obstruction, foreign material or infiltrative disease.

The visible colon is normal in wall thickness (< 0.2 cm) and layering. Contents are consistent with normal formed feces and gas.

Pancreas

The pancreas that is observed appears appropriately isoechoic to surrounding omental fat. Visible capsule is smooth and normal in contour. Visible pancreatic parenchyma is homogenous and unremarkable. There is no visible pancreatic duct dilation. There is no evidence of active peripancreatic inflammation.

Free Abdomen

There is no visible free peritoneal effusion noted in these images.

There is no apparent pathologic lymphadenopathy noted in these images.

ULTRASONOGRAPHIC FINDINGS

- Mildly heterogenous liver- These changes are most consistent with benign processes such as nodular hyperplasia, steroid (vacuolar) hepatopathy, extramedullary hematopoiesis or possibly chronic inflammatory disease and less commonly infiltrative round cell or metastatic neoplasia.

INTERPRETATION OF THE FINDINGS & FURTHER RECOMMENDATIONS

There is no definitive ultrasonographically visible evidence of pancreatitis present in these images at this time. Having said that, chronic low grade smoldering pancreatitis can't be definitively ruled out. Further recommendations are largely dependent on patient's clinical signs, but could potentially include a diet change if indicated. Given the concurrent hyperglobulinemia, if an underlying cause, such as severe dental disease versus other isn't known, further work up of that may be indicated as well.



PATIENT

Leidy Isler

SPECIES

Canine

BREED

Maltipoo

SEX

Spayed Female

AGE

13 Years

WEIGHT

12.2 Pounds

INTERPRETED BY

Beth Johnson, DVM
 DACVIM

IMAGING PERFORMED BY

Meghan Morse, LVT,
 CVT

HOSPITAL NAME

Animal General on
 Hudson

REFERRING VET

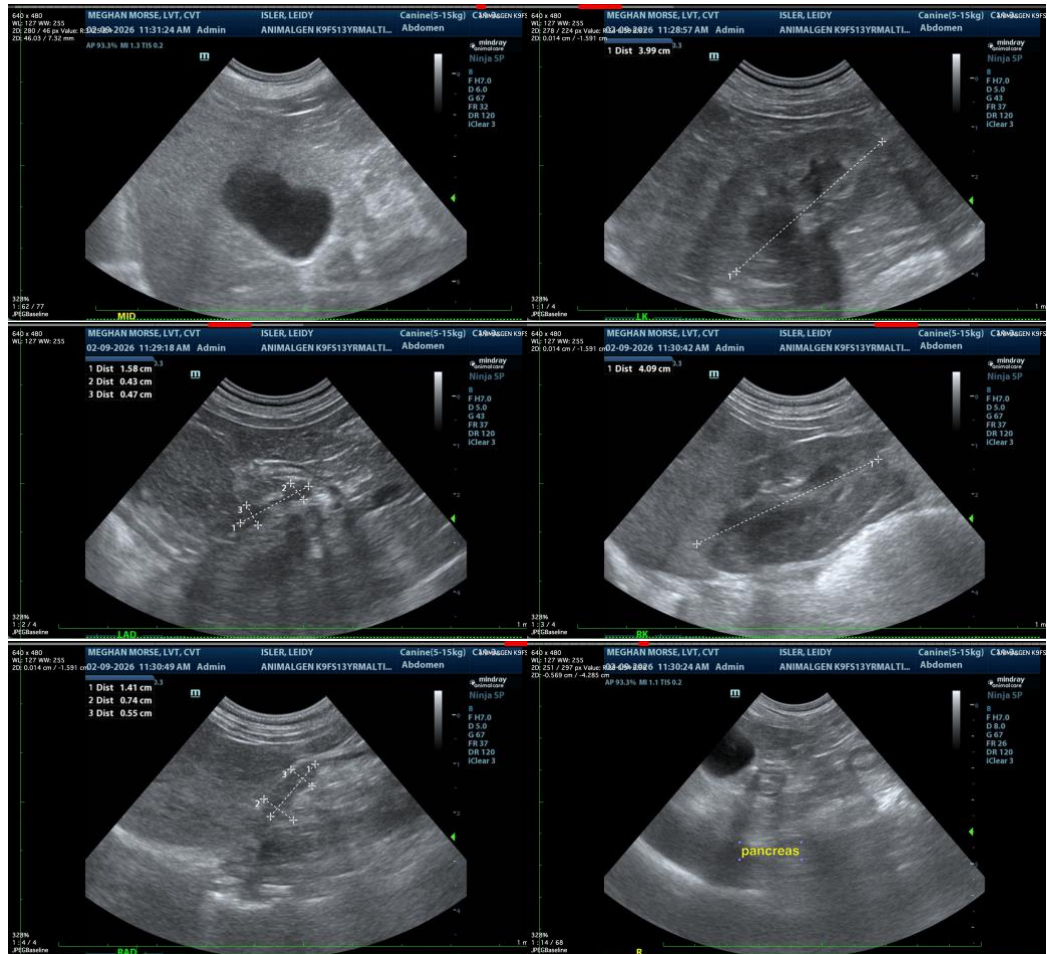
Dr. DiGiuseppi

INVOICE

36784

DATE

2/9/26



The information and recommendations provided are based on the images presented by the referring veterinarian/sonographer. No evaluation can be communicated regarding pathology that was not visible in the image/video clips provided.

Thank you for this referral. If the clinical or image interpretation does not parallel your findings or if I can be of any further assistance please contact me.

Beth Johnson, DVM DACVIM

info@sonopath.com