



**PATIENT**

Casey Paxson

**SPECIES**

Feline

**BREED**

DSH

**SEX**

Spayed Female

**AGE**

6 Years

**WEIGHT**

10.73 Pounds

**INTERPRETED BY**

Beth Johnson, DVM  
DACVIM

**IMAGING PERFORMED BY**

Sara Hansen

**HOSPITAL NAME**

VCA Salem AH

**REFERRING VET**

Dr. Frey

**INVOICE**

36778

**DATE**

2/9/26

**PRESENTING CLINICAL SIGNS**

- History: Seen at SVEC on 1/11/25 for vomiting, diarrhea, inappetence - performed BW (no abnormalities), gave SQ LRS fluids, injectable cerenia, radiographs were declined, sent home with fortiflora, & metronidazole. 1/13 - Has not vomited since visit at SVEC, but continued hyporexia. Inappetent - minimal intake of food over 5 days, unclear how many food options were offered to cat to encourage appetite. Not defecating - was having liquid diarrhea, now has not had a BM in 2 days. 2/3 - vomiting & diarrhea symptoms worsened since previous visit. Gaining weight. Gave SQ LRS, injectable cerenia, sent home cerenia & z/d diet. 2/9 - no diarrhea, eating has improved, might be using hill's z/d diet (O reported "hill's sensitive stomach").
- Abnormal PE/Chem/CBC/UA Results: ABNORMAL Labwork Values 1/11/26 - CBC/Chem Panc. lipase normal Current Medications 2/8/26 - Cerenia 4mg PO; to be giving injectable sedation today. Radiographic Findings None

**ULTRASONOGRAPHIC EXAMINATION OF THE ABDOMEN**

**Urinary System**

Urinary bladder is adequately distended. It has a normal uniform wall thickness. Contents include primarily anechoic fluid with occasional echogenic non-shadowing debris, most consistent with incidental suspended lipid in a cat, possibly combined with exfoliated cells, mucous and/or small blood clots. Both sterile inflammation as well as urinary tract infection can also present with echogenic debris. No masses or definitive cystoliths are observed. The trigone and visible pelvic urethra are normal in thickness with a smooth mucosal surface.

Left kidney is normal in size (4.29 cm), shape and echogenicity. It has smooth peripheral margination. There is a normal 1:3 cortex to medulla ratio with appropriate corticomedullary distinction. There is no evidence of pyelectasia, mineral or infarcts observed.

Right kidney is normal in size (4.4 cm), shape and echogenicity. It has smooth peripheral margination. There is a normal 1:3 cortex to medulla ratio with appropriate corticomedullary distinction. There is no evidence of pyelectasia, mineral or infarcts observed.

**Adrenal Glands**

Left adrenal gland is normal in size (0.3 cm), shape and overall architecture, echogenicity and echotexture. Visible surrounding vasculature appears normal.

Right adrenal gland is normal in size (0.36 cm), shape and overall architecture, echogenicity and echotexture. Visible surrounding vasculature appears normal.

**Spleen**

Spleen is subjectively normal in size with a normal smooth capsular contour. Parenchyma is appropriately finely textured and homogenous with normal echogenicity relative to surrounding tissue (hyperechoic to liver). No focal nodules or masses are observed. Splenic vasculature appears normal.

**Liver**



**PATIENT**

Casey Paxson

**SPECIES**

Feline

**BREED**

DSH

**SEX**

Spayed Female

**AGE**

6 Years

**WEIGHT**

10.73 Pounds

**INTERPRETED BY**

Beth Johnson, DVM  
DACVIM

**IMAGING PERFORMED BY**

Sara Hansen

**HOSPITAL NAME**

VCA Salem AH

**REFERRING VET**

Dr. Frey

**INVOICE**

36778

**DATE**

2/9/26

Liver is subjectively normal in size with normal smooth curvilinear peripheral contour. Parenchyma is appropriately hypoechoic to the spleen in echogenicity and appropriately mildly coarse and homogenous in echotexture. No focal lesions are observed. Visible vasculature and biliary tree appear normal without distension or congestion.

Gallbladder is non-distended in size. The wall is smooth without visible thickening. Luminal contents are primarily anechoic. There is no evidence of cystic or common bile duct dilation.

***Gastrointestinal***

The visible stomach wall is normal in thickness and layering. The lumen of the stomach is empty with no evidence of obstruction, foreign material or infiltrative disease. Pyloric outflow tract appears patent.

The visible small intestine demonstrates areas of very prominently thick muscularis layer relative to mucosa (disruption of the normal 1:3 muscularis:mucosa ratio). Small intestinal submucosa is slightly irregular, thick and hyperechoic, without evident loss of layering appreciated. The lumen of the small intestine is empty with no evidence of obstruction or foreign material.

The visible colon is normal in wall thickness (< 0.2 cm) and layering. Contents are consistent with normal formed feces and gas.

***Pancreas***

The pancreas that is observed appears appropriately isoechoic to surrounding omental fat. Visible capsule is smooth and normal in contour. Visible pancreatic parenchyma is homogenous and unremarkable. There is no visible pancreatic duct dilation. There is no evidence of active peripancreatic inflammation.

***Free Abdomen***

There is no visible free peritoneal effusion noted in these images.

There is no apparent pathologic lymphadenopathy noted in these images.

**ULTRASONOGRAPHIC FINDINGS**

- Marked/significant inflammatory bowel disease pattern- Thick muscularis has been reported with infiltrative bowel disease including both benign inflammatory disease as well as infiltrative neoplasia such as lymphoma. No loss of layering or distinct characteristics of malignancy are present. Therefore, differentials cannot be further ranked without tissue sampling.
- A moderate amount of echogenic urinary bladder debris

**INTERPRETATION OF THE FINDINGS & FURTHER RECOMMENDATIONS**

- A gastrointestinal malabsorption panel (including cobalamin, folate, TLI and PLI) to Texas A&M GI Laboratory is recommended for further evaluation of GI and pancreatic function.



**PATIENT**

Casey Paxson

**SPECIES**

Feline

**BREED**

DSH

**SEX**

Spayed Female

**AGE**

6 Years

**WEIGHT**

10.73 Pounds

**INTERPRETED BY**

Beth Johnson, DVM  
DACVIM

**IMAGING PERFORMED BY**

Sara Hansen

**HOSPITAL NAME**

VCA Salem AH

**REFERRING VET**

Dr. Frey

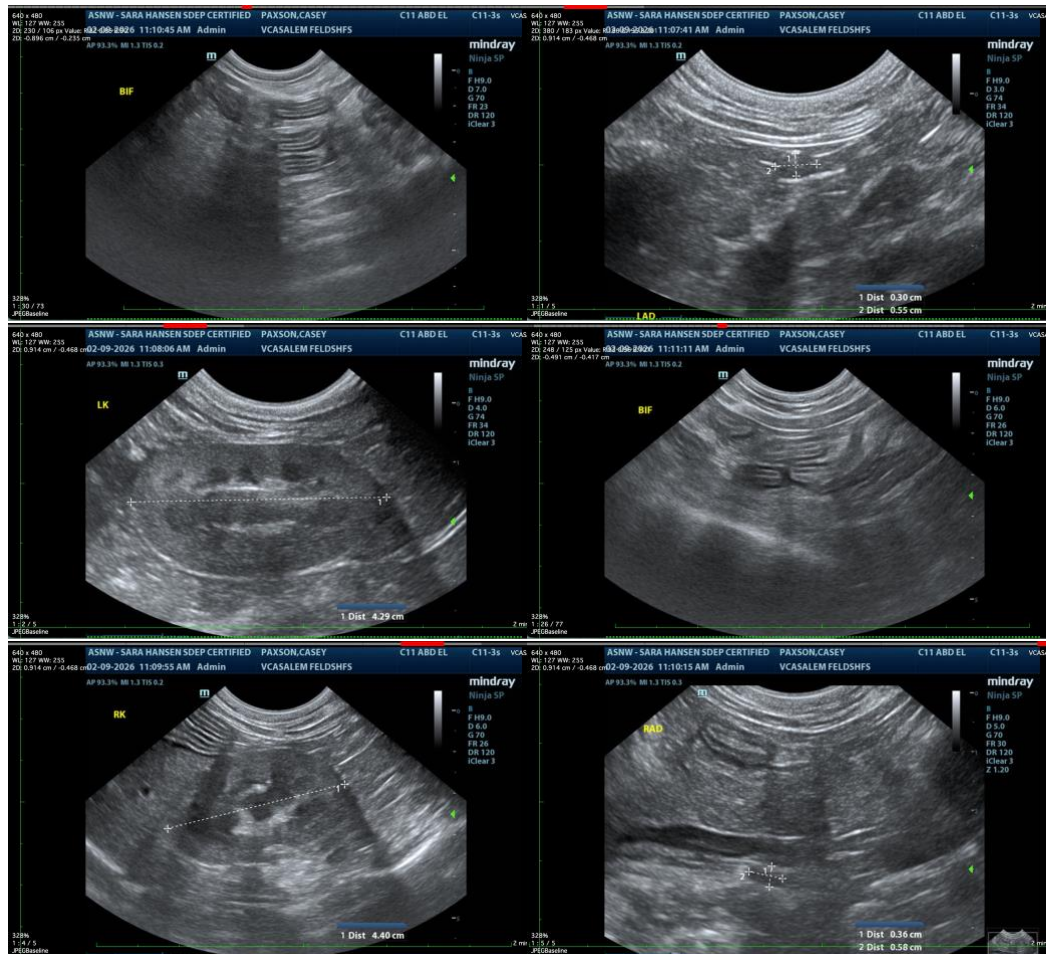
**INVOICE**

36778

**DATE**

2/9/26

- A fecal enteropathogen PCR panel to Texas A&M GI Laboratory could be considered for further evaluation of possible infectious disease. Contact lab for recommendations on how long to discontinue antibiotics (if indicated) prior to obtaining a stool sample for submission.
- Ideally, biopsies of the GI tract, being sure to include ileum, if possible, are recommended to definitively diagnose and therefore manage the infiltrative bowel disease.
- If biopsies cannot be obtained, empirical therapies could include a probiotic (if diarrhea is present, such as visbiome or proviable), empirical deworming with a 5-day course of Panacur and, if tolerated, a transition in diet, based on trial-and-error response, beginning with a hydrolyzed protein diet. Some patients respond to one brand/version of a hydrolyzed protein diet better than another brand, so several trials may be required.
- Additional considerations could include cobalamin supplementation (unless cobalamin level is evaluated and supplementation is not warranted) and prednisolone (if not contraindicated based on patient contraindications, co-morbidities, etc.).





**PATIENT**

Casey Paxson

**SPECIES**

Feline

**BREED**

DSH

**SEX**

Spayed Female

**AGE**

6 Years

**WEIGHT**

10.73 Pounds

**INTERPRETED BY**

Beth Johnson, DVM  
DACVIM

**IMAGING PERFORMED BY**

Sara Hansen

**HOSPITAL NAME**

VCA Salem AH

**REFERRING VET**

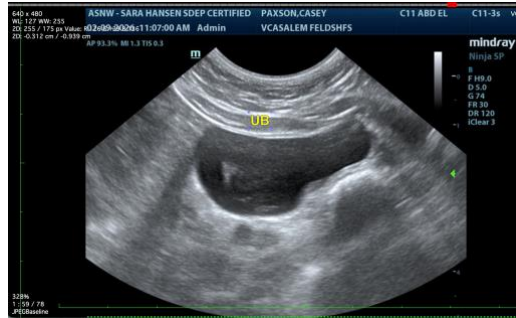Dr. Frey

**INVOICE**

36778

**DATE**

2/9/26



**The information and recommendations provided are based on the images presented by the referring veterinarian/sonographer. No evaluation can be communicated regarding pathology that was not visible in the image/video clips provided.**

Thank you for this referral. If the clinical or image interpretation does not parallel your findings or if I can be of any further assistance please contact me.

**Beth Johnson, DVM DACVIM**

info@sonopath.com