



PATIENT PRESENTING CLINICAL SIGNS

Murphy Gilfillan Vomiting x3 days, Severely dehydrated, lethargy, anorexia, heart murmur

SPECIES Abnormal PE/Chem/CBC/UA Results: SDMA 18 CREAT 1.6 NA 156 CH 105 TP 8.7 ALB 4.1 GLOB 4.6
Lepto titers pending

Canine

BREED ULTRASONOGRAPHIC EXAMINATION OF THE ABDOMEN

Mix

Urinary System

The urinary bladder is moderately distended with anechoic contents. No masses, inflammatory changes, echogenic sediment or cystoliths are observed. The urinary bladder, trigone and visible pelvic urethra are normal in thickness with a smooth mucosal surface.

SEX

Neutred Male

The area of the prostate is examined without evident prostatic pathology.

AGE

11.5

Kidneys are overall normal in size and shape with smooth peripheral margination. A normal 1:3 cortex to medulla ratio is maintained. The medulla and cortices are uniform in texture with some mild increased cortical echogenicity and mild loss of corticomedullary distinction, expected in this age patient. There is no evidence of pyelectasia, mineral or infarcts observed. The left kidney measures 6.0 cm. The right kidney measures 5.75 cm.

WEIGHT

50 Pounds

Adrenal Glands

INTERPRETED BY The right adrenal gland is unable to be well visualized in these images.

Beth Johnson, DVM
DACVIM

The left adrenal gland is normal in size (0.44 cm at the cranial pole and 0.48 cm at the caudal pole), shape and contour. Corticomedullary structure is unremarkable. Visible surrounding vasculature appears normal.

Spleen

IMAGING PERFORMED BY

Dr. Travis Cerf

Spleen is subjectively large in size with normal smooth margins. Parenchyma is normal in echogenicity with a coarse/heterogenous echotexture. No focal nodules or masses are observed. Splenic vasculature appears normal.

HOSPITAL NAME

Veterinary Center
Of Hardyston

Liver

Liver is subjectively enlarged (swollen contour). Mild parenchymal remodeling with diffusely mildly coarse architecture and increased portal markings is present. No focal nodules or masses are observed. Visible vasculature and biliary tree appear normal without distension or congestion.

REFERRING VET

Dr. Travis Cerf

Gallbladder is moderately distended with anechoic bile as well as mild to moderate suspended and gravity dependent echogenic debris. The wall is smooth without visible thickening. There is no evidence of cystic or CBD dilation. There is no evidence of effusion or inflammation.

INVOICE

44972

Gastrointestinal

DATE

2/9/23

Fundic mucosal hypertrophy with hyperechoic mucosa and some mucosal remodeling is noted. There is no loss of mural detail. Layering is normal. There is mild luminal fluid accumulation. No evidence of masses/nodules or foreign material present.

The bowel is diffusely normal in thickness and normal in layering with some visible small bowel loops being empty. However, focally, there are small bowel loops that appear thick. One of these areas contains echogenic luminal contents with strong acoustic shadowing, consistent with foreign material.



PATIENT

Murphy Gilfillan

Other loops of small bowel are dilated, which, when combined with the normal empty small bowel loops, is a characteristic obstructive pattern.

SPECIES

Canine

The visible colon is normal in wall thickness (< 0.2 cm) and layering. Contents are consistent with normal formed feces and gas.

Pancreas

BREED

Mix

The observed pancreas is prominent (enlarged) in size, hypoechoic to surrounding tissue and irregular in shape with a swollen undulating contour. Enhanced hyperechoic ill-defined surrounding fat is noted.

Free Abdomen

SEX

Neutred Male

There is a scant amount of anechoic free fluid, as well as enhanced hyperechoic mesenteric fat surrounding the suspected small bowel/jejunal foreign body.

There is no apparent lymphadenopathy noted in these images.

AGE

11.5

PRIMARY FINDINGS

WEIGHT

50 Pounds

- **Suspect small bowel obstruction** – Given the appearance of the intestines at and around the suspected foreign material, infiltrative bowel disease, even infiltrative neoplasia resulting in obstruction of normal ingesta versus an actual foreign body, is also possible. Unfortunately, these differentials can't be differentiated without an exploratory laparotomy. The free fluid and enhanced mesenteric fat in the area are suggestive of a focal peritonitis.

INTERPRETED BY

Beth Johnson, DVM
DACVIM

- **Gastritis** – Consistent with irritation secondary to dietary indiscretion or intolerance, infection (bacterial, viral, other), parasitic or protozoal disease, toxin, other metabolic disease such as pancreatitis, other. Microulceration cannot be ruled out.

- Concurrent acute pancreatitis

IMAGING PERFORMED BY

Dr. Travis Cerf

- **Coarse splenomegaly** – can be associated with congestion caused by sedation (if sedated) but can also be associated with diffuse infiltrative disease. Both benign conditions such as extramedullary hematopoiesis, lymphoid hyperplasia, as well as infiltrative neoplastic diseases such as round cell neoplasia should be considered.

HOSPITAL NAME

Veterinary Center
Of Hardyston

- **Hypoechoic hepatomegaly** – This appearance is consistent with an acute hepatopathy or acute cholangiohepatitis. Infiltrative neoplasia (round cell neoplasia) should also be considered.

REFERRING VET

Dr. Travis Cerf

SECONDARY FINDINGS

- Age related kidney changes

INVOICE

44972

- **Mild to moderate gallbladder debris** - Cholecystic debris is of unknown clinical significance. It can be seen with biliary stasis from fasting or illness. Cholecystic debris is not necessarily related to hepatobiliary disease. Echogenic bile is most commonly an incidental finding in dogs and should be interpreted in combination with clinical signs such as nausea, inappetence, cranial abdominal discomfort and/or laboratory changes such as increased ALP and/or increased Tbili.

DATE

2/9/23

INTERPRETATION OF THE FINDINGS & FURTHER RECOMMENDATIONS

It is difficult to definitively determine whether the primary underlying cause of the suspected obstruction in this patient is foreign material with inflammatory changes in the bowel secondary to



PATIENT

Murphy Gilfillan

foreign material, or stasis/partial obstruction of normal ingesta/chyme secondary to infiltrative bowel disease.

SPECIES

Canine

Recommendations include an exploratory laparotomy for planned foreign body removal, if present, as well as full thickness biopsies of the described affected/thick bowel.

BREED

Mix

Additionally, biopsies of the spleen and liver could be considered, pending patient's stability during surgery.

SEX

Neutred Male

Prior to surgery, three view thoracic radiographs are recommended for further assessment of cardio-pulmonary status as well as to further evaluate for any evidence of metastatic disease, if not recently evaluated, as well as rehydration/stabilization, given this patient's reported marked dehydration.

AGE

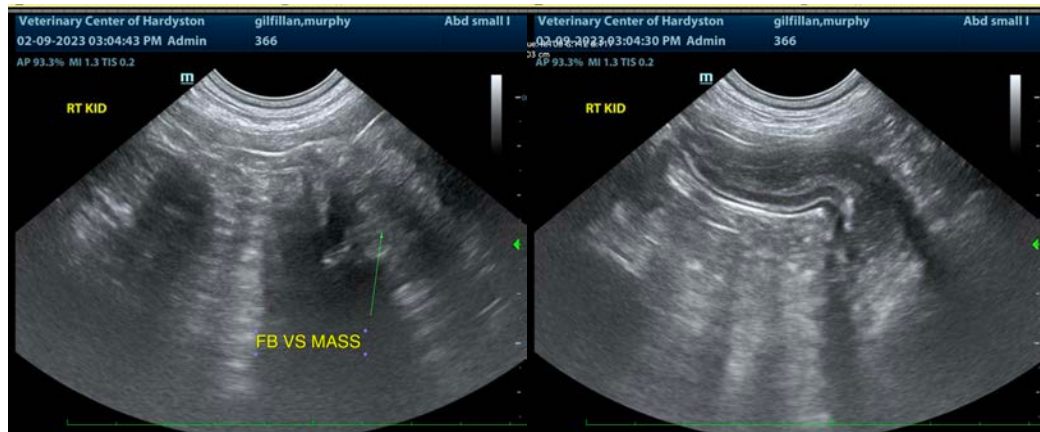
11.5

WEIGHT

50 Pounds

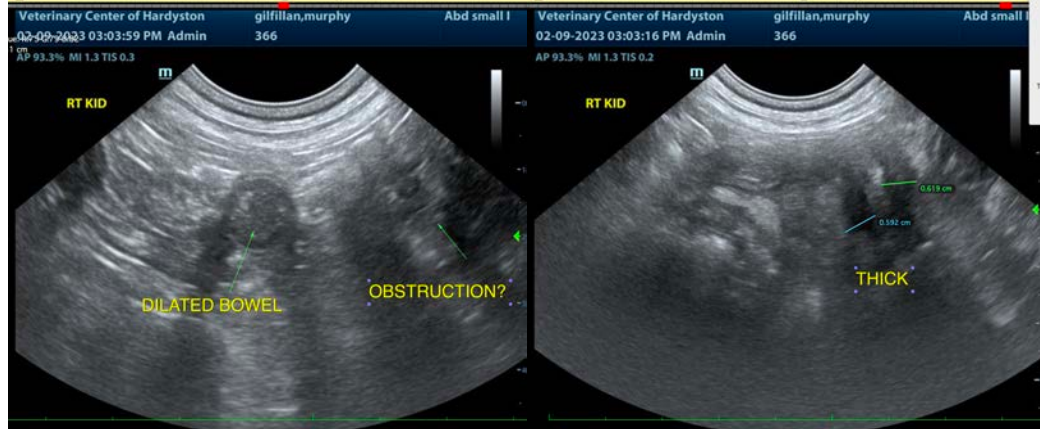
INTERPRETED BY

Beth Johnson, DVM
DACVIM



IMAGING PERFORMED BY

Dr. Travis Cerf



HOSPITAL NAME

Veterinary Center
Of Hardyston

REFERRING VET

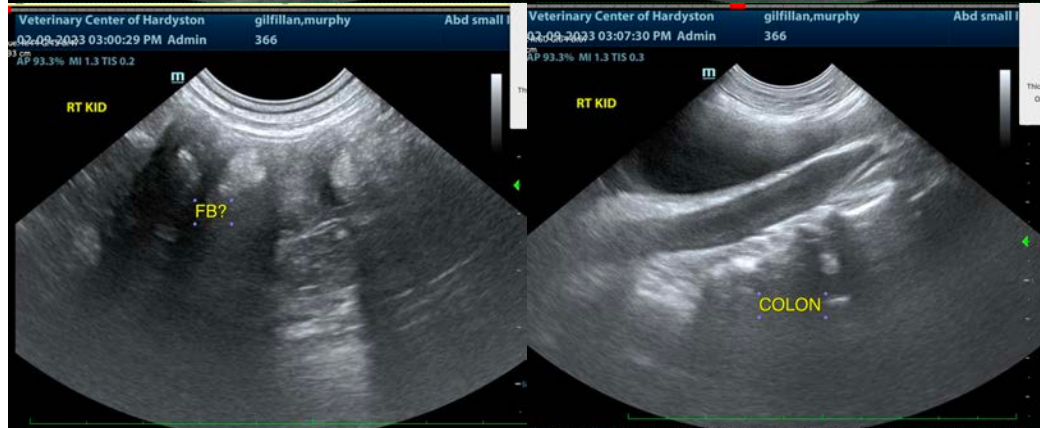
Dr. Travis Cerf

INVOICE

44972

DATE

2/9/23





PATIENT

Murphy Gilfillan

SPECIES

Canine

BREED

Mix

SEX

Neutred Male

AGE

11.5

WEIGHT

50 Pounds

INTERPRETED BY

Beth Johnson, DVM
DACVIM

IMAGING PERFORMED BY

Dr. Travis Cerf

HOSPITAL NAME

Veterinary Center
Of Hardyston

REFERRING VET

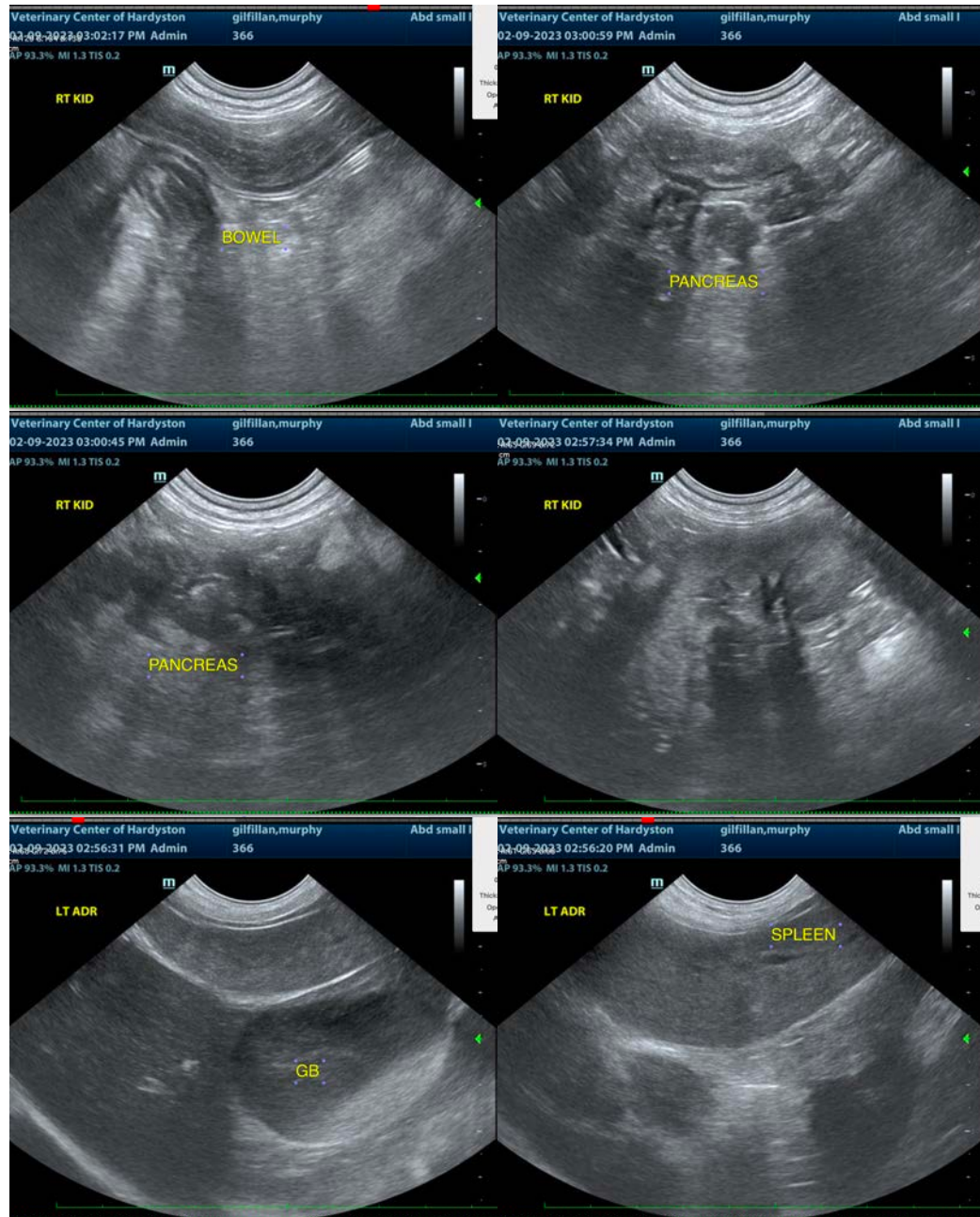
Dr. Travis Cerf

INVOICE

44972

DATE

2/9/23





PATIENT

Murphy Gilfillan

SPECIES

Canine

BREED

Mix

SEX

Neutred Male

AGE

11.5

WEIGHT

50 Pounds

INTERPRETED BY

Beth Johnson, DVM
DACVIM

IMAGING PERFORMED BY

Dr. Travis Cerf

HOSPITAL NAME

Veterinary Center
Of Hardyston

REFERRING VET

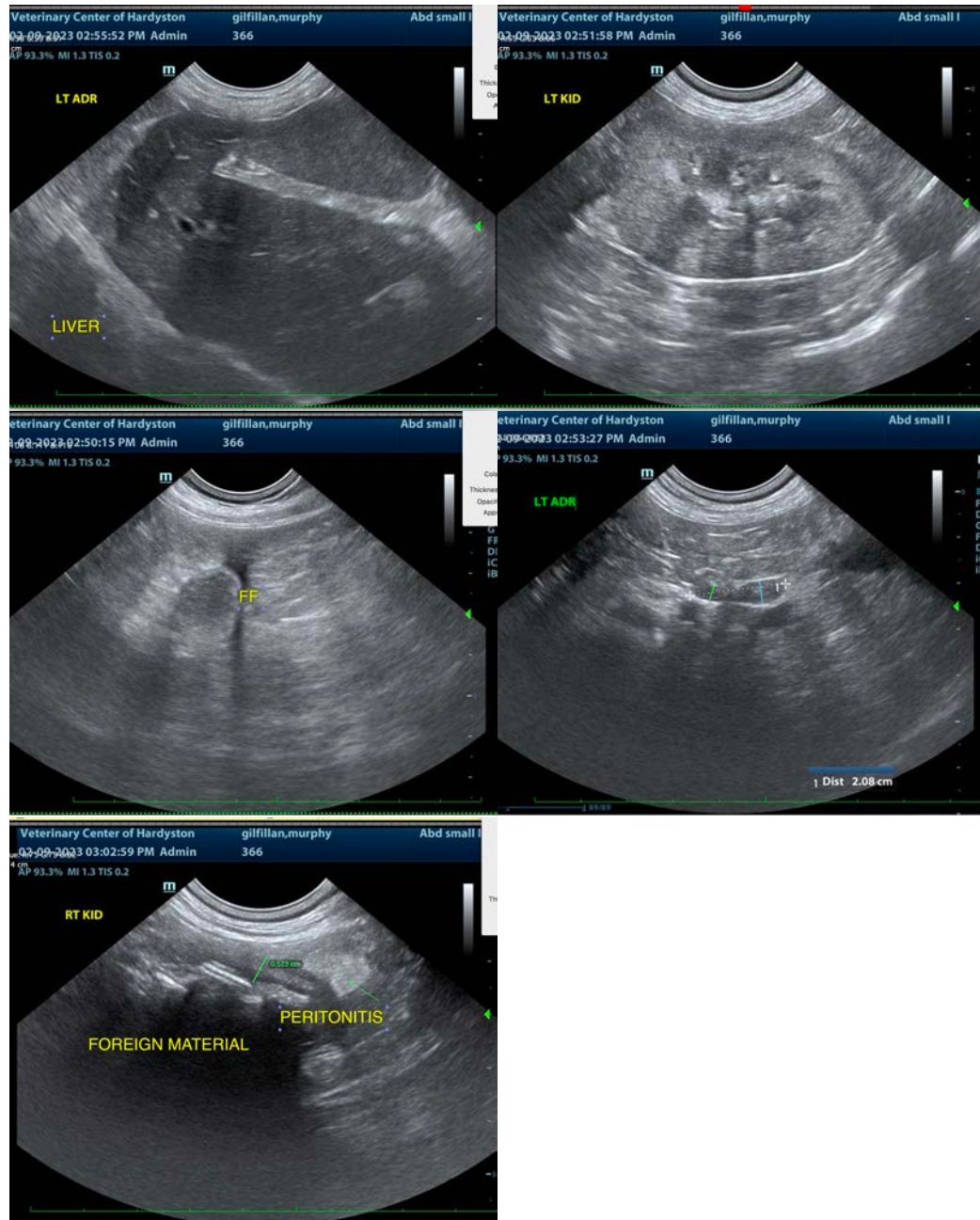
Dr. Travis Cerf

INVOICE

44972

DATE

2/9/23



The information and recommendations provided are based on the images presented by the referring veterinarian/sonographer. No evaluation can be communicated regarding pathology that was not visible in the image/video clips provided.

Thank you for this referral. If the clinical or image interpretation does not parallel your findings or if I can be of any further assistance please contact me.

Beth Johnson, DVM, DACVIM
Beth.Johnson@sonopath.com