



**PATIENT PRESENTING CLINICAL SIGNS**

Mindy Robichaud Recurrent anorexia and vomiting, diarrhea meds: mirtazapine

**SPECIES ULTRASONOGRAPHIC EXAMINATION OF THE ABDOMEN**

Canine

**Urinary System**

BREED

The urinary bladder is moderately distended with anechoic contents. No masses, inflammatory changes, echogenic sediment or cystoliths are observed. The urinary bladder, trigone and visible pelvic urethra are normal in thickness with a smooth mucosal surface.

Shep X

SEX

The right kidney is normal in size (5.08 cm), shape and echogenicity. It has smooth peripheral margination. There is a normal 1:3 cortex to medulla ratio with appropriate corticomedullary distinction. There is no evidence of pyelectasia, mineral or infarcts observed.

Spayed Female

AGE

The left kidney is normal in size (5.39 cm), shape and echogenicity. It has smooth peripheral margination. There is a normal 1:3 cortex to medulla ratio with appropriate corticomedullary distinction. There is no evidence of pyelectasia, mineral or infarcts observed.

2 Years

WEIGHT

**Adrenal Glands**

19.5 kg

The right adrenal gland is normal in size (1.84 cm long x 1.31 cm at the cranial pole and 0.83 cm at the caudal pole), shape and contour. Corticomedullary structure is unremarkable. Visible surrounding vasculature appears normal.

**INTERPRETED BY**

Beth Johnson, DVM  
DACVIM

The left adrenal gland is normal in size (2.26 cm long x 0.66 cm at the cranial pole and 0.60 cm at the caudal pole), shape and contour. Corticomedullary structure is unremarkable. Visible surrounding vasculature appears normal.

**Spleen**

**IMAGING PERFORMED BY**

Kelly Reschny

The spleen is subjectively normal in size with a normal smooth capsular contour. Parenchyma is appropriately finely textured and homogenous with normal echogenicity relative to surrounding tissue (hyperechoic to liver). No focal nodules or masses are observed. Splenic vasculature appears normal.

**HOSPITAL NAME**

Burlington Lakeshore

**Liver**

The liver is subjectively normal in size with normal smooth curvilinear peripheral contour. Parenchyma is appropriately hypoechoic to the spleen in echogenicity and appropriately mildly coarse and homogenous in echotexture. No focal lesions are observed. Visible vasculature and biliary tree appear normal without distension or congestion.

**REFERRING VET**

Dr. Aziz

The gallbladder is non-distended in size. The wall is smooth without visible thickening. Luminal contents are primarily anechoic. There is no evidence of cystic or common bile duct dilation.

**INVOICE**

44989

**Gastrointestinal**

DATE

2/9/23

The visible stomach wall is normal in thickness and layering. The lumen of the stomach is mildly distended with very echogenic reverberation artifact from intraluminal gas. There is no evidence of obstruction, foreign material or infiltrative disease; however, complete visualization of far wall is partially inhibited by gas. Pyloric outflow tract appears patent.

The visible small intestines are normal in wall thickness and layering (canine duodenum < 0.5 cm and feline duodenum < 0.4 cm; other < 0.3 cm). Small intestinal motility appears adequate (1-3 contractions per min). The lumen of the small intestine is empty with no evidence of obstruction, foreign material or infiltrative disease.



## PATIENT

Mindy Robichaud

The visible colon is normal in wall thickness (< 0.2 cm) and layering. Contents are consistent with normal formed feces and gas.

## SPECIES

Canine

## Pancreas

The pancreatic parenchyma is appropriately isoechoic to surrounding tissue. Visible capsule is smooth and normal in contour. There is no visible pancreatic duct dilation. There is no evidence of active peripancreatic inflammation.

## BREED

Shep X

## Free Abdomen

## SEX

There is no evidence of free peritoneal effusion noted in these images.

Spayed Female

The mesenteric lymph nodes are prominent in size with swollen capsular contour. Normal elongated shape (length to width ratio) is maintained. There is no loss of parenchymal detail.

## AGE

2 Years

## ULTRASONOGRAPHIC FINDINGS

- **Reactive mesenteric lymph nodes** – infiltrative neoplastic disease cannot be ruled out but is considered less likely. This may in part be normal patient variant, given the patient's young age.

## WEIGHT

19.5 kg

## INTERPRETATION OF THE FINDINGS & FURTHER RECOMMENDATIONS

## INTERPRETED BY

Beth Johnson, DVM  
DACVIM

Given patient breed, ruling out exocrine pancreatic insufficiency with a TLI is recommended. Therefore, a gastrointestinal malabsorption panel (including cobalamin, folate, TLI and PLI) to Texas A&M GI Laboratory is recommended for further evaluation of GI and pancreatic function.

Pending results, given the patient's young age, a fecal enteropathogen PCR panel to Texas A&M GI Laboratory could be considered for further evaluation of possible infectious disease.

## IMAGING PERFORMED BY

Kelly Reschny

In the meantime, empirical deworming with a 5-day course of Panacur is recommended, as is a probiotic such as Visbiome or Provable, as well as, if tolerated, a transition in diet could be considered based on trial-and-error response, potentially beginning with a hydrolyzed protein diet, understanding that some patients need several trial with different brands prior to finding the right match. Other considerations could include a low-fat or easy to digest diet, or a higher fiber colitis diet, again pending patient response.

## HOSPITAL NAME

Burlington Lakeshore

## REFERRING VET

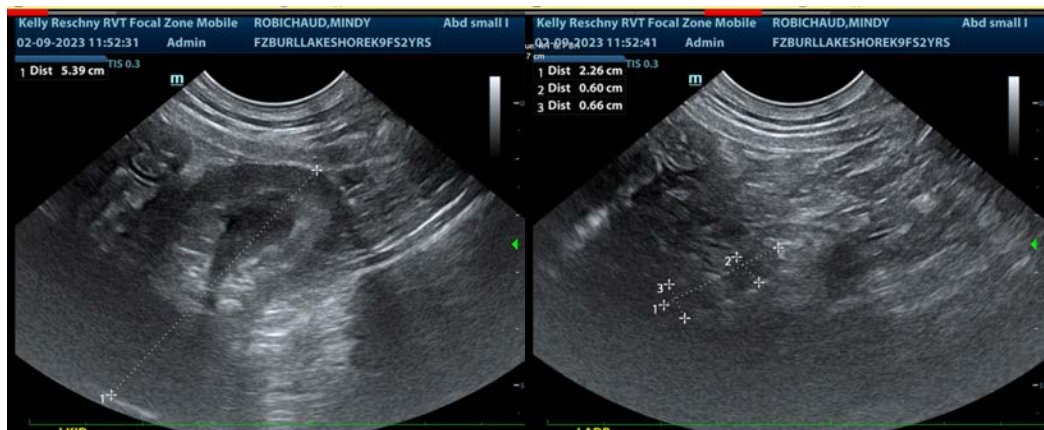
Dr. Aziz

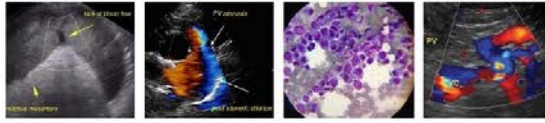
## INVOICE

44989

## DATE

2/9/23





**PATIENT**

Mindy Robichaud

**SPECIES**

Canine

**BREED**

Shep X

**SEX**

Spayed Female

**AGE**

2 Years

**WEIGHT**

19.5 kg

**INTERPRETED BY**

Beth Johnson, DVM  
DACVIM

**IMAGING  
PERFORMED BY**

Kelly Reschny

**HOSPITAL NAME**

Burlington Lakeshore

**REFERRING VET**

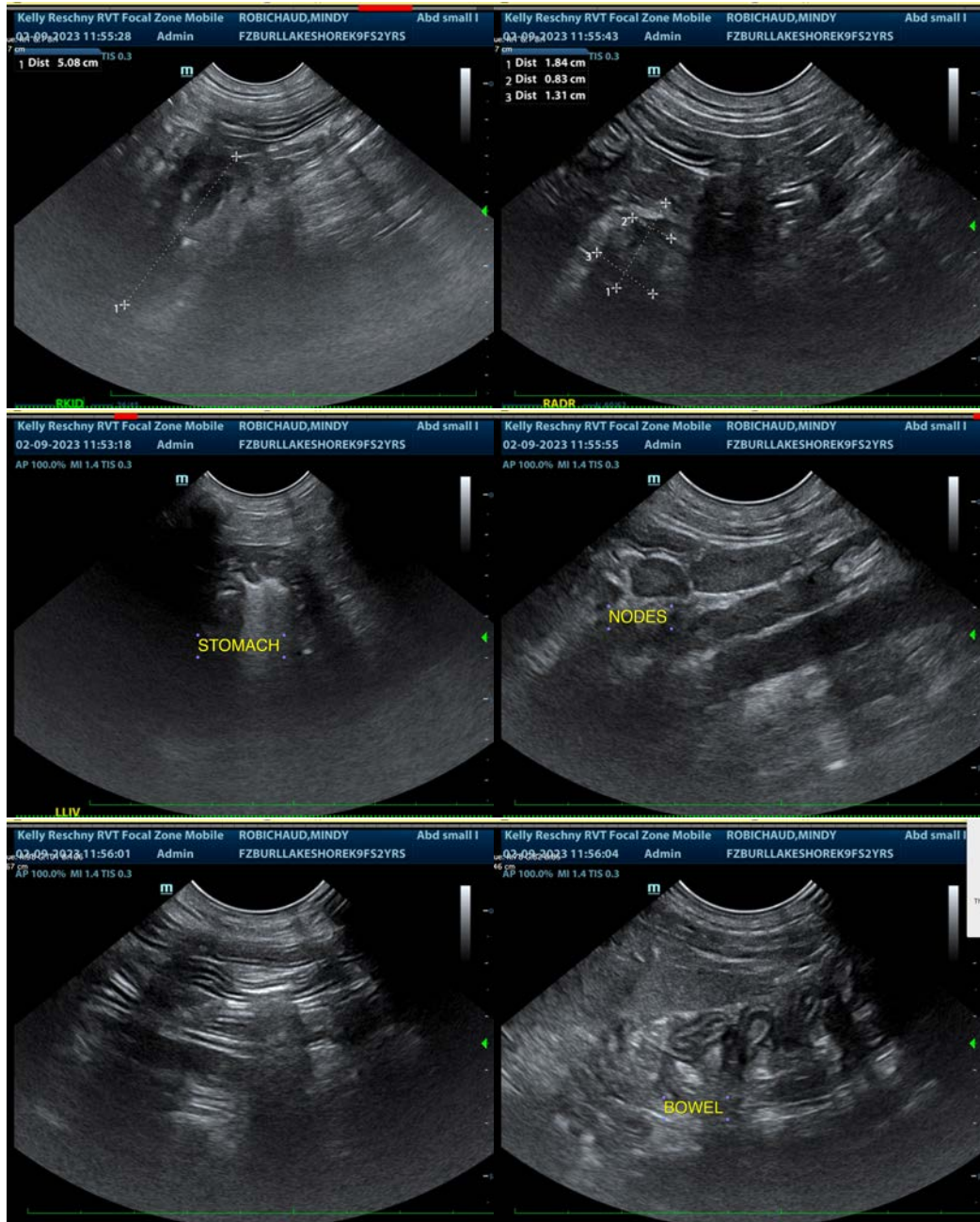
Dr. Aziz

**INVOICE**

44989

**DATE**

2/9/23



The information and recommendations provided are based on the images presented by the referring veterinarian/sonographer. No evaluation can be communicated regarding pathology that was not visible in the image/video clips provided.

Thank you for this referral. If the clinical or image interpretation does not parallel your findings or if I can be of any further assistance please contact me.

**Beth Johnson, DVM, DACVIM**  
Beth.Johnson@sonopath.com