



**PATIENT**

Mei Baker

**SPECIES**

Canine

**BREED**

Pointer X

**SEX**

Spayed Female

**AGE**

5 Years

**WEIGHT**

42.8 Pounds

**INTERPRETED BY**

Beth Johnson, DVM  
DACVIM

**IMAGING PERFORMED BY**

Samantha Hugins

**HOSPITAL NAME**

Petvacx AH

**REFERRING VET**

Dr. Rachel Wiley

**INVOICE**

35558

**DATE**

2/9/22

**PRESENTING CLINICAL SIGNS**

5d ago shredded up and ate a tennis ball, 3 days ago stopped eating and developed soft stool. Drinking water okay. Last night started vomiting with some blood and Velcro in vomit.  
Abnormal PE/Chem/CBC/UA Results: PE Within Normal Limits except tender on palpation of cranial abdomen. CBC Within Normal Limits Chem- mild elevation in ALT, tBili

**ULTRASONOGRAPHIC EXAMINATION OF THE ABDOMEN**

**Urinary System**

Urinary bladder is moderately distended. It has a normal uniform wall thickness (<0.2 cm). Contents include primarily anechoic fluid combined with both gravity dependent and suspended echogenic non-shadowing debris within the fluid. No masses or cystoliths are observed. The trigone and visible pelvic urethra are normal in thickness with a smooth mucosal surface.

The right kidney is normal in size (5.9 cm), shape and echogenicity. It has smooth peripheral margination. There is a normal 1:3 cortex to medulla ratio with appropriate corticomedullary distinction. There is no evidence of pyelectasia, mineral or infarcts observed.

The left kidney is normal in size (5.8 cm), shape and echogenicity. It has smooth peripheral margination. There is a normal 1:3 cortex to medulla ratio with appropriate corticomedullary distinction. There is no evidence of pyelectasia, mineral or infarcts observed.

**Adrenal Glands**

The right adrenal gland is not discretely visible for measurements in these images. However, the region of the right adrenal gland was evaluated without evident pathology.

The left adrenal gland is normal in size (0.42 cm at the cranial pole and 0.46 cm at the caudal pole) and subjectively flat. Corticomedullary structure is unremarkable. Visible surrounding vasculature appears normal.

**Spleen**

The spleen is subjectively large in size with normal smooth margins. Parenchyma is normal and homogeneous in echogenicity. Mildly coarse echotexture. No focal nodules or masses are observed. Splenic vasculature appears normal.

**Liver**

The liver is subjectively normal in size with normal smooth curvilinear peripheral contour. Parenchyma is appropriately hypoechoic to the spleen in echogenicity and appropriately mildly coarse and homogenous in echotexture. No focal lesions are observed. Visible vasculature and biliary tree appear normal without distension or congestion.

The gallbladder is non-distended in size. The wall is smooth without visible thickening. Luminal contents are primarily anechoic. There is no evidence of cystic or common bile duct dilation.

**Gastrointestinal**

Gastric fundic mucosal hypertrophy with hyperechoic mucosa and some mucosal remodeling is noted. There is no loss of mural detail. Layering is normal. There is mild luminal fluid accumulation. No evidence of masses/nodules or foreign material present.

The visible small intestines are normal in wall thickness and layering (canine duodenum < 0.5 cm and feline duodenum < 0.4 cm; other < 0.3 cm). Small intestinal motility appears adequate (1-3 contractions



**PATIENT**

Mei Baker

per min). The lumen of the small intestine is empty with no evidence of obstruction, foreign material or infiltrative disease.

The visible colon is normal in wall thickness (< 0.2 cm) and layering. Contents are consistent with normal formed feces and gas.

**SPECIES**

Canine

***Pancreas***

The pancreatic parenchyma is appropriately isoechoic to surrounding tissue. Visible capsule is smooth and normal in contour. There is no visible pancreatic duct dilation. There is no evidence of active peripancreatic inflammation.

**BREED**

Pointer X

***Free Abdomen***

There is no evidence of peritoneal effusion. There is no apparent lymphadenopathy.

**SEX**

Spayed Female

**ULTRASONOGRAPHIC FINDINGS**

**AGE**

5 Years

- Gastritis – Microulceration cannot be ruled out.
- Urinary bladder sediment – Urine changes are most consistent with cellular debris or crystalluria.
- Splenomegaly – Can be associated with congestion caused by sedation, if sedated, but can also be associated with diffuse infiltrative disease. Both benign conditions such as extramedullary hematopoiesis, lymphoid hyperplasia, as well as infiltrative neoplastic diseases such as round cell neoplasia should be considered.
- Subjectively flat left adrenal gland and inability to visualize right adrenal gland – Rule out normal patient variant versus potential hypoadrenocorticism.

**WEIGHT**

42.8 Pounds

**INTERPRETED BY**

Beth Johnson, DVM  
DACVIM

**INTERPRETATION OF THE FINDINGS & FURTHER RECOMMENDATIONS**

Recommendations include baseline cortisol to further investigate possible hypoadrenocorticism. If the baseline cortisol is <2.0, then full ACTH stimulation test would be recommended. Urinalysis and urine culture (if indicated based on urinalysis results) are recommended if not recently performed due to the urinary bladder sediment. In the meantime, medical management of gastritis +/- microulceration is recommended in the form of antiemetics, gastroprotectants in the form of Sucralfate (given the recent hematemesis), etc.

**IMAGING PERFORMED BY**

Samantha Hugins

**HOSPITAL NAME**

Petvacx AH

If this patient was not sedated, and/or if clinical signs persist beyond medical management of gastritis, a fine needle aspirate of the spleen would be warranted if patient's coagulation status is appropriate. Finally, if cortisol levels are normal, and medical management of acute gastritis does not result in improvement of clinical signs, recheck imaging would be recommended. There is no evidence of obstruction at this time in the form of dilation, plication, etc. While unlikely, a foreign body cannot be definitively ruled out.

**REFERRING VET**

Dr. Rachel Wiley

**INVOICE**

35558

**DATE**

2/9/22



**PATIENT**

Mei Baker

**SPECIES**

Canine

**BREED**

Pointer X

**SEX**

Spayed Female

**AGE**

5 Years

**WEIGHT**

42.8 Pounds

**INTERPRETED BY**

Beth Johnson, DVM  
DACVIM

**IMAGING PERFORMED BY**

Samantha Hugins

**HOSPITAL NAME**

Petvacx AH

**REFERRING VET**

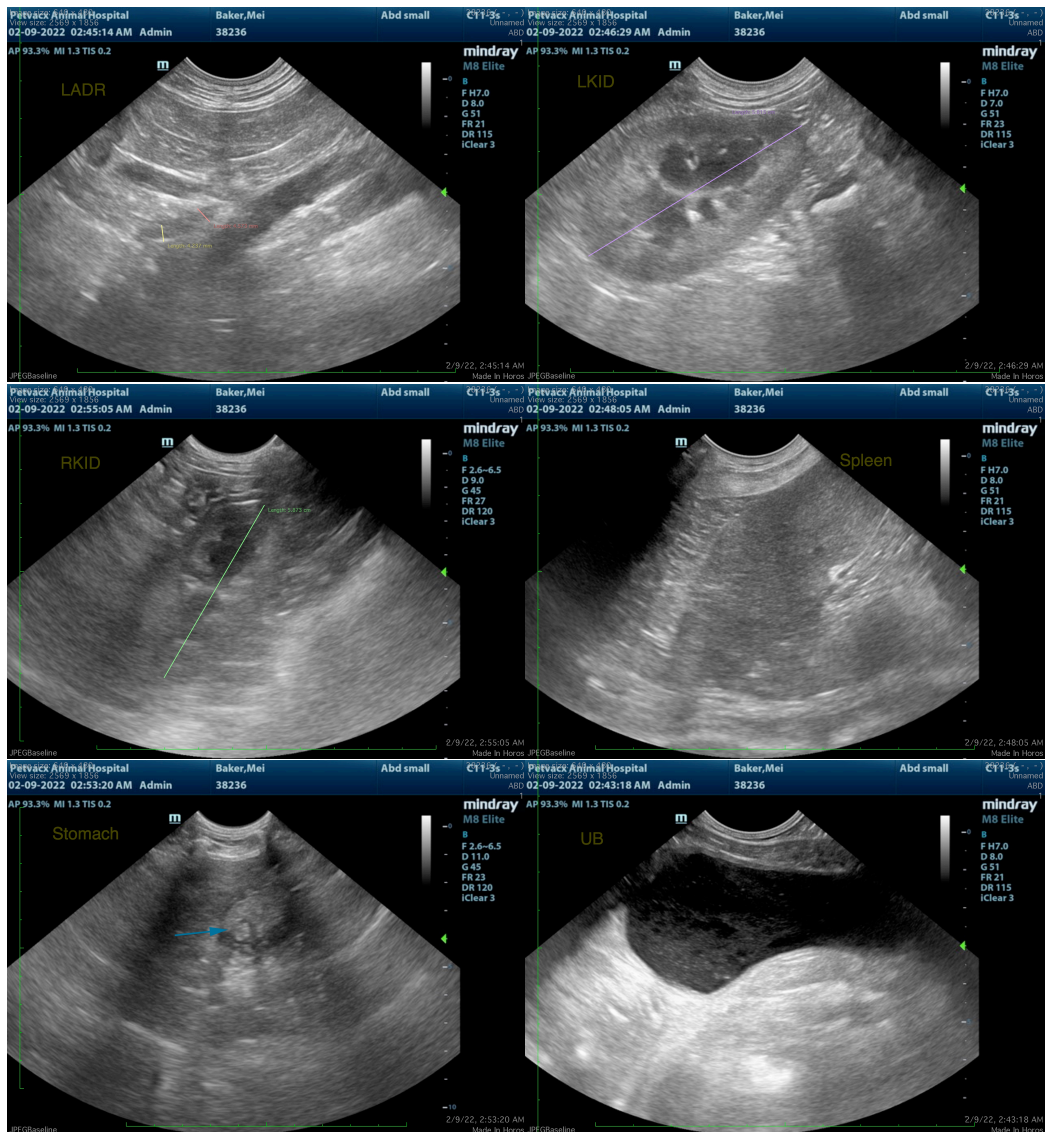
Dr. Rachel Wiley

**INVOICE**

35558

**DATE**

2/9/22



The information and recommendations provided are based on the images presented by the referring veterinarian/sonographer. No evaluation can be communicated regarding pathology that was not visible in the image/video clips provided.

Thank you for this referral. If the clinical or image interpretation does not parallel your findings or if I can be of any further assistance please contact me.

**Beth Johnson, DVM, DACVIM**  
Beth.Johnson@sonopath.com