**PATIENT**

Lucy Brahmer

SPECIES

Feline

BREED

DSH

SEX

Spayed Female

AGE

12 Years 11 Months

WEIGHT

10.3 Pounds

INTERPRETED BYBeth Johnson, DVM
DACVIM**IMAGING PERFORMED BY**

Amy Mayhew, LVT

HOSPITAL NAME

SVS Imaging MI

REFERRING VETWixom Family Pet
Practice**INVOICE**

35560

DATE

2/9/22

PRESENTING CLINICAL SIGNS

Chronic vomiting/diarrhea with recent increase in frequency. History of coughing and rhinitis signs (chest rads pending review).

Abnormal PE/Chem/CBC/UA Results: EOS 18.3% (1-11%), BUN 35.8 (15-32), Amylase 1857 (100-1500), normal T4. UA pending.

ULTRASONOGRAPHIC EXAMINATION OF THE ABDOMEN**Urinary System**

The urinary bladder is moderately distended with anechoic contents. No masses, inflammatory changes, echogenic sediment or cystoliths are observed. The urinary bladder, trigone and visible pelvic urethra are normal in thickness with a smooth mucosal surface.

The kidneys are normal in size, irregular and diffusely echogenic with decreased corticomedullary distinction and poor visualization of internal architecture. The left kidney measured 3.74 cm. Left renal pelvis is dilated (pyelectasia), measuring (0.2 cm). No visible obstruction is observed, but cannot be ruled out. A hyperechoic wedge-shaped cortical indentation is noted on the cranial pole of the left kidney, consistent with a chronic infarct. The right kidney measures 3.26 cm.

Adrenal Glands

The right adrenal gland is normal in size (0.31 cm thick), shape and contour. Corticomedullary structure is unremarkable. Visible surrounding vasculature appears normal.

The left adrenal gland is normal in size (0.85 cm long x 0.27 cm thick), shape and contour. Corticomedullary structure is unremarkable. Visible surrounding vasculature appears normal.

Spleen

The spleen is subjectively normal in size with a normal smooth capsular contour. Parenchyma is appropriately finely textured and homogenous with normal echogenicity relative to surrounding tissue (hyperechoic to liver). No focal nodules or masses are observed. Splenic vasculature appears normal.

Liver

The liver is subjectively normal in size with normal smooth curvilinear peripheral contour. Parenchyma is appropriately hypoechoic to the spleen in echogenicity and appropriately mildly coarse and homogenous in echotexture. A 0.5 cm round, discrete, focal, hyperechoic nodule is noted in the cranial right liver. Visible vasculature and biliary tree appear normal without distension or congestion.

The gallbladder is non-distended in size. The wall is smooth without visible thickening. Luminal contents are primarily anechoic. There is no evidence of cystic or common bile duct dilation.


Gastrointestinal

The stomach wall is normal in thickness (canine < 0.5 cm and feline < 0.4 cm) and layering. The lumen of the stomach is empty with no evidence of obstruction, foreign material or infiltrative disease. Pyloric outflow tract appears patent.

The visible small intestines are normal in wall thickness. Normal layering is maintained except for a diffusely disproportionately thick muscularis layer relative to mucosa. Small intestinal motility appears adequate (1-3 contractions per min). The lumen of the small intestine is empty with no evidence of obstruction, foreign material or infiltrative disease.

IMAGING PERFORMED BY

SVS Mobile Imaging MI 734-637-7711
svsimagingmi@gmail.com



PATIENT

Lucy Brahmer

The visible colon is normal in wall thickness (< 0.2 cm) and layering. Contents are consistent with normal formed feces and gas.

Pancreas

SPECIES

Feline

The pancreas is prominent size. The visible capsule is smooth and normal in contour. Parenchyma is coarse/mottled, and visibly hyperechoic to surrounding tissue. There is no evidence of active peripancreatic inflammation or pancreatic duct overdistention.

BREED

DSH

Free Abdomen

There is no evidence of peritoneal effusion. There is a round, hypoechoic, 0.5 cm diameter lymph node noted near the ileocecolic junction.

SEX

Spayed Female

ULTRASONOGRAPHIC FINDINGS

- Thick muscularis – This finding has been reported in cats with infiltrative bowel disease including both benign inflammatory disease as well as infiltrative neoplasia such as lymphoma.
- Chronic pancreatitis
- Chronic Kidney Disease - This appearance of the kidneys is consistent with chronic kidney disease such as chronic glomerular or interstitial nephritis, chronic pyelonephritis, etc.
- Left kidney Pyelectasia - Differentials for pyelectasia include pyelonephritis, diuresis, congenital malformation or ureteral or lower urinary tract obstruction.
- Chronic infarct in the left kidney
- Discrete, hyperechoic liver nodule – Differentials for which include nodular hyperplasia versus fibrosis or calcification caused by an old hematoma or infarct, chronic granulomatous disease. Infiltrative neoplasia or metastatic disease cannot be ruled out, but are considered less likely.
- Mild reactive lymphadenopathy in the area of the ileocecolic junction – Infiltrative neoplasia cannot be ruled out but is considered less likely.

AGE

12 Years 11 Months

WEIGHT

10.3 Pounds

INTERPRETED BY

Beth Johnson, DVM
DACVIM

INTERPRETATION OF THE FINDINGS & FURTHER RECOMMENDATIONS

Given the clinical signs, thick muscularis, and reported eosinophilia, recommendations include a gastrointestinal malabsorption panel including TLI, PLI, folate and cobalamin to Texas A&M GI laboratory to further assess gastrointestinal and pancreatic systems.

Ultimately, biopsies of the bowel (being sure to include ileum if possible) are necessary to definitively determine the underlying infiltrative process. However, given the eosinophilia, empirical deworming with a 5-day course of Panacur and diet change to a novel or hydrolyzed protein diet +/- empirical steroids (if biopsies are not pursued) are a reasonable medical approach for presumed eosinophilic inflammatory bowel disease. Unless surgery is pursued to obtain GI biopsies, in which case the liver nodule can be biopsied as well.

IMAGING PERFORMED BY

Amy Mayhew, LVT

HOSPITAL NAME

SVS Imaging MI

REFERRING VET

Wixom Family Pet
Practice

INVOICE


35560

DATE

2/9/22

IMAGING PERFORMED BY

SVS Mobile Imaging MI SVS 734-637-7711 svsimagingmi@gmail.com



PATIENT

Lucy Brahmer

SPECIES

Feline

BREED

DSH

SEX

Spayed Female

AGE

12 Years 11 Months

WEIGHT

10.3 Pounds

INTERPRETED BY

Beth Johnson, DVM DACVIM

IMAGING PERFORMED BY

Amy Mayhew, LVT

HOSPITAL NAME

SVS Imaging MI

REFERRING VET

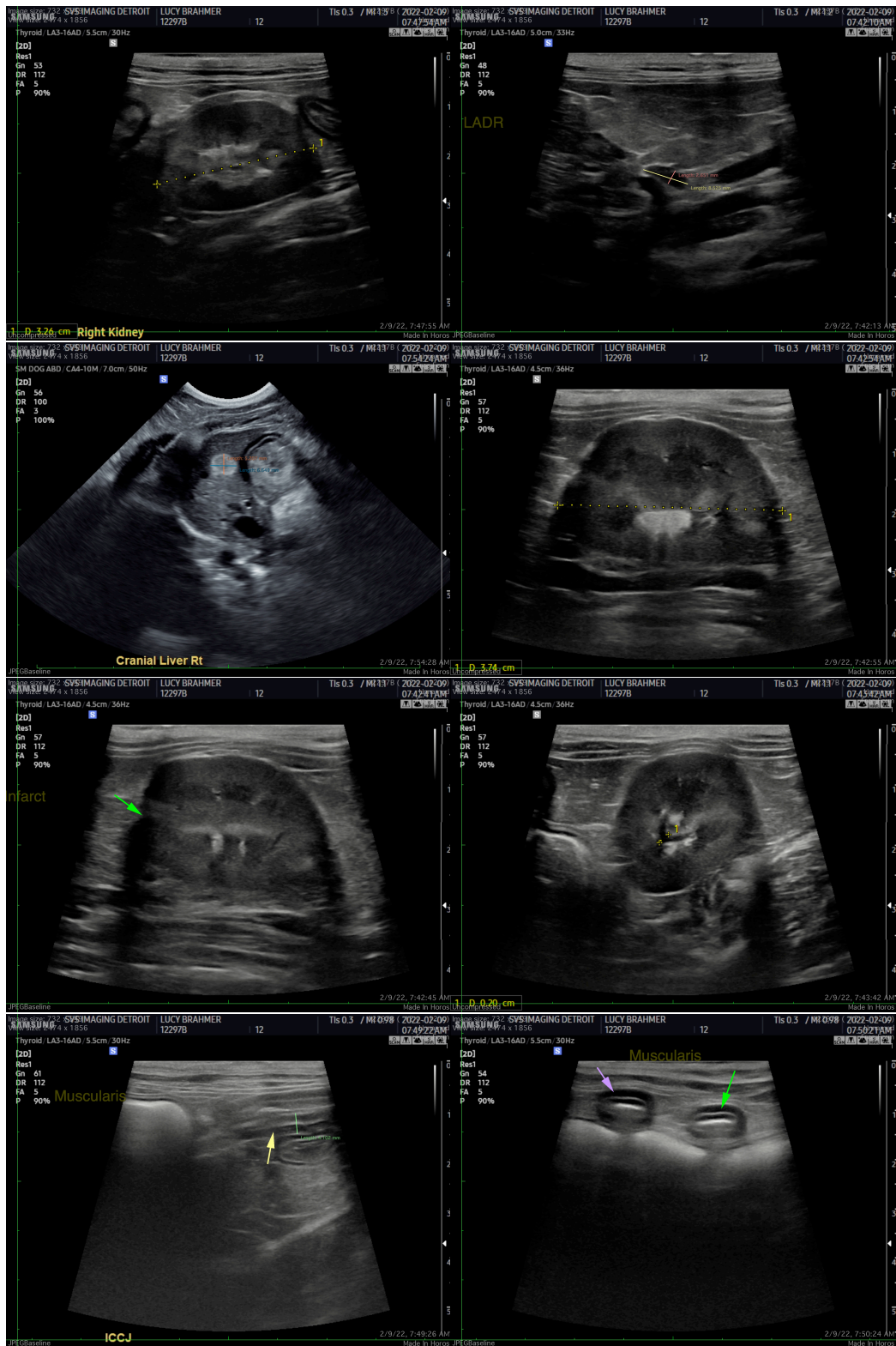Wixom Family Pet Practice

INVOICE

35560


DATE

2/9/22



IMAGING PERFORMED BY

SVS Mobile Imaging MI 734-637-7711
svsimagingmi@gmail.com



Clinical Sonography & Telectology

EDUCATIONAL TELECONSULTATION SERVICES™

1-800-838-4268 info@sonopath.com SonoPath.com

PATIENT

Lucy Brahmer

SPECIES

Feline

BREED

DSH

SEX

Spayed Female

AGE

12 Years 11 Months

WEIGHT

10.3 Pounds

INTERPRETED BY

Beth Johnson, DVM
DACVIM

IMAGING PERFORMED BY

Amy Mayhew, LVT

HOSPITAL NAME

SVS Imaging MI

REFERRING VET

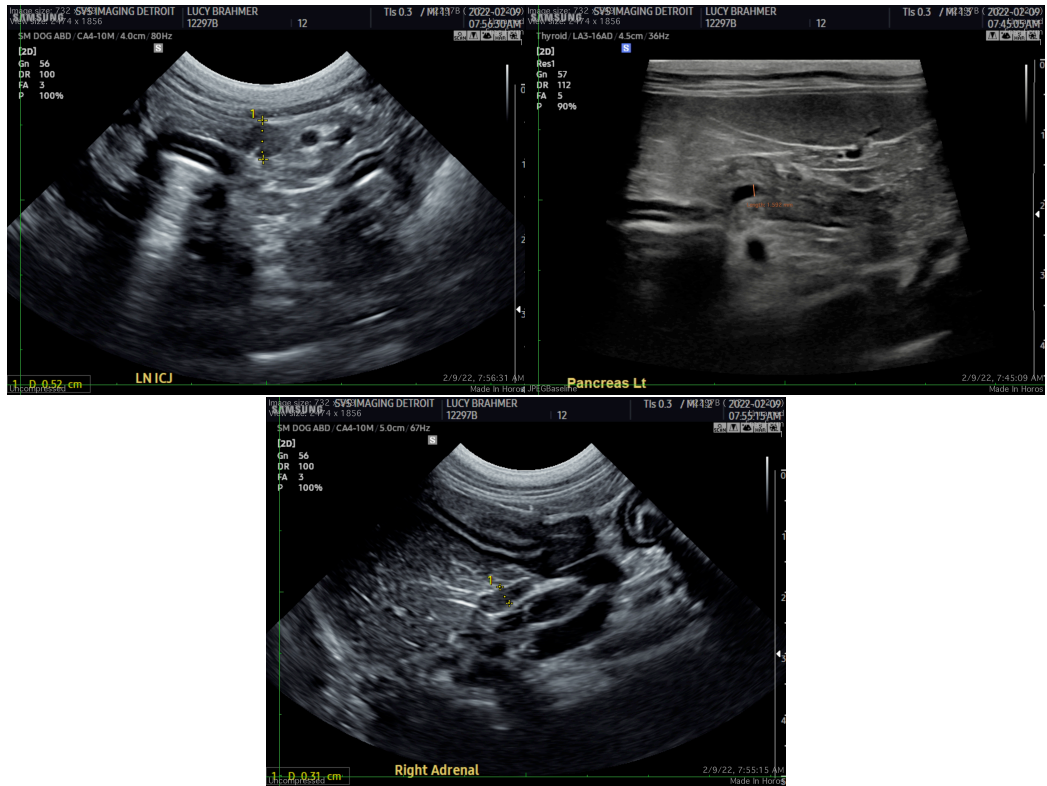
Wixom Family Pet
Practice

INVOICE

35560

DATE

2/9/22



The information and recommendations provided are based on the images presented by the referring veterinarian/sonographer. No evaluation can be communicated regarding pathology that was not visible in the image/video clips provided.

Thank you for this referral. If the clinical or image interpretation does not parallel your findings or if I can be of any further assistance please contact me.

Beth Johnson, DVM, DACVIM
Beth.Johnson@sonopath.com