



PATIENT	PRESENTING CLINICAL SIGNS
Jupiter Bainbridge	jaundice, weight loss (2-2.5 lbs), started Metronidazole, Amoxicillin and Denamarin, no masses palpated Abnormal PE/Chem/CBC/UA Results: elevated liver values
SPECIES	ULTRASONOGRAPHIC EXAMINATION OF THE ABDOMEN
Feline	Urinary System
BREED	The urinary bladder is moderately distended with anechoic contents. No masses, inflammatory changes, echogenic sediment or cystoliths are observed. The urinary bladder, trigone and visible pelvic urethra are normal in thickness with a smooth mucosal surface.
DLH	Both kidneys are normal in size with the left measuring 3.89 cm and the right measuring 4.34 cm with increased cortical echogenicity. Normal smooth peripheral margination and shape are maintained. There is a normal 1:3 cortex/medulla ratio with appropriate corticomedullary distinction. There is no evidence of pyelectasia, mineral or infarcts observed.
SEX	Adrenal Glands
Neutered Male	The right adrenal gland is normal in size (0.33 cm at the cranial pole and 0.45 cm at the caudal pole), shape and contour. Corticomedullary structure is unremarkable. Visible surrounding vasculature appears normal.
AGE	The left adrenal gland is normal in size (0.47 cm at the cranial pole and 0.47 cm at the caudal pole), shape and contour. Corticomedullary structure is unremarkable. Visible surrounding vasculature appears normal.
11 Years	
WEIGHT	Spleen
10.6 Pounds	Spleen is subjectively enlarged in size with rounded margins but intact capsule. Parenchyma is homogeneously coarse/mottled in echotexture and normal to hypoechoic in echogenicity. No focal nodules or masses are observed. Splenic vasculature appears normal.
INTERPRETED BY	Liver
Beth Johnson, DVM DACVIM	Liver is subjectively enlarged. Margins are smooth but round. It has a normal homogenous echotexture. Parenchyma is diffusely hyperechoic characterized by less prominent than normal portal vein walls and increased echogenicity relative to the spleen. No focal lesions are observed. Visible vasculature and biliary tree appear normal without distension or congestion.
IMAGING PERFORMED BY	Gastrointestinal
Adrienne Ligenza	The gallbladder is mildly distended with anechoic bile and gravity dependent, echogenic sediment. The wall is smooth without visible thickening. There is no evidence of cystic duct or common bile duct dilation. There is no evidence of effusion or inflammation.
HOSPITAL NAME	
Rush Vet Center	
REFERRING VET	
Dr. Lori Milot	
INVOICE	
35544	The visible small intestines are normal in wall thickness and layering (canine duodenum < 0.5 cm and feline duodenum < 0.4 cm; other < 0.3 cm). Small intestinal motility appears adequate (1-3 contractions per min). The lumen of the small intestine is empty with no evidence of obstruction, foreign material or infiltrative disease.
DATE	
2/9/22	



PATIENT	The visible colon is normal in wall thickness (< 0.2 cm) and layering. Contents are consistent with normal formed feces and gas.
Jupiter Bainbridge	
Pancreas	
SPECIES	The pancreas is prominent and hypoechoic to surrounding tissue. The visible capsule is smooth and normal in contour. There is no visible pancreatic duct dilation. Hyperreactive mesentery is present around the pancreas. No free fluid is noted.
Feline	
Free Abdomen	
BREED	There is no evidence of peritoneal effusion. There is no apparent lymphadenopathy.
DLH	
ULTRASONOGRAPHIC FINDINGS	
SEX	<ul style="list-style-type: none"> Bilaterally hyperechoic kidneys – most consistent with normal fat deposition, given normal size. Infiltrative disease cannot be ruled out but is considered less likely.
Neutered Male	
AGE	<ul style="list-style-type: none"> Coarse splenomegaly – can be associated with congestion caused by sedation (if sedated) but can also be associated with diffuse infiltrative disease. Both benign conditions such as extramedullary hematopoiesis, lymphoid hyperplasia, amyloidosis as well as infiltrative neoplastic diseases such as round cell neoplasia should be considered.
11 Years	
WEIGHT	<ul style="list-style-type: none"> Hyperechoic hepatomegaly – consistent with benign hepatic lipidosis. Infiltrative disease such as amyloidosis or neoplasia, such as mast cell tumor or less likely, lymphoma, is also possible. Mild acute pancreatitis Cholecystic debris of unknown clinical significance – This can be seen with biliary stasis from fasting or illness. However, it is often associated with hepatobiliary disease in cats, and in this case of increased liver enzymes and increased total bilirubin, this should be considered likely significant.
10.6 Pounds	
INTERPRETED BY	
Beth Johnson, DVM DACVIM	
IMAGING PERFORMED BY	
Adrienne Ligenza	
HOSPITAL NAME	
Rush Vet Center	
REFERRING VET	
Dr. Lori Milot	
INVOICE	
35544	
DATE	
2/9/22	

INTERPRETATION OF THE FINDINGS & FURTHER RECOMMENDATIONS

If this patient is not anemic, then the increased total bilirubin is likely due to an intrahepatic cholestasis, given the lack of visible post-hepatic cause in these images. A post-hepatic cause cannot be completely ruled out, as a small obstruction could be missed, and/or the obstruction could be early without much dilation. However, recommendations given the organomegaly include a fine needle aspirate of the spleen and liver if patient's coagulation status is appropriate.

Given the weight loss and the pancreatic changes, a gastrointestinal malabsorption panel including TLI, PLI, folate and cobalamin to Texas A&M GI laboratory is also recommended. In the meantime, medical management of pancreatitis/gallbladder sludge is recommended, paying close attention nutritional support to prevent hepatic lipidosis if not already present.

Recommendations include IV fluids, antiemetics, gastroprotectants, appetite stimulants, and/or feeding tube if necessary for nutritional support, and broad-spectrum antibiotics with close monitoring for changes. If liver enzymes, especially total bilirubin, do not improve and/or progress, recheck imaging is recommended to help further identify a possible progressive post-hepatic cause.



PATIENT

Jupiter Bainbridge

SPECIES

Feline

BREED

DLH

SEX

Neutered Male

AGE

11 Years

WEIGHT

10.6 Pounds

INTERPRETED BY

Beth Johnson, DVM
DACVIM

IMAGING PERFORMED BY

Adrienne Ligenza

HOSPITAL NAME

Rush Vet Center

REFERRING VET

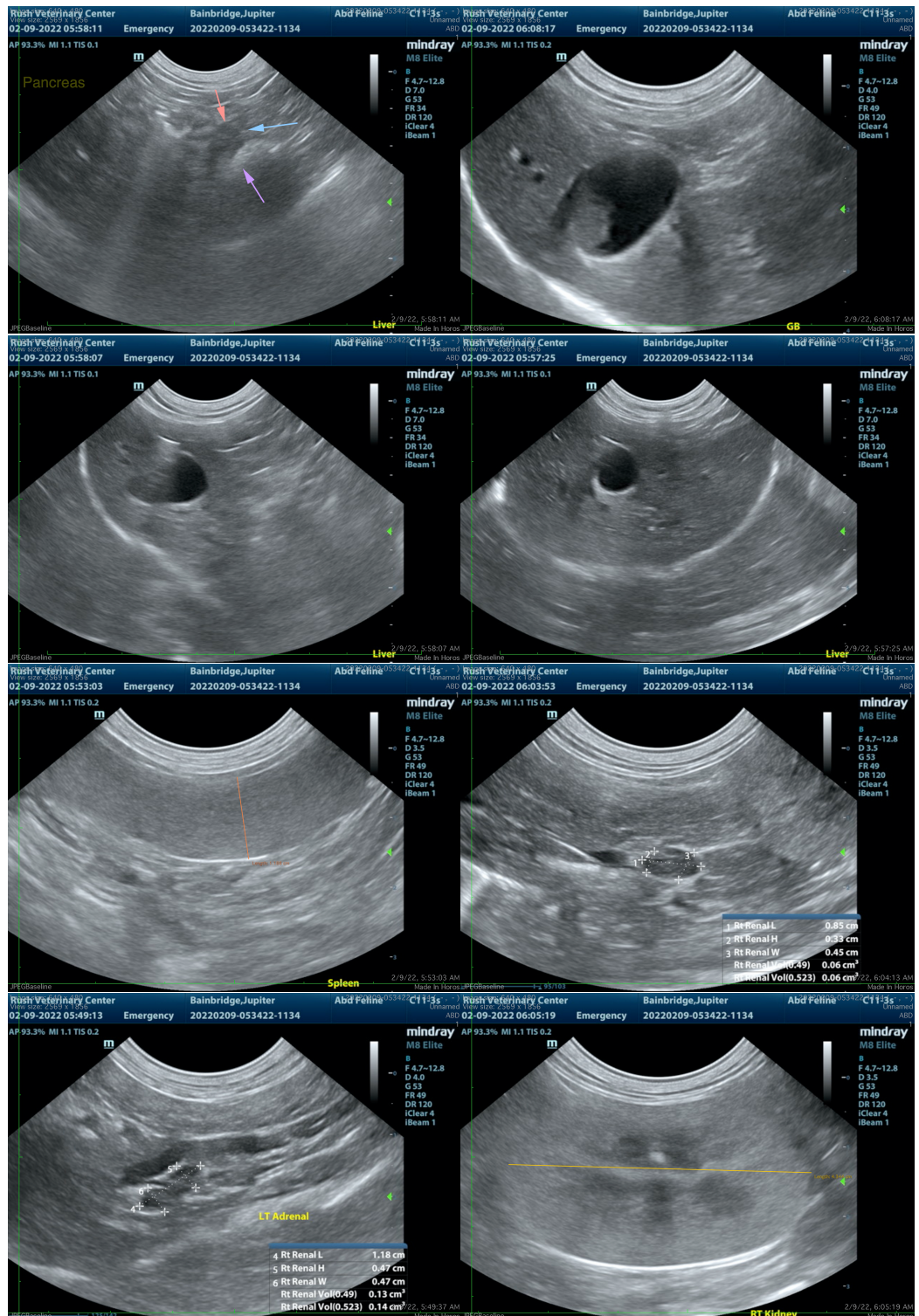
Dr. Lori Milot

INVOICE

35544

DATE

2/9/22





PATIENT

Jupiter Bainbridge

SPECIES

Feline

BREED

DLH

SEX

Neutered Male

AGE

11 Years

WEIGHT

10.6 Pounds

INTERPRETED BY

Beth Johnson, DVM
DACVIM

IMAGING PERFORMED BY

Adrienne Ligenza

HOSPITAL NAME

Rush Vet Center

REFERRING VET

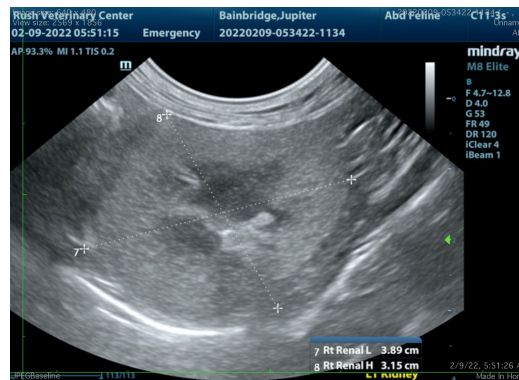
Dr. Lori Milot

INVOICE

35544

DATE

2/9/22



The information and recommendations provided are based on the images presented by the referring veterinarian/sonographer. No evaluation can be communicated regarding pathology that was not visible in the image/video clips provided.

Thank you for this referral. If the clinical or image interpretation does not parallel your findings or if I can be of any further assistance please contact me.

Beth Johnson, DVM, DACVIM
Beth.Johnson@sonopath.com